



Histopathological Findings and the Distribution of Laminin and Fibronectin in Psoriatic Skin

Mukaddes Eşrefoğlu*, Muammer Seyhan**, Akın Aktaş***, Mehmet Gül*, Feral Öztürk*

*İnönü University Medical Faculty, Department of Histology and Embryology, Malatya

** İnönü University Medical Faculty, Department of Dermatology, Malatya

***Atatürk University Medical Faculty, Department of Dermatology, Erzurum

Objective: Some previous studies have shown important modifications of the basement membrane of psoriatic skin, which could play a key role in alterations of keratinocyte proliferation and differentiation. Changes in distribution of the laminin $\alpha 1$ chain, together with fibronectin, might influence keratinocyte growth, and thus could be responsible for the initiation of psoriasis. In the view of these considerations, we have aimed to determine the expression pattern of laminin and of fibronectin, besides the structural alterations of the epidermis, dermis, and dermoepidermal junction in involved psoriatic skin.

Material and methods: Fourteen male psoriasis vulgaris patients and 6 healthy volunteers were studied retrospectively. All psoriatic patients had chronic and stable psoriatic plaque, which had not been treated. Sections were stained with haematoxylin and eosin (H-E), and periodic acid Schiff (PAS) reagent, and were stained immunohistochemically using laminin and fibronectin kits.

Results: Histological examination of psoriatic skin showed elongated rete ridges, parakeratosis, epidermal intercellular oedema, exosistosis of mononuclear cells into the epidermis, and mononuclear cell inflammation in the dermis. PAS staining revealed the large interruptions of the basement membrane. In psoriatic skin samples, the staining of laminin showed discontinuous, weak, and an uneven disruption in the basement membrane. Staining for fibronectin was pronounced below the basement membrane and showed a reticular or fibrillar pattern in the dermis. **Conclusion:** The results of our study support the hypothesis that basement membrane alterations together with the alterations in the distribution pattern of laminin and fibronectin may play an important role in the pathogenesis of psoriasis.

Key Words: Psoriasis, Laminin, Fibronectin, Basement membrane, Epidermis

Psöriatik Deride Histopatolojik Bulgular ve Laminin ve Fibronektin Dağılımı

Amaç: Yapılan bazı çalışmalarda psöriatik deride keratinosit proliferasyonu ve farklılaşmasında anahtar rol oynayabilecek bazı önemli bazal membran değişiklikleri olduğu gösterilmiştir. Laminin $\alpha 1$ zinciri ve fibronektin dağılımındaki değişiklikler keratinosit büyümesini etkileyerek psöriasisin başlamasından sorumlu olabilir. Bu görüş doğrultusunda çalışmamızda psöriatik deride dermis, epidermis ve dermo-epidermal bileşkedeki yapısal değişikliklerin yanısıra laminin ve fibronektin dağılım örneğini de incelemeyi amaçladık.

Gereç ve Yöntem: Ondört erkek psöriasis vulgaris hastası ve 6 sağlıklı gönüllü retrospektif olarak değerlendirildi. Psöriasisli hastalar kronik ve stabil plakları olan, tedavi almamış hastalardı. Kesitler haematoxylin ve eosin (H-E) ve periodic acid Schiff (PAS) yöntemleri ve laminin ve fibronektin kitleri kullanılarak immunohistokimyasal olarak boyandı.

Bulgular: Psöriatik derinin histolojik incelenmesinde rete çıkıntılarında uzama, parakeratoz, epidermal intersellüler ödem, mononükleer hücrelerin epidermise geçişi ve dermiste mononükleer hücre infiltrasyonu saptandı. PAS yöntemiyle bazal membranda geniş kesitiler gözlemlendi. Psöriatik deride bazal membranda laminin zayıf, kesintili ve düzensiz bir dağılım örneği gösterdi. Fibronektin bazal membran altında belirgindi, dermiste fibriller veya retiküler bir boyanma örneği gösterdi.

Sonuç: Çalışmamızın sonuçları psöriasisin patogenezinde bazal membran değişiklikleri ile birlikte laminin ve fibronektin dağılımındaki değişikliklerin önemli rol oynadığı hipotezini desteklemektedir.

Anahtar Kelimeler: Psöriasis, Laminin, Fibronektin, Bazal membran, Epidermis

Psoriasis vulgaris is a hyperproliferative disorder of keratinocytes, characterized by both the hyperplasia of the spinous layer and incomplete differentiation of granular and cornified layers (agranulosis and parakeratosis).¹ Although the exact mechanism of psoriasis is still unclear, the involvement of T-cell mediated cytokine expression in the etiology of psoriasis is becoming clearer.² One of the most likely hypotheses is that it is related to intrinsic keratinocyte abnormalities of an immunological nature.³ Changes in distribution of the laminin α 1 chain, together with cell lymphokines and fibronectin, might influence keratinocyte growth, and thus could be responsible for the initiation and maintenance of psoriasis.⁴⁻⁸ Fibronectin can regulate keratinocyte growth and laminin α 1 chain can interfere with cell adhesion and polarization, basement membrane formation and cell morphological process, these functions are severely altered in psoriasis.^{4,8}

Some previous ultrastructural and immunohistochemical studies have shown important modifications of the basement membrane of psoriatic skin, which could play a key role in alterations of keratinocyte adhesion, migration, proliferation and differentiation. Besides providing a purely mechanical linkage between the epidermis and the dermis, the basement membrane plays a fundamental role in the regulation of the principal biological functions of the keratinocytes (adhesion, migration, proliferation, differentiation, morphogenesis). Structural and/or molecular modifications of the structure could therefore be the basis for acquired or inherited skin diseases characterized by altered cellular proliferation and differentiation, psoriasis being a classic example of such a disease.^{9,10}

In the view of these considerations, we have aimed to determine, by means of immunohistochemical study, the expression pattern of laminin and of fibronectin, besides the structural alterations of the epidermis, dermis, and dermoepidermal junction in involved psoriatic skin.

MATERIALS AND METHODS

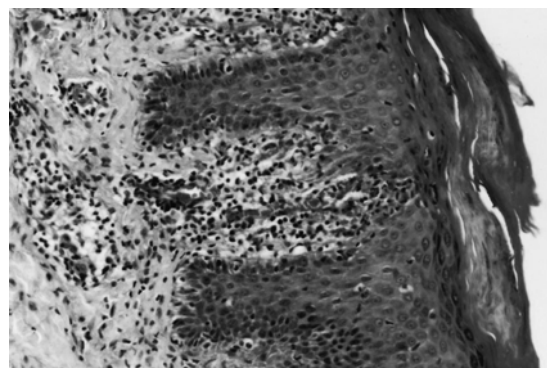
Fourteen male psoriasis vulgaris patients and 6 healthy volunteers with no history of psoriasis and systemic diseases, admitted to the departments of Dermatology of İnönü and Atatürk Universities, were studied retrospectively. All psoriatic patients had chronic and stable psoriatic plaques, which had not been treated by systemic or topical drugs. Biopsies taken from psoriatic plaques were processed with

routine histological techniques. Sections were stained with haematoxylin and eosin (H-E), and periodic acid Schiff (PAS) reagent, and were stained immunohistochemically using laminin (Laminin, IMM7-7, Sigma Chemicals, St. Louis, USA) and fibronectin (Fibronectin Ab 11, Clone FBN11, Neomarkers, USA) kits. The sections were observed and photographed using a light microscope (Olympus BH-2).

RESULTS

Histological examination of psoriatic skin showed slightly elongated rete ridges, focal lack of the granular layer, parakeratosis (Fig 1), epidermal intercellular oedema (dilatation of intercellular spaces), exosistosis of mononuclear cells into the epidermis (Fig 2), and mononuclear cell inflammation in the dermis (Figure 1-3). There were many mitotic figures within the epidermis (Fig 4). PAS staining revealed the large interruptions of the basement membrane (Fig 3). Normal skin sections stained immunohistochemically using laminin kit showed a linear and continuous staining in the basement membrane and around the dermal vessels, nerves and hair follicles (Fig 5). On the other hand, in psoriatic skin samples the staining of laminin showed discontinuous, weak, and an uneven disruption in the basement membrane. In some regions, there were markedly reactive keratinocytes (Fig 6). Normal skin sections stained using fibronectin kit showed positive staining underneath the basement membrane and in the dermis (Fig 7). In psoriatic skin, staining for fibronectin was pronounced below the basement membrane and showed a reticular or fibrillar pattern in the dermis (Fig 8).

Figure 1. Lesional psoriatic skin. The elongated rete ridges, focal lack of the granular layer, and mononuclear cell inflammation in the dermis are observed. H-E; x 40.



Histopathological Findings and the Distribution of Laminin and Fibronectin in Psoriatic Skin

Figure 2. Lesional psoriatic skin. Prominent intercellular edema and migration of mononuclear cells into the epidermis (arrows) are observed. H-E; x 100.

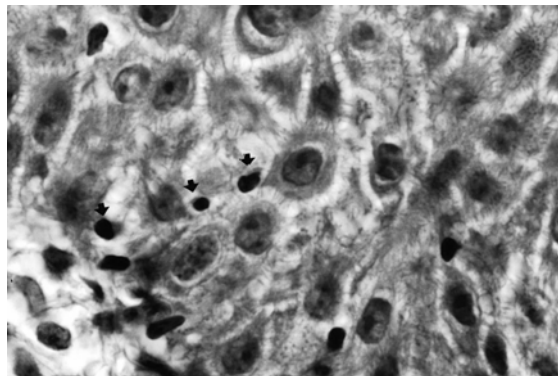


Figure 3. Lesional psoriatic skin. Interruptions of the basement membrane is clearly seen. Mononuclear cell inflammation in the dermis is observed. PAS; x40.

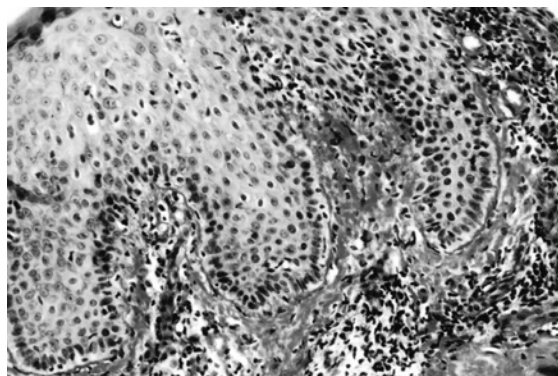
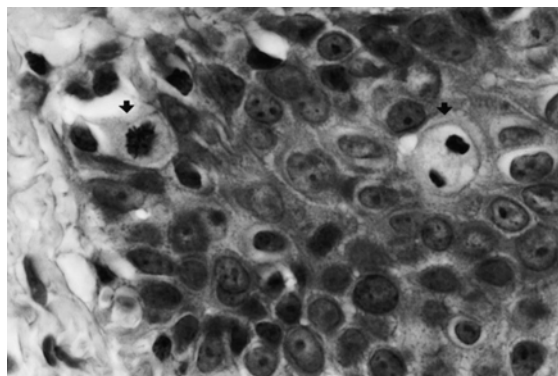


Figure 4. Lesional psoriatic skin. Mitotic figures in basal and intermediate cell layers are observed (arrows). H-E; x100.

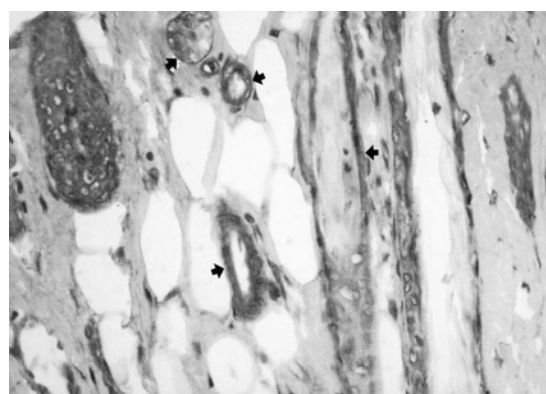


DISCUSSION

In the fully developed lesions the epidermis is thickened due to a combination of increased cell number and size (acanthosis). The acanthosis tends to be quite regular and principally manifests as elongated

rete ridges with bulbous tips and with thinning of the suprapapillary epithelium. The granular layer is lost with prominent parakeratosis. The dermis characteristically contains a mild to moderate perivascular inflammatory infiltrate of lymphocytes and macrophages. The mononuclear cells emigrate into epidermis and are associated with the loss of granular layer and parakeratosis.¹¹ The psoriatic epidermis is characterized by an increase in the intercellular spaces, dividing keratinocytes are often observed in the lower layer of the psoriatic epidermis.¹² In lesional psoriatic skin, the basal keratinocytes appears to be columnar with a dilated base, separated by very dilated intercellular spaces.⁹ In our study, focal lack of the granular layer, parakeratosis, dilatation of intercellular spaces, elongation of rete ridges, exosistosis of mononuclear cells into the epidermis, and mononuclear cell inflammation in the dermis were observed. There were many mitotic figures within the epidermis. Enlarged intercellular spaces are a common finding in psoriasis.^{9,13} Psoriasis simultaneously has a rapidly proliferating epidermis.¹⁴ Studies on the cell proliferation kinetics of psoriatic epidermal cells reveal that there is a doubling of the proliferative cell population in psoriasis and an increase in the growth fraction. There is a 28-fold greater production of cells than that of normal epidermis.¹⁵ The maturation pathway of keratinocytes in active psoriatic lesions differs qualitatively from that in normal epidermis.¹⁶ Increased mitosis represents increased cell proliferation.

Figure 5. Immunohistochemical staining of laminin in normal skin. Immunohistochemical staining of laminin is prominent around the dermal vessels, nerves and hair follicles (arrows). x 40



The epidermal basement membrane is composed of numerous macromolecules (laminin, collagen type IV and type VII, proteoglycans, nidogen/entactin) The most important among these are laminin and collagen

type IV, which besides merely mechanically connecting the epidermis and the dermis, also play a fundamental role in the regulation of the principal biological functions of keratinocytes.^{8,17,18}

Figure 6. Immunohistochemical staining of laminin in lesional psoriatic skin. Immunohistochemical staining of laminin is weak and discontinuous in the basement membrane (arrows). Cytoplasm of some of the keratinocytes is markedly reactive. Mononuclear cell infiltration within the epidermis is evident at the right side of the figure. x 40.

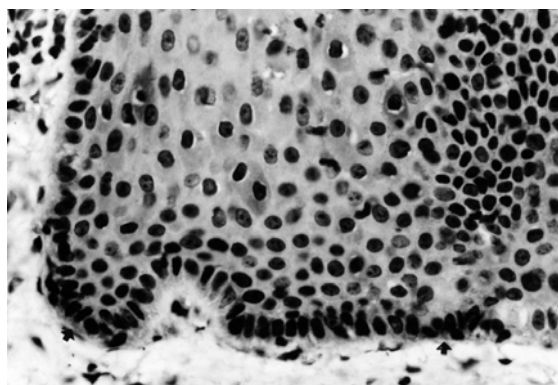
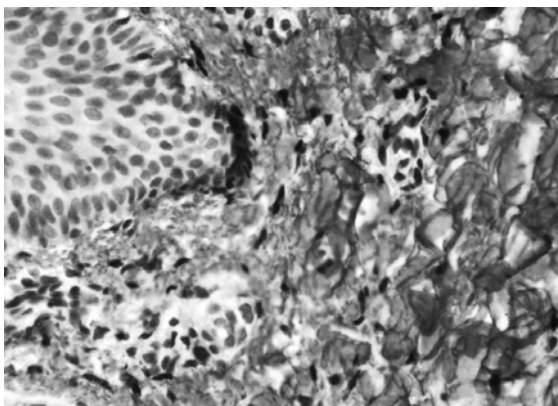


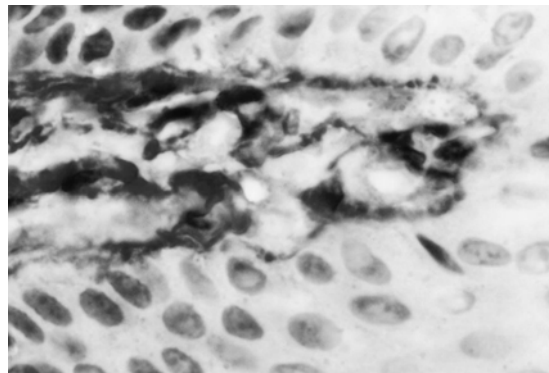
Figure 7. Immunohistochemical staining of fibronectin in normal skin. Positive staining underneath the basement membrane and in the dermis is seen. x 40



Some previous ultrastructural and immunohistochemical studies, *in vivo* and *in vitro*, have shown important modifications of the basement membrane of psoriatic skin, which could play a key role in alterations of keratinocyte adhesion, migration, proliferation and differentiation. Besides providing a purely mechanical linkage between the epidermis and the dermis, the basement membrane plays a fundamental role in the regulation of the principal biological functions of the keratinocytes (adhesion, migration, proliferation, differentiation, morphogenesis). Structural and/or molecular modifications of the structure could therefore be the

basis for acquired or inherited skin diseases characterized by altered cellular proliferation and differentiation, psoriasis being a classic example of such a disease.^{9,10}

Figure 8. Immunohistochemical staining of fibronectin in lesional psoriatic skin. Prominent immunohistochemical staining of fibronectin is obvious underneath the basement membrane. Fibrillar staining pattern is obvious in the dermis. X100.



Recent studies have demonstrated the presence in psoriatic skin of ultrastructural and molecular alterations in the basement membrane.^{4,9} In normal skin, basal keratinocytes are well attached to the basement membrane that always appears to be continuous. In psoriatic skin, the surface of lamina densa always shows numerous focal interruptions with different forms. The loss of basement membrane integrity in psoriatic skin has already been widely described; several investigators have observed that cytoplasmic processes from basal keratinocytes protrude into the dermis through gaps in the basal lamina.⁹

It is hypothesized that the loss of basement membrane integrity is due to proteolytic enzymes released by antigen-presenting cells, lymphocytes, neutrophils and endothelial cells.⁴ Basal keratinocyte herniations do not occur passively as a result of the formation of gaps in the basal lamina but are associated with gaps suggestive of proteolytic enzyme release from neutrophils, macrophages, Langerhans cells, and endothelial cells.^{19,20}

Although we have not performed electron microscopic examination; wide basement membrane interruption in psoriatic skin was very clear in the sections stained with PAS.

In psoriatic skin the basement membrane interruption probably correlated with an abnormal assembling and/or secretion of the laminin α 1 chain,

imitates a micro wound for basal keratinocytes that contact a fibronectin substratum. In psoriasis, there is a profound alteration of all the structures involved in cellular adhesion, and modification of the normal cell-matrix interaction may be of fundamental importance in the pathogenesis of the disease. An alteration of laminin α 1 chain together with fibronectin may play a role in the dysregulation of cell morphological processes.⁴

Laminins are the most abundant structural non-collagenous glycoproteins ubiquitously present in basement membranes.^{4,8,21,22} Laminins are involved in multiple interactions with themselves, with the other components of the basal lamina, and with cells. It endows laminins with a central role in the formation, the architecture, and the stability of basement membranes. Laminins also provide adjacent cells with a mechanical scaffold and biological information either directly by interacting with cell surface components, or indirectly by trapping growth factors. In doing so they trigger and control cellular functions.^{8,22} Indeed, the laminins display a remarkable repertoire of functions, most importantly as structural elements forming a network throughout the basement membrane to which other collagenous and non-collagenous glycoproteins and proteoglycans attach.²¹ Because of their structural properties, they represent crucial building blocks for tissue assembly, architecture, and stability.²³

Laminin α 1 shows a linear and continuous staining in the basement membrane and the dermal vessel walls in normal skin. On the other hand, in psoriatic skin sections, the staining for laminin α 1 chain is discontinuous, with uneven distribution in the basement membrane, mainly at the apex of the dermal papilla. In the same region clusters of keratinocytes appears markedly reactive.⁴ In involved psoriatic skin basement membrane there is both lack and altered distribution of laminin 1.²⁴ The keratinocytic adhesion system in psoriatic patients is already altered before the clinical manifestations of the disease.¹⁰ In our study, laminin positivity showed wide interruptions, and the cytoplasm of some of the keratinocytes was obviously reactive. It has been reported that in untreated psoriasis laminin is absent in basement membrane, there is modest staining in basal keratinocytes whereas, intense staining in suprabasal keratinocytes.²⁴

Fibronectin, a high-molecular glycoprotein, one of acute-phase proteins, contributes to cellular proliferation and macrophagal activity regulation, and

its blood plasma levels are an indicator of the reticuloendothelial system functional activity.²⁵ Human keratinocytes *in vitro* have been shown to produce fibronectin. Epithelium can contribute fibronectin to the dermal-epidermal junction.²⁶

Fibronectin normally localizes in the dermis and the epidermal-dermal junction.^{5,16} Normal skin shows no staining above the basement membrane with antibodies against fibronectin, positive staining is restricted to the dermis and underneath the basement membrane.⁵ In psoriatic skin, staining for fibronectin is more pronounced, with an overexpression in the papillary dermis under the interruptions of the basement membrane.⁴ In untreated psoriatic lesions, fibronectin is clearly visualized in the dermo-epidermal junction and in the walls of papillary capillaries, and shows a reticular or fibrillar pattern in the dermis.²⁷ It is also detected intra- and extracellularly in the psoriatic epidermis. This result indicate that the alterations in keratinocyte maturation found in psoriasis do not arise from a truncation of the normal maturation pathway but rather reflect the onset of an abnormal pathway of differentiation characterized by the expression of fibronectin.⁵ In our study, there was a strong positive staining beneath the basement membrane; it showed fibrillar and somewhat reticular pattern in the dermis. Positive staining was not detected in psoriatic epidermis.

As a conclusion, the results of our study support the hypothesis that basement membrane alterations together with the alterations in the distribution pattern of laminin and fibronectin may play an important role in the pathogenesis of psoriasis.

REFERENCES

1. McKay IA, Leigh IM. Altered keratinocyte growth and differentiation in psoriasis. *Clin Dermatol* 1995;13:105-114.
2. Kormelil T, Lowe NJ, Yamauchi PS. Psoriasis; immunopathogenesis and evolving immunomodulators and systemic therapies; U.S. experiences. *Br J Dermatol* 2004;151(1):3-15.
3. Guilhou JJ. Immunopathogenesis of psoriasis: news in an old concept. *Dermatology* 1998;197:310-312.
4. Vaccaro M, Magganda I, Cutroneo F, et al. Changes in the distribution of laminin α 1 chain in psoriatic skin: immunohistochemical study using confocal laser scanning microscopy. *Br J Dermatol* 2002;146(3):392-398.
5. Bernard BA, Robinson SM, Vandaele S, Mansbridge JN, Darmon M. Abnormal maturation pathway of keratinocytes in psoriatic skin. *Br J Dermatol* 1985;112(6):647-653.
6. Bata-Csorgo Z, Cooper KD, Ting KM, Voorhees JJ, Hammerberg C. Fibronectin and alpha 5 integrin regulate keratinocyte cell cycling. A mechanism for increased fibronectin potentiation of T cell lymphokine-driven keratinocyte hyperproliferation in psoriasis. *J Clin Invest* 1998;101(7):1509-1518.
7. Beta-Csorgo Z, Hammerberg C, Voorhees JJ, Cooper KD. Kinetics and regulation of human keratinocyte stem cell growth in short-term primary *ex vivo* culture. Cooperative growth factors from psoriatic lesional T lymphocytes stimulate proliferation among psoriatic uninvolved, but not normal, stem keratinocytes. *J Clin Invest* 1995;95:317-327.
8. Aumailley M, Smyth N. The role of laminins in basement membrane function. *J Anat* 1998 193 (Pt 1):1-21.
9. Vaccaro M, Pergolizzo S, Mondello MR, et al. The dermoepidermal junction in psoriatic skin as revealed by scanning electron microscopy. *Arch Dermatol Res* 1999;291:396-399.

10. Mondello MR, Magaudda L, Pergolizza S, et al. Behaviour of laminin 1 and type IV collagen in uninvolved psoriatic skin. Immunohistochemical study using confocal laser scanning microscopy. Arch Dermatol Res 1996;288:527-531.
11. Fleming KA. The skin. In: McGee JO'D, Isaacson PG, Wright NA, editors. Oxford Textbook of Pathology. Oxford : Oxford university press. 1992. p. 2146-2147.
12. Kawashima K, Dio H, Ito Y, Shibata M, Yoshinaka R, Otsuki Y. Evaluation of cell death and proliferation in psoriatic epidermis. J Dermatol Sci 2004;35(3):207-214.
13. Mete UO, Denli YG, Özbilgin MK, et al. Electron microscopy of psoriatic skin before and after psoralen/ultraviolet A treatment. Cutis 1996;58(1):83-86.
14. Stone OJ. Psoriasis: highly reactive early cellular inflammation. Med Hypotheses 1990;31(1):47-53.
15. Weinstein GD, McCullough JL, Ross PA. Cell kinetic basis for pathophysiology of psoriasis. J Invest Dermatol 1985;85(6):579-583.
16. Watanabe S, Wagatsuma K, Ichikawa E, Takahashi H. Abnormal distribution of epidermal proteins antigens in psoriatic epidermis. J Dermatol 1991;18(3):143-151.
17. Timpl R. Structure and biological activity of basement membrane proteins. Eur J Biochem 1989;180(3) :487-502.
18. Yurchenco PD, Cheng YS, Colognato H. Laminin forms an independent network in basement membranes. J Cell Biol 1992;117(1):1119-1133.
19. Heng MC, Heng JA, Allen SG. Electron microscopic features in generalized pustular psoriasis. J Invest Dermatol 1987;89(2):187-191.
20. Heng MC, Kloss SG, Kuehn CS, Chase DG. Significance and pathogenesis of basal keratinocyte herniations in psoriasis. J Invest Dermatol 1986;87(3):362-366.
21. Aumailley M, Rousselle P. Laminins of the dermo-epidermal junction. Matrix Biol 1999 ;18(1) :19-28.
22. McGowan KA, Marinkovich P. Laminins and human disease. Microsc Res Tech 2000;51:262-279.
23. Aumailley M, Krieg T. Laminins: a family of diverse multifunctional molecules of basement membranes. J Invest Dermatol 1996;106(2):209-214.
24. Mondello MR, Califano L, Cannavo SP, et al. Psoriasis and cyclosporin: immunohistochemical aspects of the basement membrane. Acta Derm Venerol Suppl (Stockh) 1994;186:96-98.
25. Vasil'eva Niu, Nazimova SV, Tatarinov IuS. The content of fibronectin in the blood of patients with psoriasis. Lab Delo 1991;(3):27-28.
26. O'Keefe EJ, Woodley DT, Falk RJ, Gammon WR, Briggaman RA. Production of fibronectin by epithelium in a skin equivalent. J Invest Dermatol 1987;88(5):634-639.
27. Lauharanta J, Salo O, Kanerva L, Lassus A. The effect of etretinate on fibronectin in psoriatic skin. Acta Derm Venereol 1982;62(4):358-361.

Correspondence Address:

Prof. Dr. Mukaddes Eşrefoğlu
İnönü University Medical Faculty,
Department of Histology and Embryology
44280 Malatya/TÜRKİYE
Tel : 422 341 0660-1306
Fax : 422 341 0036
E-mail : drmukaddes@hotmail.com