



## Laparoscopic Transanal Endoscopic Microsurgery via Single-Port: A Case Report

Fatih Gönültaş, Cemalettin Koç, Sinan Hatipoğlu, Hüseyin Yönder, Serdar Karakaş, Mustafa Ateş, Abuzer Dirican

Inonu University, Faculty of Medicine, Department of General Surgery, Malatya, Turkey

### Abstract

Transanal endoscopic microsurgery is a minimally invasive procedure for the pathologies in the rectum. Transanal endoscopic microsurgery can be performed using a laparoscopic single port. In this study, we intended to represent our first case in which we used the singleport laparoscopic transanal endoscopic microsurgery for the excision of a rectal polyp. The single port was incorporated into the anal canal and then this port was fixed by sutures to the perianal area. The polyp was entirely resected with the help of standard and two angled laparoscopic surgical instruments. There were no postoperative complications and the patient was discharged on the first postoperative day. The histopathological examination revealed that focal high-grade dysplasia detected in the resection material surgical margins were negative. As a result, resection of rectal polyp in the anal canal by applying single-port laparoscopic surgery with the help of hand tools was found to be safe and feasible.

**Key Words:** Rectal Polyp; Single Port; Transanal Endoskopik Microsurgery.

### Tek Port ile Laparoskopik Transanal Endoskopik Mikrocerrahi: Bir Vaka Takdimi

### Özet

Transanal endoskopik mikrocerrahi, rektumda bulunan patolojiler için minimal invaziv bir girişim olup, tek portun transanal endoskopik mikrocerrahide kullanımı mümkündür. Bu çalışmada, merkezimizde ilk kez tek port transanal laparoskopik cerrahi yöntemi ile yaptığımız rektal polip eksizyonu olgusunun sunumunu amaçladık. Tek port, anal kanala yerleştirildikten sonra perianal bölgeye sütürlerle tespit edildi. Standart ve açılı laparoskopik cerrahi aletler yardımı ile rektumdaki polip rezeksiyonu tam kat gerçekleştirildi. Operasyon sonrası komplikasyon gelişmeyen hasta postoperatif birinci günde taburcu edildi. Histopatolojik incelemede, fokal yüksek dereceli displazi tespit edilen rezeksiyon materyalinin cerrahi sınırları negatif idi. Sonuç olarak, rektal polip rezeksiyonunun, anal kanala tek port uygulanarak laparoskopik cerrahi el aletleri yardımıyla rezeksiyonunun mümkün ve güvenli olduğu görüldü.

**Anahtar Kelimeler:** Rektal Polip; Tek Port; Transanal Endoskopik Mikrocerrahi.

## INTRODUCTION

The development of carcinoma, one of the rectal polypoid adenomas, is widely accepted to be the cause of rectal cancer (1). Transanal endoscopic microsurgery (TEM) is one of the surgical methods developed for the incision of polyps localised in the rectum (2). It was first applied by Gerhard Buess about 20 years ago; then, in a more improved form, it was first implemented by Marco Lirici in 2003 (3).

Next, with the introduction of single-port laparoscopy, transanal single-port polypectomy (TASPP) became an alternative method for the resection of rectal polyps. Single-port transanal polypectomy requires costly laparoscopic instruments and experienced operators in addition to the fact that it also takes a long period of time to learn the surgical procedures (4). The aim of this case report is to present the transanal single-port polypectomy excision of a high-grade dysplastic polyp that developed in the rectum.

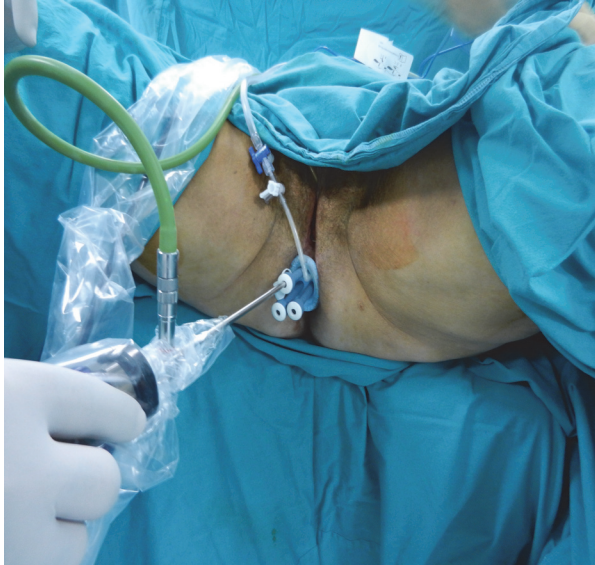## CASE REPORT

A 66-year old female patient presented in our General Surgery Outpatient Clinic with rectal bleeding and abdominal pain. We biopsied from the 1x1,5 cm polypoid lesion that the colonoscopy located on the rectum posterior wall, 10cm through the anal canal. We decided to apply surgery as the biopsy result reported the sample to be a high-grade dysplastic adenomatous polyp. The patient was positioned in the lithotomy position under general anesthesia. Three-input single port was placed in the anal canal with sutures on the perianal skin (Figure 1).

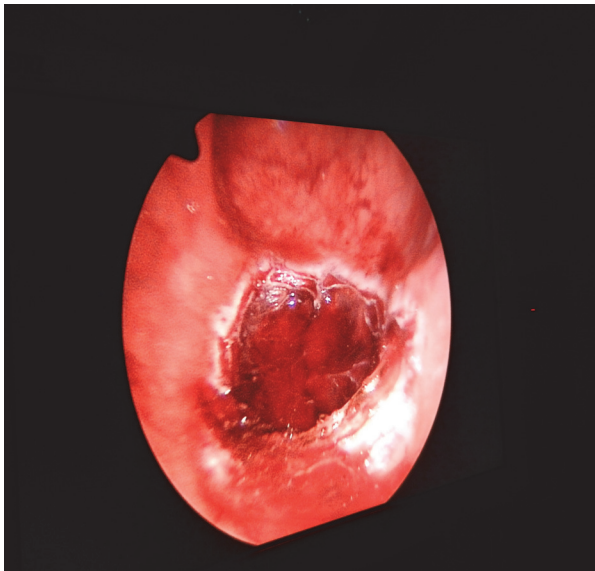
We inflated the rectum with suitable air pressure. Located 10cm from the anal canal, the polyp, about 1x1,5cm in diameter and located on the rectum posterior wall, was entirely excised with the help of a vessel sealing device and single port tools (Figure 2).

The bleeding control was achieved. The resection area was not sutured. The whole operation took about 80 minutes. We did not have any complications throughout

the operation. The patient was discharged on the first postoperative day. The patient's pathology reported the case to be one of high-grade dysplasia with clean surgical margins. The check-up in the 3rd postoperative month showed the colonoscopy to be normal and the patient did not have any fecal incontinence. After the rectal port usage, we did not observe any complications in this case despite the risk of anal sphincter dysfunction.



**Figure 1.** The application of the three-input single-port into the perianal area with sutures.



**Figure 2.** The view of the 1x1,5cm polyp located on the rectum posterior wall after the excision.

## DISCUSSION

Transanal single-port polypectomy has proved to be a popular and effective procedure since it was developed 20 years ago. With its minimal invasive nature, easy

implementation, and applicability, the method may be considered as an effective method. Low complication rates (9%) compared with local excision, safer procedures, and low recurrence rates (4-13%) are among the advantages of this application (5, 6, 7, 8). In some series, though they are few in number, it has been reported that the recurrence rates in the TEM procedures were higher than the ones in the radical surgery (2, 9, 10).

The number of post-TEM procedure complications such as rectal bleeding, suture opening, and perforation was reported to be 3-10% (11). Another complication that negatively affects the quality of life of patients is incontinence. In a series of operations conducted by Endreth et al., incontinence rate was about 6% (10). However, we did not come across any of the reported complications like bleeding, perforation or incontinence. Except for the length of the operation, we did not observe any negative influence of the TEM procedure on the anal sphincter. In single-port transanal surgeries, the single-port may cause less damage since it is flexible.

We used standard single incision laparoscopic surgery tools (SILS) throughout our surgery. Although they are difficult to use in narrow areas of the rectum, they may still be considered advantageous since they allow the use of the vessel sealing devices while they also facilitate polyp resection. Assuming that applying sutures on the surgical resection area may cause submucosal abscess, we preferred to leave the resection area open.

Finally, it can be stated that transanal endoscopic microsurgery, which can be applied at one time, is an effective method in low-risk rectal cancer patients and resectable rectal polyp cases.

## REFERENCES

1. Leslie A, Carey FA, Pratt NR, Steele RJ. The colorectal adenoma-carcinoma sequence. *Br J Surg* 2002; 89: 845-60.
2. Middleton PF, Sutherland LM, Maddern GJ. Transanal endoscopic microsurgery: a systematic review. *Dis Colon Rectum* 2005; 48: 270-84.
3. Darwood RJ, Wheeler JM, Borley NR. Transanal endoscopic microsurgery is a safe and reliable technique even for complex rectal lesions. *Br J Surg* 2008; 95: 915-8.
4. Saclarides TJ. Transanal endoscopic microsurgery. *Surg Clin North Am* 1997; 77: 229-39.
5. Said S, Stippel D. Transanal endoscopic microsurgery in large, sessile adenomas of the rectum. A 10-year experience. *Surg Endosc* 1995; 9: 1106-12.
6. Winde G, Schmid KW, Reers B, Bunte H. Microsurgery in prospective comparison with conventional transanal excision or anterior rectum resection in adenomas and superficial carcinomas. *Langenbecks Arch Chir Suppl Kongressbd* 1996; 113: 265-8.
7. Mörschel M, Heintz A, Bussmann M, Junginger T. Follow up after transanal endoscopic microsurgery or transanal excision of large benign rectal polyps. *Langenbecks Arch Surg* 1998; 383: 320-4.
8. Nagy A, Kovacs T, Berki C, Jano Z. Surgical management of villous and tubulovillous adenomas of the rectum. *Orv Hetil* 1999; 140: 2215-9.
9. Maslekar S, Pillinger SH, Monson JR. Transanal endoscopic micro surgery for carcinoma of the rectum. A 10-year experience. *Surg Endosc* 1995; 9: 1106-12.

10. Endreseth BH, Wibe A, Svinsas M, Marvik R, Myrvold HE. Postoperative morbidity and recurrence after local excision of rectal adenomas and rectal cancer by transanal endoscopic microsurgery. *Colorectal Dis* 2005; 7: 133-7.

11. Buess G, Theiss R, Gunther M, Hutterer F, Pichlmaier H. Transanal endoscopic microsurgery. *Leber Magen Darm* 1985; 15: 271-9.

Received/Başvuru: 06.03.2014, Accepted/Kabul: 02.04.2014

Correspondence/İletişim

Cemalettin KOÇ  
İnönü Üniversitesi Tıp Fakültesi, Genel Cerrahi Anabilim Dalı,  
MALATYA, TÜRKİYE  
E-mail: ckoc\_41@hotmail.com



For citing/Atf için

Gonultas F, Koc C, Hatipoglu S, Yonder H, Karakas S, Ates M, Dirican A. Laparoscopic transanal endoscopic microsurgery via single-port: a case report. *J Turgut Ozal Med Cent* 2015;22:37-9 DOI: 10.7247/jtomc.2014.1889