

## Radiological and Histopathological Evaluation in Reduction Mammoplasty

Hidir Kilinc, Omer Elmas, Bilge Turk Bilen

Department of Plastic Surgery, İnönü University, Medical Faculty, Malatya

### Abstract

**Aim:** Mammography and ultrasonography are helpful diagnostic methods for the detection of asymptomatic lesions prior to reduction mammoplasty operations. Preoperative radiological evaluation does not give accurate results all time. Consequently, preoperative radiological and postoperative histopathologic evaluation were used together in order to diagnose the premalignant and silent cancer foci.

**Material and Methods:** In our clinic, 135 patients underwent reduction mammoplasty operation between 2007 and 2011. The age of the patients ranged from 18 to 67 (mean 44.6). Ultrasonography was performed for all the patients and mammography was performed additionally for the ones older than 40 years of age. The excised tissue samples were sent for histopathologic evaluation.

**Results:** Preoperative radiologic evaluation, USG results were assessed as normal in 96 patients (71,1%) and, of the patients, % 8,1 had fibrocystic changes, 0,7% had lipoma, 4,4% had fibroadenoma and 2,9% had benign lymph node.

In the histopathologic evaluation, 7% had mild epithelial hyperplasia, 4,8% had severe epithelial hyperplasia, 25,9% had fibrocystic changes, 16,2% had fibrosis, 9,6% had fatty breast tissue, 7,7% had apocrine metaplasia, 4,4% had ductal ectasia, 3,7% had focal adenosis, 4,4% had mild ductal hyperplasia, 3,7% had fibroadenoma and 12,2% had normal breast tissue.

**Conclusion:** In this study, non-proliferative benign changes were seen in the 87,6% of the breast tissue samples. No premalignant or malignant lesions were detected. These results revealed that preoperative radiologic evaluation and postoperative histopathologic analysis were significant in terms of diagnosis of benign, premalignant or silent malignant lesions of the breast.

**Key Words:** Reduction Mammoplasty; Histopathologic Evaluation; (Ultrasonography; Mammography).

### Redüksiyon Mammoplastide Radyolojik ve Histopatolojik Değerlendirme

#### Özet

**Amaç:** Mammografi ve Ultrasonografi (USG), redüksiyon mammoplasti öncesinde asemptomatik lezyonların tespit edilmesinde yardımcı tanı yöntemleridir. Ancak preoperatif radyolojik değerlendirme her zaman kesin sonuçlar vermemektedir. Bu nedenle premalign lezyonların veya sessiz kanser odaklarının tanısı amacıyla, preoperatif radyolojik inceleme ve postoperatif histopatolojik değerlendirme birlikte kullanıldı.

**Gereç ve Yöntemler:** Kliniğimizde, 2007-2011 yılları arasında 135 hastada redüksiyon mammoplasti ameliyatı yapıldı. Hastaların yaşları 18 ile 67 arasında değişmekteydi (ortalama 44,6 yıl). Operasyondan önce tüm hastalarda USG ve 40 yaş üstündeki hastalarda ek olarak mammografi yapıldı. Çıkarılan tüm doku örnekleri histopatolojik olarak incelendi.

**Bulgular:** Preoperatif olarak yapılan radyolojik incelemede; 96 hastada (%71,1) USG sonuçları normal olarak değerlendirildi. %8,1 Fibrokistik değişiklik, %0,7 lipoma, %4,4 fibroadenoma, %2,9 benign lenf nodu olduğu tespit edildi. Histopatolojik olarak yapılan incelemede; %7 hafif-orta epitelyal hiperplazi, %4,8 ağır epitelyal hiperplazi, %25,9 fibrokistik değişiklik, %16,2 fibrozis, %9,6 yağdan zengin meme dokusu, %7,7 apokrin metaplazi, %4,4 duktal ektazi, %3,7 fokal adenozis, %4,4 hafif-orta dereceli duktal hiperplazi, %3,7 fibroadenoma ve %12,2 normal meme dokusu olarak değerlendirildi.

**Sonuç:** Bu çalışmada, meme dokusu örneklerinde %87,6 oranında non-proliferatif benign değişiklikler olduğu görüldü. Premalign veya malign lezyona rastlanmadı. Bu sonuçlar, preoperatif radyolojik değerlendirme ve postoperatif histopatolojik incelemenin, memenin benign, premalign veya sessiz malign lezyonlarının tanısındaki önemini göstermesi açısından anlamlı bulundu.

**Anahtar Kelimeler:** Redüksiyon Mammoplasti; Histopatolojik İnceleme; (Ultrasonografi; Mammografi).

## INTRODUCTION

Macromastia is very common in Anatolian women due to their racial property where as there is not a certain data in our country. It is predicted that reduction mammoplasty is the second frequent

among the plastic surgery operations.

Macromastia is associated with uncomfortable symptoms, including neck, back, shoulder and chest pain, bresiere tab vestige, chronic dermatitis in the submamary folds, stooped posture and movement diffucultier in daily activities. Patients

with macromastia are relieved from these symptoms after reduction mamoplasty operations.

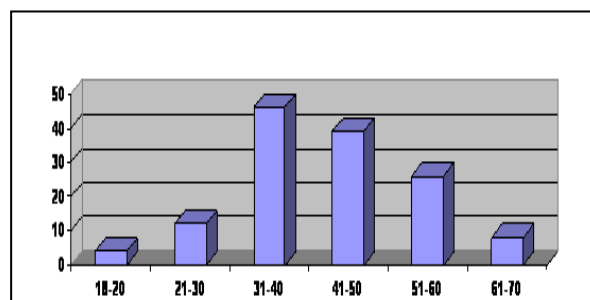
High ratio of patients leave satisfied after the operation. Breast cancer is seen in every woman from eight (%12.7) (1). Breast cancer is seen at this frequency is not a surprise to coincidence from reduction mamoplasty specimens. Inspection of specimens after reduction; coincidence rate of malignity is between %0,06- 0,4 among most of the studies. Inspection at reduction mamoplasty patients' specimens; frequently fibrocystic changes and atypical breast lesions are coincided (2,3). Atypical ductal hyperplasia and atypical lobular hyperplasia are shown as risk factors for breast cancer growth (4). Coincidence to these kinds of specimens is important for taking precautions against occurrence of a breast cancer.

Many techniques are used of reduction mamoplasty and also there are differences from technique to technique which are used in taking lump localization from the breast. The objective of this study is comparison of USG, mammography and pathology results preoperatively and postoperatively and also comparison of operative techniques used for reduction mamoplasties.

## MATERIAL AND METHODS

At Turgut Ozal Medical Center between 2007 - 2011 years, reduction mamoplasty operated by the same group on 135 patients and whose folders are retrospectively inspected. Patients' age range was between 18-67, the average age was 44.6. Most of our patients were between 30-50 years age (Table 1).

**Table 1.** Age group of patients.



The technique that applied on patients is categorized according to before operation USG

and mammography reports, after operation pathology results. Before operation; there was not any breast neoplasm, neither patients nor their families. The preoperative investigation routinely performed included radiological examination, ultrasound scanning or digital mammography. For patients younger than 40 years of age, ultrasound scanning was requested. In patients older than 40 years of age, mammography and USG were the routine examination. To 135 patients, eighth techniques as; 65 McKissock, to 12 patients medial pedicle, 10 free nipple, 27 inferior pedicle, 3 vertical pedicle, 9 superomedial, 7 superior pedicle and 2 lateral pedicle were used and operated. Equable USG results were inspected pre-operation for the last time and searched whether there was particularity or not. Excisions, appropriate techniques for patients and all left-right specimen differences were made and sent to pathology lab in a formol. The mean weight of the resected single breast tissue was 1060 g (300-2600 g). At the time of operation; in the case that coincidence to suspicious tissues' samples which are independent from USG, were designated as localization and sent to the pathology laboratory for sectioning and gross examination, including weight and size measurements. At the end of the operation, all breast tissue is identified and sent to the pathologist. Several slices no thicker than 0.5 mm are randomly made in the whole specimens. The tissue is cut, imitating the leaves of a book, and is then closely examined, slice by slice, for any areas judged to be conspicuous, hard, or suspicious by appearance or tactile sensation. All suspected areas are then fixed in paraffin and formaldehyde for 24 hours. After this time, each paraffin block is cut and the sections are stained using routine hematoxylin and eosin. In certain cases, when suspicious areas are seen during the visual examination, two or three slices are chosen for microscopic examination. In this way, the pathologist is able to identify small dysplastic lesions, inflammatory lesions, and neoplastic lesions under the microscope.

## RESULTS

Evaluation to preoperative radiologic findings of patients; from 96 patients radiological results as normal (%71,1), from 11 patients fibrocystic

changes (%8,1), from 1 patient lipoma (0,7), from 6 patients fibroadenoma (%4,4) and from 4 patients benign lenf node (%2,9) were detected at aksilla. Total 135 patients' 270 breast spesmen inspection; 19 slight- average epteliyal hiperplazi (%7), 13 heavy epteliyal hiperplazi (%4,8), 70 fibrocystic (%25,9), 44 fibrosis (%16,2), 26 adipoz rich breast tissue (%9,6), 21 apocrin metaplasia (%7,7), 12 duct ectasia (%4,4), 10 focal adenosis (%3,7), 12 slight- average ductal hyperplasia (non-atypical) (%4,4), 10 fibroadenoma (%3,7) and from 33 breast spesmen reported as normal breast tissue (%12,2) (Table 2). We have never met malignity from any of our patients. The patients where abnormal findings detected were followed up by breast surgery department.

**Table 2.** Result of histopathological examination.

Fibrocystic	70(%25,9)
Fibrosis	44(%16,2)
Adipoz rich breast tissue	26(%9,6)
Apocrin metaplasia	21(%7,7)
Duct estasia	12(%4,4)
Focal adenosis	10(%3,7)
Slight-average ductal hyperplasia (non-atypical)	12(%4,4)
Fibroadenoma	10(%3,7)
Slight-average epteliyal hiperplazi	19(%7)
Heavy epteliyal hiperplazi	13(%4,8)
Normal breast tissue	33(%12,2)

## DISCUSSION

Reduction mammoplasty is one of the most cosmetic-reconstructive procedures of plastic surgeons. Surgeons have difficulty in deciding and determining the correct oncologic treatment because of this patient population age and potentially develop breast cancer. From the analysis of the surgical specimens, a high frequency of breast pathology was found in asymptomatic patients. It is notable that in a total of 270 histopathological sample examinations in 135 patients, normal breast parenchyma was found in only 33 breast specimens. When the glandular and ductal elements and the connective tissues do not show morphological changes, with a perfect balance among the different tissues; a breast is understood as "normal".

Fibroadioposity usually found in breast tissue. The fibroadiposity is characterized by the almost nonexistence of glandular elements, a few ducts, fat tissue with prominent hyperplasia and fiber threads in higher or lower intensity (5,6).

The prevalence of fibroadenomas is approximately 8%-10% in women older than 40 years. After breast cancer; fibroadenomas are the second most common solid tumor and the most common benign tumor among women. Fibroadenoma is the most commonly diagnosed breast tumor among women younger than 30 years. In the current study, fibroadenomas represent 42.4% of all identified benign conditions and most cases were detected among non-married patients. According to the previous reports; the fibroadenoma can occur in all age groups, but it is mostly seen in young women from 20 to 35 years of age (7). Two components that characterize Fibroadenoma are histopathologically: a prolific stroma of connective fibrosis and one epithelial element (ductal and acini), so that the connective component predominates. There are two histological types: the pericanalicular, in which the fiber connective tissue is predominant and surrounds the glandular space, and the intracanalicular, in which the fiber tissue invades into the ducts. Both patterns often coexist in the same tumor (8,9).

Particularly premenopausal women between the ages of 20 and 50 years have more risk of fibrocystic breast. Chart reviews studies indicate that  $\approx 60\%$  of women referred for evaluation of breast symptoms receive a diagnosis of a benign condition. Of these benign conditions, fibrocystic changes are the most common, and between 30% and 70% of these lesions show evidence of epithelial hyperplasia or proliferation (10). Although nonproliferative fibrocystic conditions have been associated with little or no increase in breast cancer risk (0-2%), proliferative fibrocystic conditions have been associated with a 1.5- to 4-fold increased risk of breast cancer, with the greatest increase in women with atypia (11).

Apocrine change in the breast is seen in a broad spectrum of lesions ranging from microscopic cysts to invasive apocrine carcinoma. Not only some of these lesions are difficult to categorise, but also there are controversy regardings for their

relative risk of subsequent carcinoma development. Fibrocystic change, fibroadenomas, hamartomas, papillomas, sclerosing adenosis and apocrine adenoma are all benign breast lesions that can show apocrine change as one of their histological features. Apocrine lesions can be divided into two categories as; simple and papillary apocrine changes, those of uncertain significance, those found in association with other lesions, apocrine ductal carcinoma in-situ and invasive apocrine carcinoma. In addition to carcinomas with obvious apocrine differentiation, other carcinomas have some apocrine features and it may be that a significant number of breast tumours arise from apocrine epithelium or that a significant number can express some apocrine features (12).

The breast cancer which occurs with a peak incidence at or after menopause is rarely found before the age of 35 (13). Curiously, carcinoma is more common in the left breast than in the right, at a ratio of 110:100 (14). Ductal carcinoma in situ, also known as intraductal carcinoma, is considered a lesion associated with breast cancer; histopathologically it is characterized by atypical proliferation of the papillary epithelium intraductal (15,16). More than 90 percent of breast carcinomas arise within the ducts (14).

A histologically unique lesion manifested by proliferation in one or more terminal ducts or ductules (acini) in situ is of lobular carcinoma. It can be seen in breasts removed for fibrocystic disease in the vicinity of invasive carcinoma or admixed with intraductal carcinoma (14,17).

After treatment of primary breast cancer the higher incidence of contralateral breast cancer is well recognized. In a large case series demonstrated that 1.6 percent of breast cancer patients were found to have invasive breast cancer at time of breast reduction in the contralateral breast (18).

An important screening method for the early detection of breast cancer is mammography. When an abnormality which shows suspicious features of cancer is detected on the mammogram, it requires related to surgery techniques. In our study; there has been no difference detected between surgery

recalling screened women for further assessment. This is then investigated either with further mammographic views, ultrasound, or tissue sample. The surgical removal of breast tissue can produce a spectrum of mammographic changes. The typical postoperative changes have been well characterized and include a high nipple position and skin thickening (in the periareolar region or inferior to the nipple line) (19). Using fibrosis; a redistribution of the parenchyma inferior to the nipple and non-anatomical retroareolar band-like thickenings might be developed. Fat necrosis with the formation of characteristic oil cyst calcification or calcification along suture lines can be caused by the post-surgical changes.

Many variations in the technique of breast reduction have been described. The surgical excision site differs according to the surgical technique.

In our study; eight different techniques were used on 135 operated patients. Examining after operation specimens, among surgical techniques pathological differences have not been detected. Contrary to evaluation of 96 operated patients' pre-operation radiological results as normal, after operation histologic examining evaluated only 33 (12.2 percent) histologic results as normal and 237 (87,6 percent) specimens found premalign changes. The highest frequency of breast pathology corresponded to benign lesions: fibrosis and fibrocystic changes were seen in 42.1 percent of cases (Table 2). Fibroadenoma were found in 3.7 percent of the patients. Twenty-one specimens (%7,7 percent) had apocrin metaplasia and twelve specimens (% 4,4 percent) had duct ectasia. This rate was concordant with literature. It has been accepted by the authors that these changes do not have risk about breast cancer since these are non-proliferative lesions (20). In our study; totally 135 patients have been operated and from none of these patients malignity have not found.

In contrast to many studies about evaluations of pathology results which are belong to after operation reduction mamaoplasty at the literature; there have been no studies about comparisons

technique with after operation specimens and pathology detection. It seemed that there has been

no correlation between pre-operation radiologic examinations with specimens examination. Reason of this is thought as; similarities among the textures which had been taken by techniques and also the quality of radiologic examination could be a factor. Our study has been manifested that whatever the result of pre-operation's radiologic examination; the histopathological evaluation of tissue samples (reduction material) of all the patients is quite important for the diagnosis of benign or premalignant lesions.

## REFERENCES

1. Clancy J. Clark, Susan Whang, Keith T. Paige. Incidence of precancerous lesions in breast reduction tissue: A pathologic review of 562. *Plast Reconstr Surg* 2009;124:1033.
2. Boice JD, Friis S, McLaughlin JK, et al. Cancer following breast reduction surgery in Denmark. *Cancer Causes Control* 1997;8:253-58.
3. Tang CL, Brown MH, Levine R, Sloan M, Chong N, Holowaty E. A follow-up study of 105 women with breast cancer following reduction mammoplasty. *Plast Reconstr Surg* 1999;103:1687-90.
4. Carter CL, Corle DK, Micozzi MS, Schatzkin A, Taylor PR. A prospective study of the development of breast cancer in 16,692 women with benign breast disease. *Am J Epidemiol* 1988;128:467-77.
5. Robbins, S. L. *Pathologic Basis of Diseases*, 4th Ed. Philadelphia: Saunders, 1989:1181-201.
6. Silverstein, M. J., Sartorius, W., and Zarem, H. A. Pathology of the breast for plastic and reconstruction surgeons. In R. M. Goldwyn (Ed.), *Plastic and Reconstruction Surgery of the Breast*, 1st Ed. Boston: Little, Brown, 1976:59-81.
7. Ahmed HG, Ali AS, Almobarak AO. Frequency of breast cancer among sudanese patients with breast palpable lumps. *Indian J Cancer* 2010;47:23-6.
8. Pitanguy, I., and Torres, E. Histopathological aspects of mammary gland tissue in cases of plastic surgery of breast. *Br J Plast Surg* 1964;17:297.
9. Pitanguy, I., Torres, E., and Zelicovich, R. Histopathological aspects of mammary gland tissue in cases of plastic surgery of breast. *Br J Plast Surg* 1964;17:297.
10. Bodian CA, Perzin KH, Lattes R, Hoffmann P, Abernathy TG. Prognostic significance of benign proliferative breast disease. *Cancer* 1993;71:3896-907.
11. Shannon J., King J.B., Lampe J.W., Gao D.L., Ray R.M., Lin M.G, Stalsberg H., Thomas D.B. Erythrocyte fatty acids and risk of proliferative and nonproliferative fibrocystic disease in women in Shanghai, China . *Am J Clin Nutr* 2009;89:265-76.
12. Wells CA, El-Ayat GA. Non-operative breast pathology: apocrine lesions. *J Clin Pathol* 2007;60:1313-20.
13. Wilson, R. W. Perspectives from a surgical oncologist: The history of breast cancer. In R. M. Goldwyn (Ed.), *Plastic and Reconstruction Surgery of the Breast*, 1st Ed. Boston: Little, Brown, 1976:431-40.
14. Silverstein, M. J, Sartorius, W, and Zarem, H. A. Pathology of the breast for plastic and reconstruction surgeons. In R. M. Goldwyn (Ed.), *Plastic and Reconstruction Surgery of the Breast*, 1st Ed. Boston: Little, Brown, 1976:59-81.
15. Andersen, J. A. Lobular carcinoma in situ: An approach to rational treatment. *Cancer* 1977;39:2597.
16. Dinner, M. I., and Artz, J. S. Carcinoma of the breast occurring in routine reduction mammoplasty. *Plast Reconstr Surg* 1989;83:1042-4.
17. Robbins, S. L. *Pathologic Basis of Diseases*, 4th Ed. Philadelphia: Saunders, 1989:1181-201.
18. Petit JY, Rietjens M, Contesso G, Bertin F, Gilles R. Contralateral mastoplasty for breast reconstruction: A good opportunity for glandular exploration and occult carcinomas diagnosis. *Ann Surg Oncol* 1997;4:511-5.
19. Miller CL, Feig SA, Fox JW. Mammographic changes after reduction mammoplasty. *AJR Am J Roentgenol* 1987;149:35-8.
20. Clark C.J., Susan Whang S., Paige K.T. Incidence of precancerous lesions in breast reduction tissue: A pathologic review of 562 consecutive patients. *Plast Reconstr Surg* 2009;124:1033-9.

Received/Başvuru: 16.05.2012, Accepted/Kabul: 13.11.2012

## Correspondence/İletişim

**Hidir KILINC**  
Inonu University, Medical Faculty, Plastic,  
Reconstructive and Aesthetic Surgery Department 44069,  
MALATYA/TURKEY  
Tel: 0422 3410660  
E-mail: hidir.kilinc@inonu.edu.tr

## For citing/Atıf için:

Kilinc H, Elmas O, BT Bilen. Radiological and histopathological evaluation in reduction mammoplasty. *J Turgut Ozal Med Cent* 2013;20(1):19-23 DOI: 10.7247/jtomc.20.1.5