



Hydatid Disease With Rare Localizations: A Case Report

M. Tayfun Altınok*, Süleyman Kılıç**, Ahmet Sığırcı*, Alpay Alkan*, Ramazan Kutlu*,
Tamer Baysal*, İsmet Aydoğdu***

* İnönü University School of Medicine, Department of Radiology, Malatya, Turkey

** İnönü University School of Medicine, Department of Urology, Malatya, Turkey

*** İnönü University School of Medicine, Department of Internal Medicine, Malatya, Turkey

Introduction: When the disease is in rare localization and especially has not a typical appearance of hydatid cyst, incorrect definitive diagnosis may be defined mistakenly, since the disease may be easily missed unless being careful.

Case Report: We present a patient affected by echinococcosis with rare localizations such as thyroid, abdominal wall and kidney.

Discussion: Especially in endemic and sporadic echinococcosis areas, hydatid disease must be always considered wherever cysts are established.

Keys Words: Hydatid Disease, Thyroid, Abdominal Wall, Kidney, Computed Tomography.

Nadir Yerleşimli Kist Hidatik : Olgu Sunumu

Giriş: Hidatik kist, nadir yerleşim yerinde olduğunda ve özellikle tipik görünümde olmadığında, akılda tutulmadığı takdirde kolaylıkla atlanabileceğinden hatalı kesin tanı yanlışlıkla konulabilir.

Olgu Sunumu: Tiroid, karın duvarı ve böbrek gibi nadir yerleşim yerleri ile ekinokokkozisten etkilenmiş bir olguyu sunduk.

Sonuç: Özellikle endemik ve sporadik ekinokokkozis bölgelerinde, kistler her nerede saptanırsa saptansın, hidatik kist her zaman düşünülmelidir.

Anahtar Kelimeler: Kist Hidatik, Tiroid, Abdominal Duvar, Böbrek, Bilgisayarlı Tomografi

Hydatid disease (HD), also known as ‘echinococcosis’ is a parasitic disease most commonly caused by *Echinococcus granulosus* that is usually endemic in Asia, Australia, South America, Mediterranean countries, especially in sheep-raising and cattle raising areas. Most hydatid cysts occur in the liver (%75), followed in frequency by the lung (%15). Involvements of the kidney (%3), bone (%1-4) and brain (%1-2) are rare. Other sites such as the heart, spleen, pancreas and muscle are rarely involved, but it may develop in almost any part of the body.^{1,2} This case is reported because of the rare localizations of the disease in same patient.

CASE REPORT

A 15-year-old male was admitted to the hospital because of a 2-year history of slowly enlarging mass in his neck and 2-weeks history of abdominal mass. He had no complaint except the mass lesions. Patient’s history revealed that, he had had only neck mass 2 years ago and he had been diagnosed as having euthyroid goiter. At that time, only a thyroid ultrasound had been performed to the patient and we could not obtain that report. The patient was admitted to the hospital with the complaints of recently developed abdominal mass in addition to slightly growing neck mass.

His physical examination revealed 4x5 cm mass in the neck and 5x8 cm mass in right upper abdominal wall. A thyroid ultrasound showed two well-defined fluid-filled cystic structures in the isthmus and left lobe. An abdominal ultrasound revealed cystic lesions with similar characteristics in abdominal wall, liver and left kidney. After ultrasound examinations, patient was evaluated on a computed tomography (CT). All of CT examinations were performed with i.v.-contrast administration. Computed Tomography of the neck showed two cysts in isthmus and left lobe of

thyroid with sharp and thin margins exhibiting no contrast enhancement and containing fluid (Fig. 1a).

Figure 1a- CT of the neck shows a sharp and thin walled cystic mass with fluid content in the left lobe of thyroid

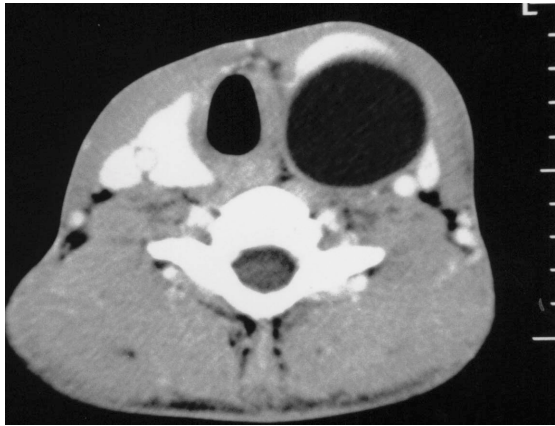
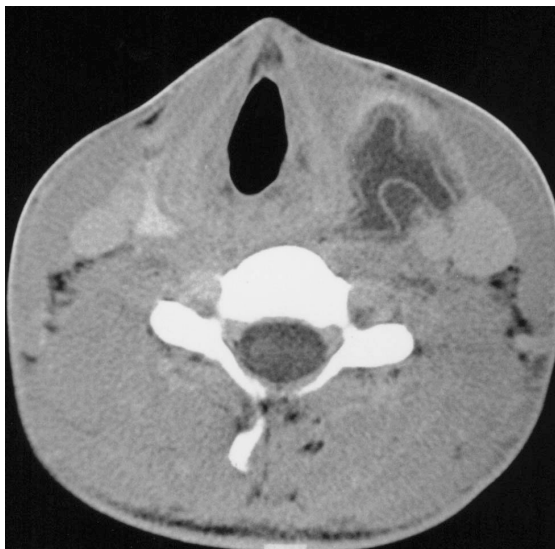
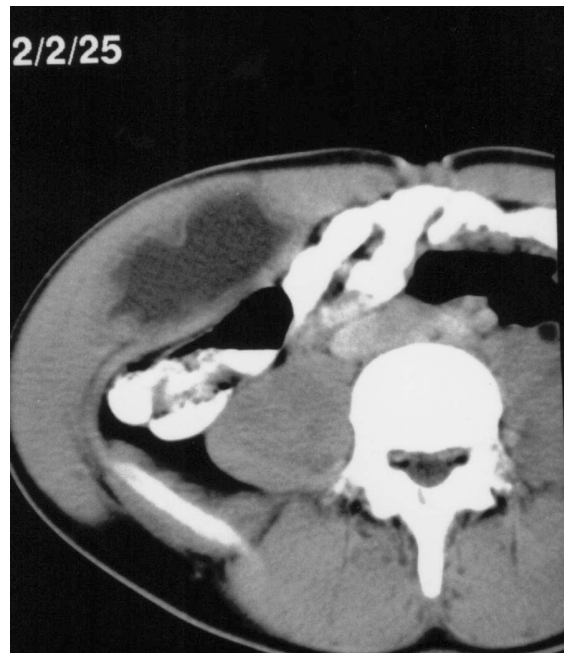Figure 1b- After a medical treatment, thyroidal cyst showed diffuse membrane detachment indicating hydatid disease and regression in a size.



On an abdominal CT, left renal cyst and liver cysts were identified with same findings. Cardiac ultrasound and cranial CT was normal, but chest CT showed a unilocular cystic lesion in the right lung with a homogeneous fluid content showing water attenuation values and a thin walled structure. In all of cysts, no daughter cysts or calcification of the wall were noticed. On a thyrooid scan, cystic lesions were defined as hypoactive cold nodules. Following positive serologic tests results, the patient was accepted as multiple HD. No operation was recommended because of multiple cysts and the

patient was treated with 400 mg. mebendazole per day. 2-months later, CT examinations were performed again. At this time, significant regression was determined in cysts sizes. Contrast-enhanced CT scans demonstrated typical membrane detachment at the inner layer of thyrooid cysts (Fig. 1b), abdominal wall cyst (Fig. 1c) and liver cysts. Although renal cyst appearance was unilocular, there was a small area at the lateral margin of the cyst with detached membrane (Fig 1d). On chest CT, right lung hydatid cyst was seen as small constricted lesion containing air density because of bronchial rupture with thick and irregular wall structure. Cyst rupture occurred spontaneously and did not cause any clinical problem such as anaphylactic reaction.

Figure 1c- CT of the abdomen shows right abdominal wall hydatid cyst with diffuse detached membrane.



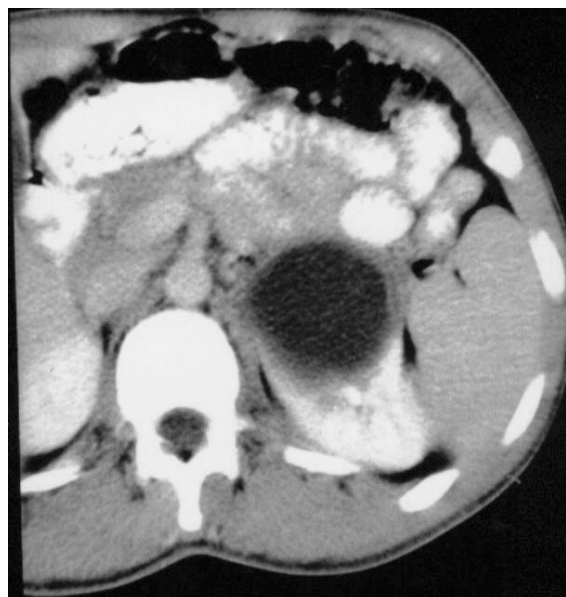
DISCUSSION

HD is often manifested by slowly growing cystic mass. Symptoms develop when the cyst enlarges sufficiently to be a space-occupying mass. Cysts may be single or multiple, uni- or multiloculated, and thin- or thick walled. The diagnosis of hydatid cyst relies on serologic tests and imaging techniques. Sonography, CT, and magnetic resonance imaging are useful for delineating the location of the cyst, but the findings are nonspecific. Presence of daughter cysts, membrane detachment and wall calcifications are specific signs and facilitate differential diagnosis.

Hydatid Disease With Rare Localizations: A Case Report

However, hydatid cysts in unusual localizations with simple cyst appearance may cause serious diagnostic problems.³ The disease may also mimic benign or malignant tumors, single or multiple metastases, abscesses, empyemas, infarcts, and other lesions.⁴

Figure 1d- CT of the upper abdomen after a treatment showed small membrane detachment in a lateral margin of the renal hydatid cyst.



Soft tissue HD occurs in 2.3% of patients reported from endemic areas. Thyroid and abdominal wall involvement is extremely rare and they are usually associated with involvement of other structures.⁵ A palpable mass is the most constant clinical or exploratory finding of HD affecting soft tissues. Also slowly enlarging neck mass was the first complaint of our patient. Kidney involvement is rare and constitutes only 2-3% of all patients of HD. Mural

calcification and multiple daughter cysts within a large cyst may occur and the presence of these two findings help in differentiating the lesion from simple cyst.^{6,7} In our patient, renal cyst did not show any specific finding. Small membrane detachment after medical treatment was observed. Also liver and lung cysts were determined in our patient in addition to cysts located in rare sites. Moreover, hydatid cyst of the right lung ruptured into bronchus which could have caused to anaphylaxis because of antigenic fluid content.

In the present case we experienced that the evaluation of a simple neck mass revealed a disseminated form of hydatid disease with unusual localizations. In conclusion, hydatid disease should be included in the differential diagnosis of cystic masses in any part of the body, especially in endemic countries.

REFERENCES

1. Beggs I. The radiology of hydatid disease. *AJR* 1985;145:639-648
2. Dahniya MH, Manna RM, Ashebu S et al. The imaging of hydatid disease at some unusual sites. *Br J Radiol* 2001;74:283-289
3. Engin G, Acunaş B, Rozanes İ, Acunaş G. Hydatid disease with unusual localization. *Eur Radiol* 2000;10:1904-1912
4. Reeder MP. *The radiology of tropical disease with epidemiological, pathological and clinical correlation*. Williams and Wilkins, Baltimore, 1981
5. Chevalier X, Rhamouni A, Bretagne S, Martigny J, Larget-Piet B. Hydatid cyst of the subcutaneous tissue without other involvement: MR imaging features. *AJR* 1994;163:645-646
6. Akhan O, Üstünsöz B, Somuncu İ et al. Percutaneous renal hydatid cyst treatment: long-term results. *Abdo Imaging* 1998;3:209-213
7. Gossios KJ, Kontoyannis DS, Dascalogiannaki M, Gourtsoyannis NC. Uncommon locations of hydatid disease: CT appearances. *Eur Radiol* 1997;7:1303-1308.

Corresponding Author:

Dr. M. Tayfun Altınok
Department of Radiology, Turgut Özal Medical Center, İnönü
University, Elazığ yolu 12.km, 44069, Malatya/TURKEY
Tel: +905323166062
Fax: +904223410729
E-Mail: taltinok@ttnet.net.tr