

# The Beneficial Effects of Vitamin D3 Against Trichloroethylene Toxicity in Rat Ovaries

<sup>1</sup>Helin BAĞCI<sup>a</sup>, <sup>2</sup>Rauf MELEKOĞLU<sup>b</sup>, <sup>3</sup>Ebru ÇELİK KAVAK<sup>c</sup>, <sup>4</sup>Tuncay KULOĞLU<sup>d</sup>,  
<sup>5</sup>Mehmet ŞİMŞEK<sup>e</sup>

<sup>a</sup>Karabük Training and Research Hospital, Department of Obstetrics and Gynecology, Karabük, TURKEY

<sup>b</sup>İnönü University Faculty of Medicine, Department of Obstetrics and Gynecology, Malatya, TURKEY

<sup>c</sup>Fırat University Faculty of Medicine, Department of Obstetrics and Gynecology, Elazığ, TURKEY

<sup>d</sup>Fırat University Faculty of Medicine, Department of Histology and Embryology, Elazığ, TURKEY

<sup>e</sup>Adıyaman University, Department of Obstetrics and Gynecology, Adıyaman, TURKEY

**ABSTRACT Objective:** Vitamin D3 is an active metabolite of vitamin D and has been reported to have anti-oxidative effects due to inhibition of lipid peroxidation in some tissues both in vitro and in vivo studies. The current study was carried out to assess the protective effects of vitamin D3 on experimental trichloroethylene (TCE) toxicity in rat ovaries by using immunohistochemical detection of malondialdehyde (MDA) in tissues as well as histopathological scores' computation. **Material and Methods:** Twenty-four healthy rats were randomly divided into four equivalent groups: control (sham-operated), TCE+vitamin D3 (1000 mg/kg/day and 50 IU/day, in that order), TCE (1000 mg/kg/day), as well as vitamin D3 (50 IU/day). Histopathological and immunohistochemical analyses were carried out on tissue samples 21 days following exposure to vitamin D3 and TCE. **Results:** Histopathological examination showed a significant decrease of angiogenesis in the corpus luteum and a substantial degeneration in the ovarian follicles and germinal epithelium in ovarian tissues of TCE group. Also, immunohistochemical examination for MDA immunoreactivity revealed that MDA immunoreactivity was significantly increased in the TCE group compared to the control group. We observed that vitamin D3 administration improved histological parameters, which include follicular degeneration as well as germinal epithelium degeneration, limiting TCE's negative impacts on ovarian tissues. It was also confirmed that MDA immunoreactivity was considerably reduced in ovarian tissues in the TCE + vitamin D3 group. **Conclusion:** In this study, the significant improvements observed in immunohistochemical and histopathological tissue oxidative stress parameters indicate that treatment with vitamin D3 could be a conservative method to prevent ovarian TCE toxicity.

**Keywords:** Antioxidants; vitamin D3; ovary; oxidative stress; toxicity; trichloroethylene

Trichloroethylene (TCE) is a chlorinated hydrocarbon that is generally used as a solvent in the industrial process of metal degreasing. The major contributors to human exposure of TCE are a number of commercial products such as parquet cleaning solutions, stain removers, surface adhesives, and wood paints.<sup>1</sup> Owing to environmental contamination, TCE is not found in natural habitat even though it could be detectable in air, surface and underground water.<sup>2</sup>

Therefore, human exposure in general population can occur through ingestion, inhalation or transdermal absorption. The degradation rates of TCE differ according to its physical state and concentration. TCE evaporation from surface water produces TCE vapor in the air with a half-life of one to eleven days.<sup>3</sup>

Several studies have confirmed that exposure to TCE leads to oxidative damage in several tissues such as kidney and liver.<sup>4</sup> Toxic reproductive outcomes

**Correspondence:** Rauf MELEKOĞLU

İnönü University Faculty of Medicine, Department of Obstetrics and Gynecology, Malatya, TURKEY

**E-mail:** rmelekoglu@gmail.com



Peer review under responsibility of Journal of Clinical Obstetrics & Gynecology.

**Received:** 22 Mar 2020

**Received in revised form:** 02 Jun 2020

**Accepted:** 12 Jun 2020

**Available online:** 11 Aug 2020

2619-9467 / Copyright © 2020 by Türkiye Klinikleri. This is an open access article under the CC BY-NC-ND license (<http://creativecommons.org/licenses/by-nc-nd/4.0/>).

have as well been recognized in reproductive tissues which include ovary and testis.<sup>5,6</sup> In an experimental animal model, the liver is the main target organ for the TCE toxicity.<sup>7</sup> The major pathway of TCE metabolism is the cytochrome P450 enzyme-mediated oxidation. CYP2C11/6, CYP2B1/2, CYP2E, and CYP1A1/2 are the primary CYP isoforms involved in the metabolism of TCE. CYP2E1 has a significantly higher affinity for TCE among these CYP isoforms.<sup>8</sup> Besides; a second route could metabolize TCE by conjugating glutathione, and this pathway could be important in the kidneys.<sup>9</sup> The degradation of TCE into more toxic and bioactive products could as well take place in the female reproductive system as a result of the existence of these two pathways in the ovarian tissues.<sup>10</sup> It has been proposed that TCE could exert toxic effects by means of oxidative stress.<sup>11</sup>

Vitamin D3 is the active metabolite of vitamin D and it has several biological roles.<sup>12</sup> Numerous studies have demonstrated the benefits of vitamin D3 including cancer protection, immune system regulation, and endocrine diseases.<sup>13,14</sup> Anti-oxidative effects of vitamin D3 due to inhibition of lipid peroxidation in some tissues such as brain and liver were also reported both in vitro and in vivo studies.<sup>15,16</sup> There is, however, no study on the therapeutic impact of vitamin D3 in the female reproductive system against the oxidative damage caused by TCE toxicity.

This study aims to demonstrate the toxic effects of TCE on ovarian tissues and evaluate the beneficial effects of vitamin D3 on experimental TCE-exposed rat ovaries by using histopathological and immunohistochemical analyses.

## MATERIAL AND METHODS

### STUDY DESIGN

In accordance with the animal ethics guidelines of the Firat University Institutional Animals Ethics Committee (Approval No. 24-221), experiments were carried out. All animals that were involved in experiments have received humane care in compliance with the Guide for the Care and Use of Laboratory Animals ([www.nap.edu/catalog/5140.html](http://www.nap.edu/catalog/5140.html)). In this experiment, we used 24 healthy adult female

Wistar albino rats with the age of eight to ten months that were acquired from the Experimental Animal Institute Elazig, Turkey. These animals were preserved in polypropylene rat cages that were disinfected at controlled conditions of temperature ( $21\pm 2^{\circ}\text{C}$ ) under a 12 h light-dark cycle. There were six rats in each cage. Water and food were given *ad libitum*. Rats were randomly divided into four equal groups ( $n= 6$  for every group) as shown: vitamin D3 (50 IU/day), TCE (1000 mg/kg/day), control (sham-operated) and vitamin D3+TCE (50 IU/day and 1000 mg/kg/day correspondingly). Vitamin D3 and TCE were dissolved in corn oil and orally administered by gavage for twenty-one days. The determination of the dose for TCE dose and the period of vitamin D3 treatment were based on prior studies.<sup>17</sup> Following the period of treatment, the animals were euthanized by using lethal intraperitoneal pentobarbital dose (Bioveta, Ankara, Turkey), and the ovaries were removed with the purpose of histopathological and immunohistochemical analyses. A deep freezer was used in storing tissue samples at  $-80^{\circ}\text{C}$  before carrying out the tissue analyses.

### SURGICAL PROCEDURES

With the use of aseptic procedures, all surgical interventions were carried out in a suitable laboratory setting. Using an intramuscular injection of xylazine (10 mg/kg) and ketamine (50 mg/kg), the rats were anesthetized. After that, the rats were placed in supine position, and the surgical field was sterilized and covered using drapes that were disinfected. In order to avoid hypothermia, the surgical procedures were performed at  $36\pm 1^{\circ}\text{C}$  ambient temperature. In order to reveal the ovaries, a longitudinal midline incision was undertaken in the suprapubic area at roughly 2 cm. The ovarian tissues were then extracted and transferred for dissection straightaway to ice-cold glass.

### HISTOPATHOLOGICAL EXAMINATION

For histopathological evaluation, the ovarian tissues were fixed with 10% formaldehyde solution. Embedded tissues were cut into sections of approximately 4-6  $\mu\text{m}$  thick. On the other hand, Masson Trichrome staining was carried out. These sections were histopathologically examined with the use of a

light microscope (Olympus BX51; Japan, Tokyo, Olympus Corporation). The characteristics of germinal epithelium degeneration, follicular degeneration, and corpus luteum angiogenesis were assessed and scored severe (3), moderate (2), mild (1), and none (0) according to their histopathological status. Nine was the highest score. For each rat, scoring was performed, and for each group, mean values were determined. Furthermore, the primordial follicle's oocyte nucleoli in every ovarian tissue were computed to evaluate ovarian reserve. Consistent with the standards of morphology, ovarian follicles were classified as Gougeon reports.<sup>18</sup>

### IMMUNOHISTOCHEMICAL ANALYSIS

The complex technique of Avidin-Biotin-Peroxidase was applied in determining malondialdehyde (MDA) immunoreactivity of ovarian tissues. There are segments, which had a breadth of 4-6  $\mu\text{m}$ , divided into polylysine slips, that were taken from paraffin blocks. For antigen retrieval, the deparaffinized tissues were passed via a series of graded alcohol and boiled in the microwave oven in citrate buffer solution for 10 minutes, at (750W), pH: 6. After washing with PBS (Phosphate Buffered Saline), it was incubated with hydrogen peroxide block solution for 5 minutes to prevent the activity of endogenous peroxidase (Hydrogen Peroxide Block, TA-125-HP, Lab Vision Corporation). Five minutes later, Ultra V Block (USA, TA-125-UB, Lab Vision Corporation,) solution application, was incubated using a primary antibody of 1/200 dilution (ab6463, Anti-MDA antibody, Abcam, Cambridge) for 60 minutes at room temperature. Leica DM500 microscope was applied in evaluating preparations. Following administration of the primary antibody, washing of tissues with PBS was done in 3x5 minutes and incubated for 30 minutes with secondary antibody at room temperature (biotinylated Goat Anti-Polyvalent (rabbit IgG/anti-mouse), TP-125-BN, USA, Lab Vision Corporation). Tissues were washed with PBS for 3x5 min after application of secondary antibody, incubated with Streptavidin Peroxidase (TS-125-HR, Lab Vision Corporation, USA) for 30 minutes at room temperature and then taken into PBS. The tissues were then added a solution of 3-amino-9-ethyl carbazole (AEC) Substrate + AEC Chromogen (TA-015, AEC Substrate, and TA-

002-HAC, AEC Chromogen, USA, HAS, Lab Vision Corporation), before taking the image signal under the light microscope and instantaneously washing using PBS. Mayer's hematoxylin stained tissues were passed via distilled water and PBS before sealing with suitable closure solution (the USA, Large Volume Vision Mount, Lab Vision Corporation, TA-125-UG).

The formation of histoscore based on the prevalence (0.1: <25%, 0.4: 26-50%, 0.6: 51-75%, 0.9: 76-100%) as well as severity (0: none, +0.5: very little, +1: low, +2: moderate, +3: severe) of immunohistochemical staining. The computation of histoscore was performed as prevalence X severity.

### POWER ANALYSIS

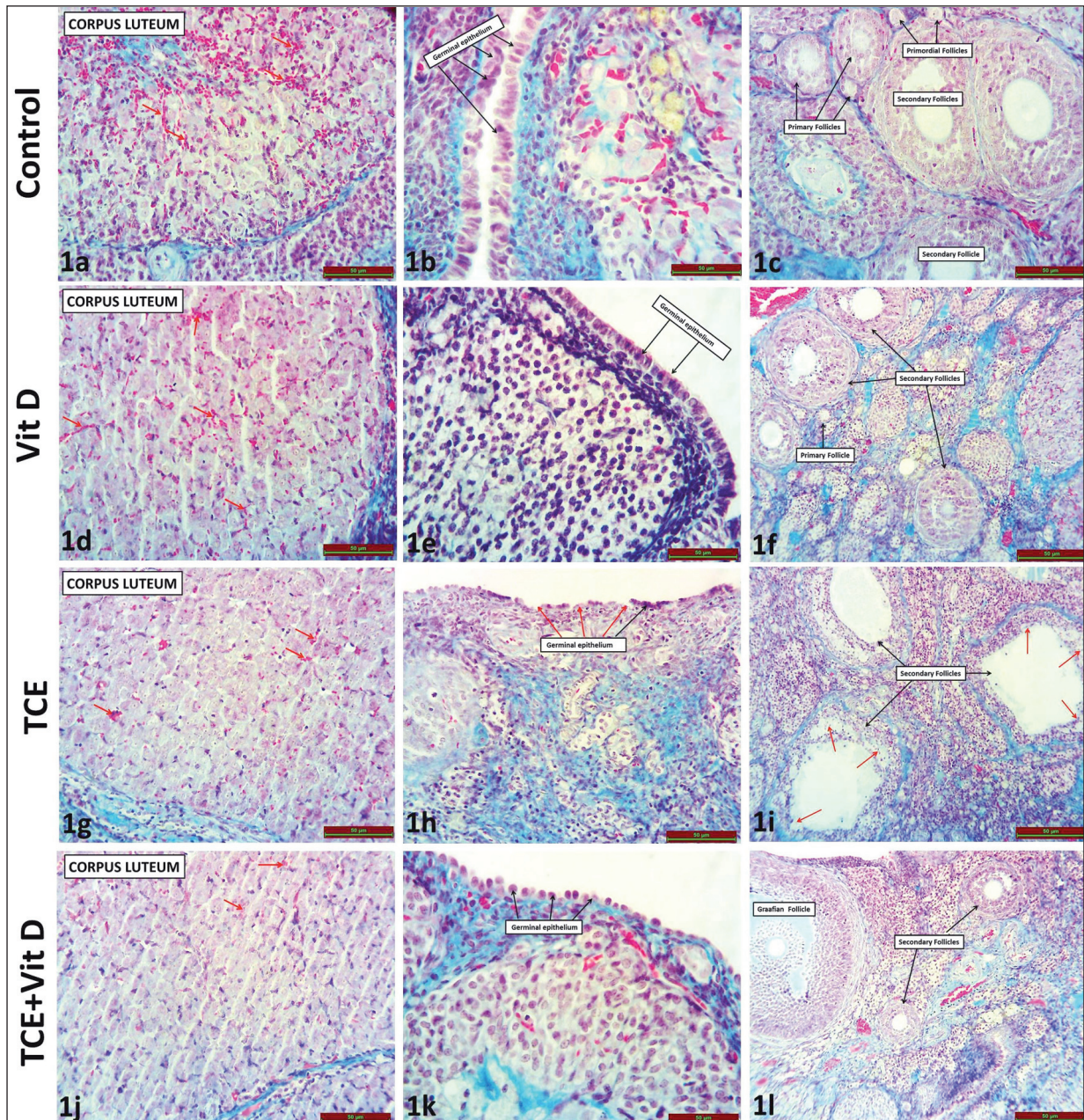
Power analysis suggested that at least 6 rats should be included in each group if the greatest between-group difference in MDA level was 2.2 ng/mL, the standard deviation was 1.8 ng/mL, the type I error 0.05, and the type II error 0.20.<sup>16</sup>

### STATISTICAL ANALYSIS

The presentation of all data was mean  $\pm$  standard deviation. For all data analysis, the statistical software Statistical Package for the Social Sciences, SPSS Inc, version 22.0, New York, USA (SPSS) was applied. With the use of Kruskal-Wallis variance analysis, histological outcomes were analyzed when more than two groups were compared. The Bonferroni post hoc test was used to perform pairwise comparisons of groups. Group means were compared with the use of the Mann-Whitney U test for comparing two groups. P values, < 0.05 that were considered to be significant.

## RESULTS

The control (Figures 1a, 1b, 1c) and Vitamin D3 (Figures 1d, 1e, 1f) groups were similar and ovarian tissues appeared normal under light microscopy by Masson's trichrome staining. When compared with the control group; we observed significantly reduced angiogenesis in the corpus luteum (red arrow) (Figure 1g) ( $p = 0.004$ ), degeneration of the germinal epithelium (red arrow) (Figure 1h) ( $p = 0.002$ ), reduction in ovarian follicle reserve ( $p = 0.002$ ) and increased



**FIGURE 1:** Normal histological appearance of germinal epithelium, corpus luteum and ovarian follicle in the control group (1b, 1a, 1c, in that order) as well as vitamin D3 group (1e, 1d, 1f, correspondingly). Degeneration of follicles (1i), decreased angiogenesis in the corpus luteum (1g), reduction of ovarian follicle reserve and degeneration of germinal epithelium (1h) shown is demonstrated by the red arrow in TCE group. Significant amelioration in follicle degeneration (1l), recovery in the germinal epithelium (1k) and improvement in the angiogenesis of corpus luteum (1j). (Scale bar = 50  $\mu$ m).

follicle degeneration (follicular cell loss + follicular fluid increase) (red arrow) (Figure 1i) ( $p = 0.002$ ) in the TCE group. There was no significant difference in corpus luteum angiogenesis (Figure 1j) ( $p = 0.589$ ) and ovarian reserve ( $p = 0.180$ ) but significant improvement was observed in germinal epithelium (Figure 1k) ( $p = 0.015$ ) and follicle degeneration

(Figure 1j, Figure 1l) ( $p = 0.009$ ) in the TCE + vitamin D3 group compared with TCE group. Table 1 illustrates the groups' histopathologic scores.

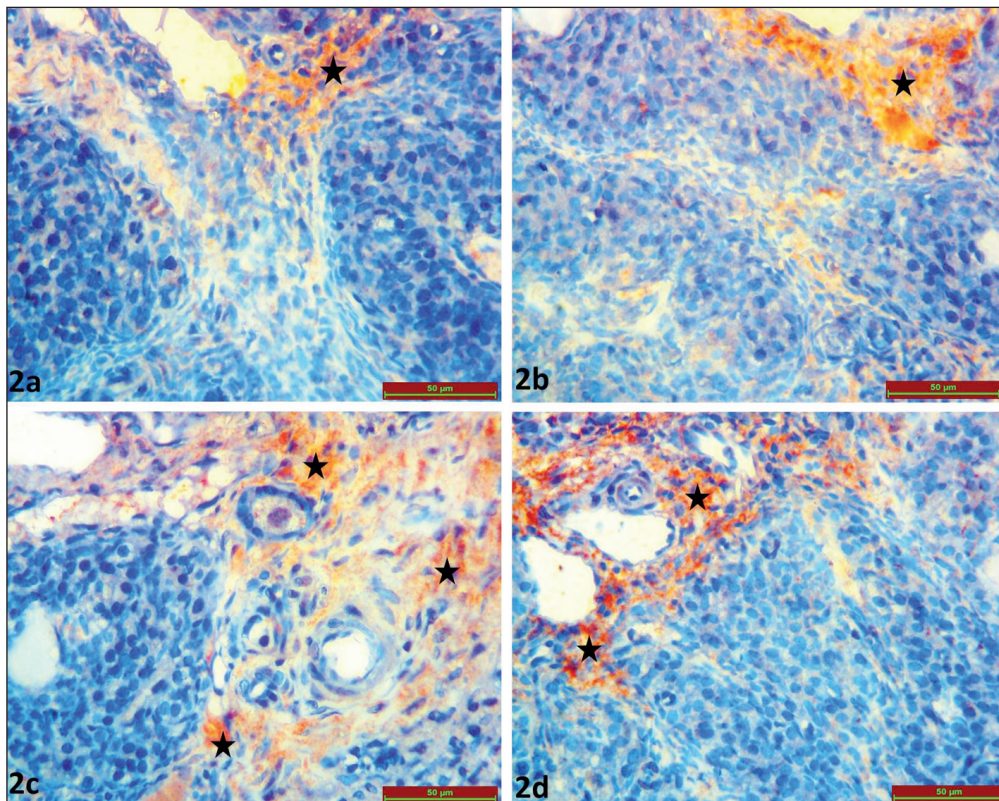
As a result of the examination of immunohistochemical staining for MDA immunoreactivity under light microscopy; MDA immunoreactivity was observed in the stromal area of ovarian tissues

**TABLE 1:** The histopathological score of groups.

	Corpus luteum angiogenesis	Germinal epithelium degeneration	Follicular degeneration	Ovarian reserve
Control	3.00 (2.00-3.00)	0.00 (0.00-1.00)	0.00 (0.00-0.00)	48.00 (45.00-52.00)
Vitamin D3	3.00 (2.00-3.00)	0.00 (0.00-1.00)	0.00 (0.00-0.00)	43.00 (40.00-56.00)
TCE	1.00 (1.00-2.00) <sup>a</sup>	3.00 (1.00-3.00) <sup>a</sup>	2.50 (1.00-3.00) <sup>a</sup>	21.00 (14.00-26.00) <sup>a</sup>
TCE + Vitamin D3	1.50 (1.00-3.00)	1.00 (0.00-2.00) <sup>b</sup>	0.00 (0.00-2.00) <sup>b</sup>	24.50 (21.00-27.00) <sup>a</sup>

MDA: Malondialdehyde

TCE: Trichloroethylene

<sup>a</sup> Values are given as median (minimum-maximum).<sup>a</sup> Compared with the control group (p<0.05)<sup>b</sup> Compared with TCE group (p<0.05).**FIGURE 2:** The appearance of a significant reduction in MDA immunoreactivity in TCE + Vit D group (2d), MDA immunoreactivity in the ovarian tissue's stromal area in the control group (2a) and vitamin D3 group (2b) as well as increased MDA immunoreactivity in TCE group (2c). Scale bar represents 50 µm.

in all groups (black star). MDA immunoreactivity was similar in the control (Figure 2a) and vitamin D3 (Figure 2b) groups ( $p=0.345$ ). TCE exposure significantly increased MDA immunoreactivity in the ovarian tissue (Figure 2c) compared with the control group ( $p=0.002$ ). MDA immunoreactivity was significantly decreased in ovarian tissues in the TCE + vitamin D3 group compared with the control group (Figure 2d) ( $p=0.002$ ). Table 2 illustrates

the MDA immunoreactivity histoscores of every group.

## DISCUSSION

In mammals, synthetic and natural chemicals could have an impact on the female reproductive system and could bring about a number of complications which comprise anovulation, menstrual abnormali-

**TABLE 2:** MDA immunoreactivity histoscore of groups.

Groups	MDA immunoreactivity
Control	0.85 (0.60-1.20)
Vitamin D3	0.60 (0.45-1.20)
TCE	2.70 (1.80-2.70) <sup>a</sup>
TCE + Vitamin D3	0.85 (0.60-1.20) <sup>b</sup>

MDA: Malondialdehyde

TCE: Trichloroethylene

<sup>a</sup> Values are given as median (minimum-maximum).<sup>a</sup> Compared with the control group ( $p < 0.05$ )<sup>b</sup> Compared with TCE group ( $p < 0.05$ ).

ties, developmental defects of the reproductive tract, infertility and miscarriage.<sup>19</sup> TCE is among the most encountered environmental chemicals that have recently been described as toxic for the reproductive system. The primary source of exposure to TCE in humans and animals is the inhalation or ingestion of polluted water.

This study revealed that there was a substantial rise in the immunoreactivity of MDA, which displayed higher oxidative stress in ovarian tissues due to TCE exposure. Oxidative stress is brought about by a disproportion between the antioxidant defense system and free radicals, resulting in inactivation of many enzymes and lipid peroxidation. MDA is typically referred to as the final product of lipid peroxidation, and elevated MDA levels reflect the status of oxidative stress.<sup>20</sup> In ovarian tissues, increased oxidative stress could cause ovarian failure by inducing apoptosis and inhibiting cytoplasmic as well as nuclear maturation in oocytes.<sup>21</sup> Consistently with this study, Wu and Berger demonstrated increased oxidative modified proteins (protein carbonyls) by immunohistochemical assessment in the rat ovaries exposed to TCE-including water for two weeks. Also, they showed the presence of protein carbonyls in ovarian tissues exposed to TCE from four to five days to the treatment interim of two weeks, particularly in the ovarian granulosa cells. They concluded that exposure to TCE might decrease the fertilization potential of the oocytes in all growth stages (late-stage, early or mid) by meiotic nuclear arrest, irrespective of the time of exposure.<sup>22</sup> Du Teaux and co-workers investigated the potential mechanisms of TCE toxicity in the male reproductive system. They observed oxi-

dized proteins around the head and mid part of sperm obtained from TCE-treated animals by means of immunochemical staining. They proposed that the reduction in the fertilizing capacity of TCE-exposed animals could be attributed to the oxidative damage.<sup>23</sup> Cummings et al. similarly studied the role of glutathione and CYP450 in the cytotoxicity and metabolism of TCE in rat kidneys. They reported that TCE toxicity on renal proximal and distal tubules was the result of oxidative damage by CYP450 and glutathione metabolism.<sup>24</sup> The findings of the present study also indicated that the toxic mechanism of TCE is related to oxidative stress concerning a substantial rise in immunoreactivity of MDA.

Anti-oxidant treatment could have favorable effects on the negative results of lethal chemical substances that cause organ damage. This study was able to prove that anti-oxidant properties of vitamin D3 inhibited the detrimental effects of TCE on ovarian tissues. When vitamin D3 was administered together with TCE, there was a decrease in the MDA immunoreactivity. Therefore, we proposed that vitamin D3 administration may preserve tissues from the destructive results of TCE exposure. In accordance, Lin et al. investigated in vitro and in vivo anti-oxidative mechanisms of vitamin D3 against oxidative stress that is zinc-induced. They revealed that zinc-induced lipid peroxidation was suppressed by vitamin D3 through termination of the lipid peroxidation chain reaction, upregulation of vitamin D3 up-regulated protein-1 (VDUP-1) as well as inhibition of auto-oxidation.<sup>25</sup> In an animal model of thioacetamide-induced hepatotoxicity, Kwon et al. specified the critical role of VDUP-1 by which vitamin D3 was up-regulated in oxidative stress.<sup>26</sup> Recently, Sahin et al. assessed the anti-oxidant outcome of 1,25 dihydroxyvitamin D3 against gastric destruction triggered by intragastric ethanol instillation in rats. They established that vitamin D3 reduced endogenous anti-oxidant effects of glutathione, infiltration of neutrophils, expression of nuclear factor kappa-B, and apoptosis in gastric mucosa which was rigorously damaged by lipid peroxidation.<sup>27</sup> Contrary to that, Tagliaferri et al. carried out a review concerning the anti-oxidant role of vitamin D and they noticed the controversial effects concerning the capacity of vitamin D3 in pre-

venting oxidative stress and the need for high-quality studies for testing the anti-oxidant outcomes of vitamin D treatment.<sup>28</sup> The findings of this study pointed out the anti-oxidant impact of vitamin D3 and suggested that vitamin D3 could be capable of reversing the toxic effects of TCE.

According to the current study, the exposure to TCE caused severe histological alterations such as degeneration of germinal epithelium, degeneration of ovarian follicles and reduced angiogenesis in corpus luteum. However, administration of vitamin D3 was able to improve these histological alterations and limited the negative impact of TCE on ovarian tissues. Similarly, Hayderi et al. confirmed the ameliorative outcomes of vitamin E on TCE-induced nephrotoxicity in rats. They found substantial histological harm, which consisted of cellular swelling, tubular epithelial necrosis and nuclear dilatation. In addition, they observed the fact that vitamin E treatment significantly improved histopathological injury as compared to non-treated rats.<sup>29</sup> Recent studies have also demonstrated that TCE harmfully affects ovarian functions and, thus, fertility. Xu et al. showed an impairment in the fertilization capacity of sperms in TCE-exposed mice.<sup>30</sup> Berger and Horner also demonstrated a reduction in the fertilization capacity of oocytes after TCE exposure. This reduction was attributed to the decreased capacity for binding sperm plasma membrane proteins.<sup>31</sup> Several studies in the literature have demonstrated that related antioxidants like beta-carotene, vitamin E, and vitamin C protect ovarian tissues from oxidative stress.<sup>32,33</sup>

The major limitation of the present study was the administration of a single dose of vitamin D3. That is, various dosages and/or metabolites of vitamin D3 could have discrepant outcomes. In addition, there was lack of data related with different lengths of treatment periods and administration routes. Another

limitation was the inability to carry out biochemical and hormonal analyses and retrieve related data.

## CONCLUSION

To conclude, this study provided evidence that exposure to TCE caused histological ovarian injury by means of oxidative stress. Besides, the substantial improvements in oxidative stress parameters as observed by histopathological and immunohistochemical methods indicate that treatment with vitamin D3 could prevent the TCE related toxicity in ovarian tissues. The beneficial effects of vitamin D3 might be attributed to its anti-oxidant properties.

### Acknowledgments

*No particular funding was received by any author from any funding agency in the commercial, non-profit or public sectors.*

### Source of Finance

*During this study, no financial or spiritual support was received neither from any pharmaceutical company that has a direct connection with the research subject, nor from a company that provides or produces medical instruments and materials which may negatively affect the evaluation process of this study.*

### Conflict of Interest

*No conflicts of interest between the authors and / or family members of the scientific and medical committee members or members of the potential conflicts of interest, counseling, expertise, working conditions, share holding and similar situations in any firm.*

### Authorship Contributions

**Idea/Concept:** Helin Bağcı, Mehmet Şimşek; **Design:** Helin Bağcı, Tuncay Kuloğlu; **Control/Supervision:** Ebru Çelik Kavak, Mehmet Şimşek; **Data Collection and/or Processing:** Helin Bağcı; **Analysis and/or Interpretation:** Helin Bağcı, Rauf Melekoğlu; **Literature Review:** Helin Bağcı, Rauf Melekoğlu; **Writing the Article:** Helin Bağcı, Rauf Melekoğlu; **Critical Review:** Ebru Çelik Kavak, Tuncay Kuloğlu; **References and Fundings:** Helin Bağcı.

## REFERENCES

- Bhattacharya P, Keating AF. Impact of environmental exposures on ovarian function and role of xenobiotic metabolism during ovotoxicity. *Toxicol Appl Pharmacol.* 2012;261(3):227-35. [Crossref] [PubMed] [PMC]
- Gilbert KM, Bai S, Barnette D, Blossom SJ. Exposure cessation during adulthood did not prevent immunotoxicity caused by developmental exposure to low-level trichloroethylene in drinking water. *Toxicol Sci.* 2017;157(2):429-37. [Crossref] [PubMed] [PMC]
- Shukla AK, Upadhyay SN, Dubey SK. Current trends in trichloroethylene biodegradation: a review. *Crit Rev Biotechnol.* 2014;34(2):101-14. [Crossref] [PubMed]
- Chiu WA, Jinot J, Scott CS, Makris SL, Cooper GS, Dzubow RC, et al. Human health effects of trichloroethylene: key findings and scientific issues. *Environ Health Perspect.* 2013;121(3):303-11. [Crossref] [PubMed] [PMC]
- Lamb JC, Hentz KL. Toxicological review of male reproductive effects and trichloroethylene exposure: assessing the relevance to human male reproductive health. *Reprod Toxicol.* 2006;22(4):557-63. [Crossref] [PubMed]
- Stermer AR, Klein D, Wilson SK, Dalajamts C, Bai CY, Hall SJ, et al. Differential toxicity of water versus gavage exposure to trichloroethylene in rats. *Environ Toxicol Pharmacol.* 2019;68:1-3. [Crossref] [PubMed] [PMC]
- Wu KL, Berger T. Ovarian gene expression is stable after exposure to trichloroethylene. *Toxicol Lett.* 2008;177(1):59-65. [Crossref] [PubMed] [PMC]
- Luo YS, Furuya S, Soldatov VY, Kosyk O, Yoo HS, Fukushima H, et al. Metabolism and toxicity of trichloroethylene and tetrachloroethylene in cytochrome P450 2E1 knockout and humanized transgenic mice. *Toxicol Sci.* 2018;164(2):489-500. [Crossref] [PubMed] [PMC]
- Zhang F, Marty S, Budinsky R, Bartels M, Pottenger LH, Bus J, et al. Analytical methods impact estimates of trichloroethylene's glutathione conjugation and risk assessment. *Toxicol Lett.* 2018;296:82-94. [Crossref] [PubMed]
- Bhattacharya P, Keating AF. Ovarian metabolism of xenobiotics. *Exp Biol Med (Maywood).* 2011;236(7):765-71. [Crossref] [PubMed] [PMC]
- Cooper GS, Makris SL, Nietert PJ, Jinot J. Evidence of autoimmune-related effects of trichloroethylene exposure from studies in mice and humans. *Environ Health Perspect.* 2009;117(5):696-702. [Crossref] [PubMed] [PMC]
- Dusso AS, Brown AJ, Slatopolsky E. Vitamin D. *Am J Physiol Renal Physiol.* 2005;289(1):F8-28. [Crossref] [PubMed]
- Jones G. Expanding role for vitamin D in chronic kidney disease: importance of blood 25-OH-D levels and extra-renal 1 $\alpha$ -hydroxylase in the classical and nonclassical actions of 1 $\alpha$ ,25-dihydroxyvitamin D(3). *Semin Dial.* 2007;20(4):316-24. [Crossref] [PubMed]
- Hou YF, Gao SH, Wang P, Zhang HM, Liu LZ, Ye MX, et al. 1 $\alpha$ ,25(OH) $_2$ D $_3$  suppresses the migration of ovarian cancer SKOV-3 cells through the inhibition of epithelial-mesenchymal transition. *Int J Mol Sci.* 2016;17(8):1285. [Crossref] [PubMed] [PMC]
- Khairy EY, Attia MM. Protective effects of vitamin D on neurophysiologic alterations in brain aging: role of brain-derived neurotrophic factor (BDNF). *Nutr Neurosci.* 2019;1-10. [Crossref] [PubMed]
- Seif AA, Abdelwahed DM. Vitamin D ameliorates hepatic ischemic/reperfusion injury in rats. *J Physiol Biochem.* 2014;70(3):659-66. [Crossref] [PubMed]
- Khan S, Priyamvada S, Khan SA, Farooq N, Khan F, Yusufi ANK. Effect of trichloroethylene (TCE) toxicity on the enzymes of carbohydrate metabolism, brush border membrane and oxidative stress in kidney and other rat tissues. *Food Chem Toxicol.* 2009;47(7):1562-8. [Crossref] [PubMed]
- Gougeon A. Human ovarian follicular development: from activation of resting follicles to preovulatory maturation. *Ann Endocrinol (Paris).* 2010;71(3):132-43. [Crossref] [PubMed]
- Hombach-Klonisch S, Pocar P, Kietz S, Klonisch T. Molecular actions of polyhalogenated arylhydrocarbons (PAHs) in female reproduction. *Curr Med Chem.* 2005;12(5):599-616. [Crossref] [PubMed]
- Tsikas D. Assessment of lipid peroxidation by measuring malondialdehyde (MDA) and relatives in biological samples: analytical and biological challenges. *Anal Biochem.* 2017;524:13-30. [Crossref] [PubMed]
- Liang LF, Qi ST, Xian YX, Huang L, Sun XF, Wang WH. Protective effect of antioxidants on the pre-maturation aging of mouse oocytes. *Sci Rep.* 2017;7(1):1434. [Crossref] [PubMed] [PMC]
- Wu KL, Berger T. Trichloroethylene metabolism in the rat ovary reduces oocyte fertilizability. *Chem Biol Interact.* 2007;170(1):20-30. [Crossref] [PubMed] [PMC]
- DuTeaux SB, Berger T, Hess RA, Sartini BL, Miller MG. Male reproductive toxicity of trichloroethylene: sperm protein oxidation and decreased fertilizing ability. *Biol Reprod.* 2004;70(5):1518-26. [Crossref] [PubMed]
- Cummings BS, Parker JC, Lash LH. Role of cytochrome P450 and glutathione S-transferase alpha in the metabolism and cytotoxicity of trichloroethylene in rat kidney. *Biochem Pharmacol.* 2000;59(5):531-43. [Crossref] [PubMed]
- Lin AMY, Chen KB, Chao PL. Antioxidative effect of vitamin D3 on zinc-induced oxidative stress in CNS. *Ann N Y Acad Sci.* 2005;1053:319-29. [Crossref] [PubMed]
- Kwon HJ, Lim JH, Han JT, Lee SB, Yoon WK, Nam KH, et al. The role of vitamin D3 upregulated protein 1 in thioacetamide-induced mouse hepatotoxicity. *Toxicol Appl Pharmacol.* 2010;248(3):277-84. [Crossref] [PubMed]
- Sahin HH, Cumbul A, Uslu U, Yilmaz Z, Ercan F, Alican I. The effect of 1,25 dihydroxyvitamin D3 on HCl/Ethanol-induced gastric injury in rats. *Tissue Cell.* 2018;51:68-76. [Crossref] [PubMed]
- Tagliaferri S, Porri D, De Giuseppe R, Manuelli M, Alessio F, Cena H. The controversial role of vitamin D as an antioxidant: results from randomised controlled trials. *Nutr Res Rev.* 2019;32(1):99-105. [Crossref] [PubMed]
- Heydari M, Ahmadizadeh M, Ahmadi Angali K. Ameliorative effect of vitamin E on trichloroethylene-induced nephrotoxicity in rats. *J Nephropathol.* 2017;6(3):168-73. [Crossref] [PubMed] [PMC]
- Xu H, Tanphaichitr N, Forkert PG, Anupriwan A, Weerachatanukul W, Vincent R, et al. Exposure to trichloroethylene and its metabolites causes impairment of sperm fertilizing ability in mice. *Toxicol Sci.* 2004;82(2):590-7. [Crossref] [PubMed]
- Berger T, Horner CM. In vivo exposure of female rats to toxicants may affect oocyte quality. *Reprod Toxicol.* 2003;17(3):273-81. [Crossref] [PubMed]
- Aksak Karamese S, Toktay E, Unal D, Selli J, Karamese M, Malkoc I. The protective effects of beta-carotene against ischemia/reperfusion injury in rat ovarian tissue. *Acta Histochem.* 2015;117(8):790-7. [Crossref] [PubMed]
- Ismiyati A, Wiyasa IWA, Hidayati DYN. Protective effect of vitamins C and E on depot-medroxyprogesterone acetate-induced ovarian oxidative stress in vivo. *J Toxicol.* 2016;2016:3134105. [Crossref] [PubMed] [PMC]