

Vaginal Adenosis without DES exposure: A Case Report

Ayşe Kafkash, MD¹, Aycan Kayıkçıoğlu, MD², Abdullah Aydın, MD³, Ali Buhur, MD¹

An unusual case of vaginal adenosis in non-diethylstilbestrol (DES)-exposed patient is presented. Patient was admitted with the history of dyspareunia and excessive mucoid vaginal discharge. On speculum examination red, granular areas extending from anterior and posterior wall of the upper vagina and a transvers vaginal ridge were detected. Microscopic examination of the specimen taken from the lesion revealed mucinous type of vaginal adenosis. [Journal of Turgut Özal Medical Center 1996;3(4):356-358]

Key Word: Vaginal adenosis

DES etkisine maruz kalmamış vajinal adenozis : bir olgu sunumu

In utero DES etkisine maruz kalmamış nadir rastlanan bir vajinal adenozis olgusu sunulmaktadır. Hasta polikliniğimize dispareuni ve artmış mukoid vajinal akıntı öyküsü ile başvurdu. Yapılan spekülüm muayenesinde üst vajen ön ve arka duvarından kaynaklanan kırmızı granüler alan saptandı. Bu lezyondan alınan materyalin mikroskopik değerlendirmesinde müsinöz tip vajinal adenozis tanısı kondu. [Turgut Özal Tıp Merkezi Dergisi 1996;3(4):356-358]

Anahtar Kelime: Vajinal adenozis

Vaginal adenosis is characterized by the presence of glands in the lamina propria and/or replacement of the surface squamous epithelium of the vaginal wall by glandular epithelium (1,2). Vaginal adenosis was uncommonly detected until the first recognition of the vaginal wall clear-cell adenocarcinoma in DES-exposed adolescent in 1971 (3,4). The association between vaginal clear-cell adenocarcinoma and inutero DES-exposure has been reported by several authors (4-7). However, vaginal adenosis has also been observed in patients without DES-exposure (8). Histopathologic changes are identical in patients with and without DES-exposure (2,8).

Three types of epithelia characterize the vaginal adenosis: 1-Mucinous (resembles the normal endocervical epithelium), 2-Tuboendometrial (resembles the epithelium of fallopian tube or uterine fundus), 3-Embryonic (tiny glands lined by embryonic type columnar epithelium). Most of the patients with vaginal adenosis have been reported to be asymptomatic and have been diagnosed incidentally during routine gynecological examination. Leukorrhoea was the most prominent sign in the symptomatic patients (2). In fact vaginal adenosis is a benign lesion, but it has been reported to be the precursor of vaginal clear-cell adenocarcinoma in a considerable number of

¹ İnönü University Faculty of Medicine Department of Obstetrics and Gynecology, Malatya

² İnönü University Faculty of Medicine Department of Plastic and Reconstructive Surgery, Malatya

³ İnönü University Faculty of Medicine Department of Pathology, Malatya

patients. Although the exact mechanism of transition from adenosis to the adenocarcinoma is not clear yet, patients with vaginal adenosis must be followed by periodic cytologic and colposcopic examinations.

A 28-year old, nulligravid woman with vaginal adenosis without DES-exposure is presented here.

CASE REPORT

A 28-year old, nulligravid woman was admitted to the outpatient clinics of Obstetrics and Gynecology Department with a history of dyspareunia and excessive mucoid vaginal discharge for 7 months. On the speculum examination; diffuse red warty protuberances were observed on the anterior and posterior wall of the upper vagina. A transvers vaginal ridge was palpated during the bimanual pelvic examination. Two punch biopsies were taken from anterior and posterior wall lesions. Histopathologic examination of the biopsy material revealed endocervical type epithelium lined glands throughout the lamina propria. The overlying squamous epithelium of the vagina was normal. Congestion in some of the small vessels were observed in the lamina propria (Figure 1 and Figure 2). Lesions was diagnosed as mucinous type vaginal adenosis. Her mother denied any steroidal or nonsteroidal medication during her pregnancy. Transvers vaginal ridge was released with bilateral Z-plasties and hypoplastic cervix was exposed following the Z-plasties. A vaginal stent was applied for 10 days. She was advised to have periodic cytologic and colposcopic examination to rule out clear-cell adenocarcinoma development.

DISCUSSION

The association between vaginal adenosis and DES-exposure has received attention to this vaginal pathology since 1971. Plaut and Dreyfuss first recognized the vaginal adenosis prior to the DES treatment in 1940 (9). Twenty-five years later, Sandberg et al described only 27 new cases in their review article (10). Robboy et al have reported 41 additional cases with vaginal adenosis without DES-exposure during the 6-year period between 1976-1982 (2). Vaginal adenosis might occur more common than recognized. Since most of the patients have been asymptomatic, adenosis is found as an

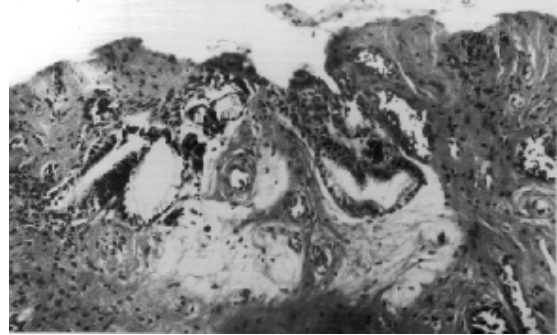


Figure 1. Squamous vaginal mucosa is normal. Beneath the surface epithelium there is an endocervical type epithelium lined gland. Also there are some congested small vessels.

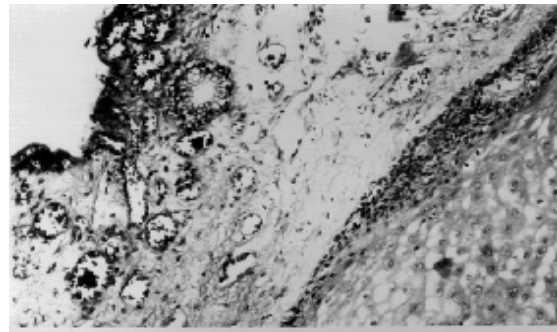


Figure 2. Deep seated glands are lined by mucinous type epithelium in the lamina propria.

incidental finding during the physical examination. Vaginal pruritis, discomfort, clear or mucoid discharge, spotting after intercourse are the most prominent signs in the symptomatic patients (2,11). Vaginal histopathological changes were reported to be identical in patients with or without DES-exposure by Robboy (2). In the present case the patient had a history of mucoid discharge but dyspareunia due to vaginal transvers ridge was the prominent complain. In almost all cases with vaginal adenosis without DES-exposure, probably due to the easy recognition of mucinous epithelium, the glands were reported to be exclusively composed of mucinous columnar cells. Even in the DES-exposed patients tuboendometrial cell-lined glands were reported infrequently (3,11). In the present case microscopic features revealed mucinous type vaginal adenosis and malignant changes were not detected. The complaint of excessive mucoid discharge was due to mucus secretion of this glands in the patient.

In conclusion; vaginal adenosis should be kept in mind in young patients even without DES-

exposure. Sexually active young patients with vaginal adenosis can be treated on a wait-and-see basis with periodic cytologic and colposcopic examinations.

REFERENCES

1. Disaia PJ, Creasman WT. Preinvasive disease of the vagina and vulva. In: Clinical Gynecologic Oncology. Disaia PJ, Creasman WT, eds. Missouri: Mosby 1993:37-57.
2. Robboy SJ, Hill EC, Sandberg EC, et al. Vaginal adenosis in women born prior to the diethylstilbestrol era. Hum Pathol 1986;17:488-92.
3. Herbst AL, Scully RE. Adenocarcinoma of the vagina in adolescence. Cancer 1970;257:745-57.
4. Herbst AL, Ulfelder H, Poskanzer DC. Adenocarcinoma of the vagina: Association of maternal stilbestrol therapy with tumour appearance in young women. N Engl J Med 1971; 284:848.
5. Noller KL, Fish DR. Diethylstilbestrol usage: its interesting past, important present, and questionable future. Med Clin North Am 1974;58:793.
6. Herbst AL, Kurman RJ, Scully RE. Vaginal and cervical abnormalities after exposure to stilbestrol in utero. Obstet Gynecol 1972;40:287.
7. Robboy SJ, Welch WR, Young RH, et al. Pathologic findings in young women enrolled in national cooperative diethylstilbestrol adenosis (DESAD) project. Obstet Gynecol 1979;53:309.
8. Scurry J, Planner R, Grant P. Unusual variants of vaginal adenosis: A challenge for diagnosis and treatment. Gynecologic Oncology 1991; 41:172-7.
9. Plaut A, Dreyfuss ML. Adenosis of vagina and its relation to primary adenocarcinoma of vagina. Soc Gynecol Oncol 1940;71:756.
10. Sandberg EC, Danielson RW, Cauwet RW, et al. Adenosis vaginae. Am J Obstet Gynecol 1965;93:209.
11. Sandberg EC, Danielson RW, Prince E. Benign vaginal adenosis. Obstet Gynecol 1967;30:93.

Correspondence address: Ayşe Kafkaslı, MD
İnönü University Faculty of Medicine
Department of Obstetrics and Gynecology
44300 MALATYA