

Hepatotoxic and Nephrotoxic Effects of Acetaminophen in New-Born and Adult Rats Comperatively

Mukaddes Eşrefoğlu, M D, PhD*, Mukadder Ayşe Selimoğlu, M D**, M. Akif Çiftçioğlu, M D, PhD***, Akçahan Gepdiremen, M D, PhD****, Mehmet Parlak, M D*****

This study was planned to demonstrate acetaminophen hepatotoxicity and nephrotoxicity in new-born and adult rats comperatively. Ten newborn and ten adult male Wistar albino rats were used and in each group four rats were administered 300mg/kg and four 500mg/kg acetaminophen intraperitoneally. Spontaneous death was not observed; after 8 hours the animals were killed by decapitation. Liver and kidney sections were stained with hematoxylin and eosin. In newborn rats at 300mg/kg dose small number of necrotic cells were observed and all the animals at 500mg/kg dose developed mild centrilobular hepatic necrosis, whereas in adult rats at 300mg/kg dose moderate and at 500mg/kg dose severe centrilobular hepatic necrosis was observed.

The severity of the renal injury was not different at 300mg/kg and 500mg/kg acetaminophen group in adult and new-born rats. This toxicity was not dose-dependent and age-dependent. In all groups, there was severe acute tubular necrosis.

Key words: Acetaminophen, hepatotoxicity, nephrotoxicity, rat, newborn

Asetaminofen hepatotoksisitesinin ve nefrotoksisitesinin yenidoğan ve erişkin sıçanlarda karşılaştırmalı olarak incelenmesi

Bu çalışma asetaminofen hepatotoksisitesini ve nefrotoksisitesini yenidoğan ve erişkin sıçanlarda karşılaştırmalı olarak incelemek amacı ile planlandı. Çalışmada 10 erişkin ve 10 yenidoğan Wistar albino türü sıçan kullanıldı, her grupta hayvanların dördüne 300mg/kg ve dördüne de 500mg/kg asetaminofen intraperitoneal olarak uygulandı. Spontan ölüm gözlenmedi, 8 saat sonra hayvanlar öldürüldüler. Karaciğer ve böbrek kesitleri hematoksilen-eozinle boyandı. 300mg/kg dozda yeni-doğan sıçanların karaciğerlerinde az sayıda nekrotik hücre izlenirken; 500mg/kg dozda bütün yeni-doğanlarda hafif sentrilobüler hepatik nekroz gözlemlendi. Erişkin sıçanlarda ise 300mg/kg dozda orta derecede, 500mg/kg dozda ciddi hepatik nekroz izlendi.

300 mg/kg ve 500 mg/kg asetaminofen uygulanan yeni-doğan ve erişkin sıçanlarda böbrek değişiklikleri birbirinden farklı değildi. Böbrek toksisitesi doza ve yaşa bağlı değildi. Bütün gruplarda ciddi derecede akut tubuler nekroz izlendi.

Anahtar kelimeler: Asetaminofen, hepatotoksisite, nefrotoksisite, sıçan, yeni-doğan

* Atatürk University, Medical Faculty, Department of Histology and Embriology,

** Department of Pediatrics

*** Department of Pathology

**** Department of Pharmacology

***** Department of Clinical Microbiology and Infectious Diseases

The liver is central to the metabolic disposition of virtually all drugs and foreign substances(1). Like the liver, the kidney also contains active enzyme systems capable of metabolically activating drugs and other chemicals. In addition, the kidney is positioned in a primary site of exposure, since it receives a large blood supply and contains specialized transport processes for concentrating and secreting drugs(2).

Acetaminophen(APAP) is an analgesic and antipyretic which is considered safe when taken appropriately(3,4). However, following overdose, this causes severe hepatic necrosis and acute tubular necrosis(2). Damage to the liver and kidney caused by APAP is thought to be a result of the conversion of a fraction of the dose to chemically reactive metabolites which can covalently bind to cellular macromolecules(2,5).

Clinical experience suggests that if an adult consumes more than 7.5-15 g.(150 to 200mg/kg) of APAP as a single dose or a child ingests 150mg/kg of body weight hepatotoxicity may occur, doses of 20 to 25 g. or more are potentially fatal(6,7,8). It is generally accepted that children are less susceptible to APAP than adults(4,7,9).

In the present study, we have investigated the APAP toxicity in the liver and kidney comparatively at 2-week and 6-month old rats histopathologically.

MATERIALS AND METHODS

Ten 2-week-old and ten 6-month-old male Wistar albino rats were used in this study. Purified acetaminophen was obtained from Saba Drug Company. From each group four rats received 300mg/kg and four, 500 mg/kg APAP intraperitoneally in saline in a volume of 10ml/kg. These doses were chosen on the basis of previous experience to be a threshold toxic dose and an LD50 dose, respectively, in young adults(10). In each group, two control animals were injected with a equal volume of saline. Two-week-old rats were on breast feeding and they stayed with their mothers until the end of the study. Clinical observation was performed until the end of the experience. After 8 hours the animals

were killed by decapitation. Livers and kidneys were removed and placed in 10% buffered formal saline, then embedded in paraffin wax. Sections(5µm) were stained with hematoxylin and eosin. Hepatic and renal sections were examined for the morphologic changes and the pictures were taken with Olympus BH-2 photo microscope

RESULTS

The criteria used to assess the APAP toxicity in the new-born and adult rats were based on three lines of evidence: lethality data and histopathological evidence of liver and kidney injury.

At the 300mg/kg and 500 mg/kg doses, all adult and new-born rats survived for 8 hours. But at 500mg/kg dose, adult rats were near death(moribund and shallow respiration were recorded). But at the 300mg/kg and 500 mg/kg doses, new-borns were active and no physical difference was observed.

The histopathological changes in all groups are as follows:

Liver: New-born at 300mg/kg dose: The morphologic changes common to this group were mild cellular swelling, sinusoidal congestion and in a few area, hepatocytic vacuolation. There was small number of necrotic hepatocytes(Figure 1).

New-born at 500mg/kg dose: In this group, all the animals developed mild centrilobular hepatic necrosis. The other histopathological changes were hepatocytic vacuolation, sinusoidal congestion and mild hepatocytic fatty change(Figure 2).

Adult at 300mg/kg dose: In the liver sections, some of the lobules were morphologically deranged. Moderate centrilobular hepatic necrosis was a feature of this group. The other alterations included sinusoidal congestion and loss of sinusoidal cells(Figure 3).

Adult at 500mg/kg dose: Most of the lobules were morphologically deranged. Severe centrilobular hepatic necrosis was observed. Sinusoidal congestion and loss of sinusoidal cells




Figure 1: The liver of newborn rat received 300mg/kg of APAP. Small numbers of necrotic cells is observed (arrow). Hematoxylin-eosinX100.




Figure 2: The liver of newborn rat received 500mg/kg of APAP. Mild hepatic necrosis is observed (arrow). Hematoxylin-eosinX100.

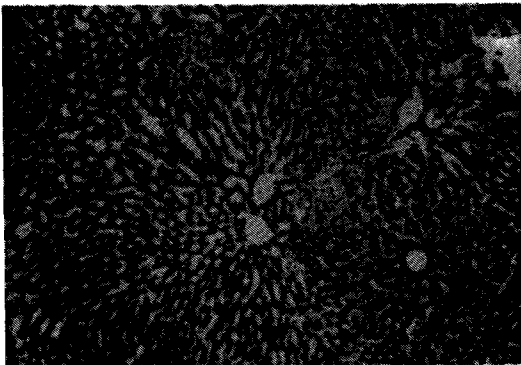


Figure 3: The liver of adult rat received 300mg/kg of APAP. Note the moderate hepatic necrosis. Sinusoidal dilatation and congestion are observed (arrow). Hematoxylin-eosinX100.

were the other histopathological changes(Figure 4).

Kidney: The severity of the renal injury was not different at 300mg/kg and 500mg/kg APAP group in adult and new-born rats. This toxicity was not dose-dependent and age-dependent. In all groups, there was severe acute tubular necrosis in the inner zone of cortex and outer zone of the medulla(Figure 5,6). In the inner zone of the medulla severe tubular edema was observed.

DISCUSSION

It is generally accepted that children are less susceptible to acetaminophen toxicity than are adults(4,7,9). In our study, at the 300mg/kg and 500mg/kg doses, all adult and new-born rats survived until decapitation. In 500mg/kg adult rats, though there was no death, moribund and shallow respiration were observed. But new-born rats were highly active and there was no sign of death clinically. Our observation is consistent with the fact that, the LD50 dose for APAP in neonatal rats is slightly higher than that observed in adult animals(11).

The histopathological criteria of the hepatic injury of APAP is centrilobular hepatic necrosis, centrilobular hepatocytic atrophy, hepatocytic vacuolation, hepatocytic fatty change, loss of sinusoidal cells, sinusoidal congestion, focal peliosis and inflammatory infiltration (8, 10, 11, 12, 13, 14). In the present study, centrilobular hepatic necrosis was a common feature found in adult rats received 300mg/kg and 500mg/kg APAP. In 500mg/kg APAP group, the severity of necrosis was higher than that of the 300mg/kg group. The other alterations including derangement of the lobules, sinusoidal congestion and loss of sinusoidal cells were more pronounced in rats receiving higher dose of APAP. Adamson et.al.found that, morphologic alterations produced by APAP were more significant in animals receiving higher doses(10). APAP is metabolized by the liver primarily to sulfate and glucuronide conjugates. The hepatic mixed-function oxidase system metabolizes a small percentage of the dose to a toxic intermediate. This reactive species is normally neutralized through conjugation with reduced

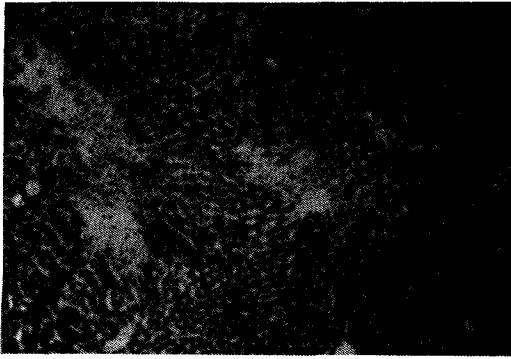


Figure 4: The liver of adult rat received 500mg/kg of APAP. Severe hepatic necrosis is observed (arrow). Hematoxylin-eosinX100.

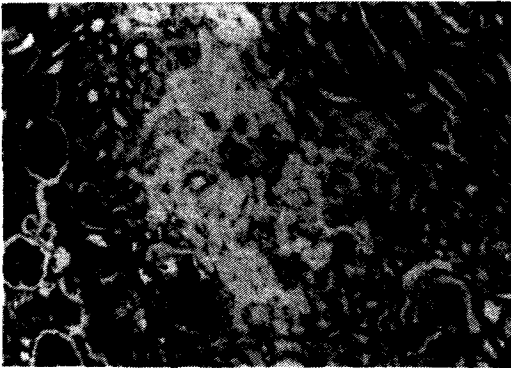


Figure 5: The kidney of newborn rat received 300mg/kg of APAP. Note the tubular necrosis in the inner zone of the cortex and outer zone of the medulla. Hematoxylin-eosinX100.




Figure 6: The kidney of adult rat received 500mg/kg of APAP. There is tubular necrosis in the inner zone of the cortex and outer zone of the medulla. Hematoxylin-eosinX100.

glutathione, facilitated by glutathione-S-transferase. Following overdose, sulfation and glucuronidation become capacity-limited contributing to increased formation of the reactive metabolite. Subsequently, glutathione-S-transferase is depleted, and reactive metabolite then covalently bind to cellular macromolecules initiating cell death(1,3). Thus, the extend of the hepatic damage produced by APAP is dose-dependent.

In our study the range of necrosis and the other morphologic alterations were lower in newborn rats compared to adults. Thus, our study indicates that 2-week-old rats are remarkably resistant to the hepatotoxic effects of high doses of APAP when compared with older animals. Accidental ingestion of an overdose of APAP in children has not frequently been reported to produce hepatotoxic reactions, in fact, there is only a few case reports in the literature(9,15). This rarity is in contrast to the more frequent ingestion of overdoses of APAP in the adolescent age group where several reports of hepatotoxic reactions have appeared(12,16). Beierschmitt et.al(3) suggested that 75% of 3-month-old mice, but only 14-29% of 1-1.5 and 2-month old mice had centrilobular necrosis after a toxic dose of APAP. In all of these studies, age-related differences in APAP toxicity have been observed.

There are some theories about the mechanism why postnatal animals have less susceptibility to APAP toxicity. Young animals have higher levels of APAP covalently bound to hepatic macromolecules and excrete higher amounts of mercapturic acid conjugate compared to adult animals. These data suggests that young rats are able to metabolically activate a low dose of APAP compared to the adult animals. So the lower susceptibility of neonates appears to be due to a relative inability of the young animals to metabolically activate the drug(11,17). For many drug substrates both human and rodent neonates have poorly developed drug metabolizing systems, the activity of which increases with maturation. Hence, the young may be less affected by agents requiring metabolic activation, such as APAP(3).

Adamson et. al(10) suggested that lack of sensitivity to APAP toxicity in 2-week-old mice

must be associated with toxic events initiated by NAPQI (N-acetyl- p-benzo-quinone-imine, a reactive metabolite of APAP) formation that ultimately result in irreversible cell damage. It is likely that these toxic processes are quenched by superior defense mechanism in the postnatal liver cells. It has been shown that the activities of hepatoprotective enzymes, glutathione peroxidase and glutathione reductase were markedly higher in liver of 2-week-old mice than in adults. Therefore the higher level of these hepatoprotective enzymes would protect the liver from oxidative stress induced by APAP.

Renal effect of APAP is minor. Renal failure may uncommonly occur within major overdose of APAP(18). The greater the ingested dose, the greater the degree of hepatic necrosis and the higher the probability of acute renal failure. In addition to characteristic and sometimes fatal hepatic necrosis which occurs in man following massive APAP ingestion, a significant proportion of individuals also develop acute renal failure This development occurs most commonly in patients with extensive liver damage, but moderate to severe renal impairment may also occur in patients with little evidence of hepatic injury(19). Fisher et. al.(5) showed that concentrations of APAP and certain of its conjugates reach high levels in plasma, liver and kidney after a toxic dose. The renal lesion of APAP is acute tubular necrosis. The other described renal alterations include tubular edema, dilatation and degeneration of tubular epithelium. Recent studies have confirmed that APAP is concentrated in the outer renal medulla (2,16,20). Joshi et. al.(16) found that cortical binding of APAP is significantly less than medullary binding even at the highest concentration of APAP. We observed severe tubular necrosis in the inner zone of the cortex and outer zone of the medulla tubular edema in the inner zone of the medulla in both new-born and adult rats and. McMurtry et al(19) observed severe tubular necrosis in the combined areas of the renal cortex and subcortical zone of medulla in the kidney of Fisher rats.

For we observed severe nephrotoxicity in both new-born and adult, but high in adult but low hepatotoxicity in new-born, we suggest that the nephrotoxic effect of APAP is more severe than its hepatotoxic effect. But previous studies noted

that, renal changes produced by APAP occur after lethal doses and damage is not apparently a factor in APAP lethality since renal tubular necrosis are not observed occasionally(2,11). Green et. al.(11) recorded that APAP induced nephrotoxicity has only been observed in the Fisher rats. Mitchell et. al.(2) suggested that in animals that have high concentrations of microsomal cytochrome P-450 in their kidneys, such as male Fisher rats and certain strains of mice, acute tubular necrosis develops after the administration of single, non lethal doses of APAP. It is observed that UDP-glucuronosyl transferase deficient Gunn rats were more susceptible to APAP toxicity than Wistar rats(21). However, Trumper(22) observed renal damage both in the presence or absence of hepatic damage in male Wistar rats. This result is consistent with ours. It is shown that p-aminophenol causes necrosis of tubules in Wistar rats and its nephrotoxicity may due to glutathione-dependent bioactivation reaction(23). Enhanced susceptibility of some species of rats to APAP toxicity is due to decreased glucuronidation resulting in enhanced bioactivation rather than appreciated genetic differences(21). In addition, both age and strain-related differences in APAP nephrotoxicity could be related to differences in the relative quantity of p-aminophenol generated from APAP by rat kidneys(20). Tarloff et al(24) recorded that APAP induced nephrotoxicity is age dependent in male Sprague-Dawley rats. But we did not observe an age-dependent difference in APAP nephrotoxicity, because there was severe nephrotoxicity in both new-born and adult Wistar Albino rats.

We concluded that newborn rats had low susceptibility to APAP hepatotoxicity compared to adults, but nephrotoxicity rates of all groups were similar. Absence of biochemical evidence of renal damage in spite of histopathological findings suggested that the renal damage after toxic doses of APAP is not as rare as known. Since death due to renal failure after APAP exposure is an uncommon event, we speculated that this renal damage probably is reversible. To evaluate these effects of APAP, further investigations on different species with long-term follow-up are required.

REFERENCES

1. Lee WM: Drug-induced hepatotoxicity. *Aliment Pharmacol Ther* 1993;7(5):477-485.
2. Mitchell JR, Mc Murtry RJ, Statham CN, Nelson SD: Molecular basis for several drug-induced nephropathies. *Am J Med* 1977;62:518-525.
3. Beierschmitt WP, Brady JT, Bartolone JB, Wyand DS, Khairallah EA, Cohen SD: Selective protein arylation and the age dependency of acetaminophen hepatotoxicity in mice. *Toxicol Appl Pharmacol* 1989;98:517-529.
4. Green MD, Fischer LJ: Age and sex-related differences in acetaminophen metabolism in the rat. *Life Sciences* 1981;29:2421-2428.
5. Fisher LJ, Green MD, Harman AW: Levels of acetaminophen and its metabolites in mouse tissues after a toxic dose. *J Pharmacol Exp Ther* 1981;219:281-286.
6. Gilman AG, Goodman LS, Rall TW: *The Pharmacological Basis of Therapeutics*: New-York :Mc Millian, 1993:694.
7. Mariscalco MM: Acetaminophen overdose. In: Oski FA, De Angelis CD, Feigin RD, McMillian JA, Warshaw JB, eds. *Pediatrics*: Philadelphia: JB Lippincott, 1994:838-840.
8. Zimmerman HJ, Ishak KG: Hepatic injury due to drugs and toxins. In: Mc Sween RNM, Anthony PP, Schever RK, eds. *Pathology of the Liver*: Edinburgh-London Churchill-Livingstone, 1987:559.
9. Peterson RG, Rumack BH: Age as a variable in acetaminophen overdose. *Arch Intern Med* 1981;141: 390-393.
10. Adamson GM, Papadimitriou, Harman AW: Postnatal mice have low susceptibility to paracetamol toxicity. *Pediatric Research* 1991; 29(5): 496-499.
11. Green MD, Shires TK, Fisher LJ: Hepatotoxicity of acetaminophen in neonatal and young rats. I: Age related changes in susceptibility. *Toxicol Appl Pharmacol* 1984;74:116-124.
12. O'Dell JR, Zetteman RK, Burnett DA: Centrilobular hepatic fibrosis following acetaminophen induced hepatic necrosis in an alcoholic. *JAMA* 1986;255(19):2636-1637.
13. Schever PJ: *Liver Biopsy Interpretation*. London, Bailliere Tindall, 1989;75.
14. Tolunay Ş: Aspirin ve parasetamolü 26 hafta süreyle hergün verdiğimiz sıçanların karaciğerinde oluşan histopatolojik değişiklikler. *Uludağ Üniversitesi Tıp Fakültesi Dergisi* 1990;1:115-124.
15. Doudidar SM, Al-Khalil I, Habersang RW: Severe hepatotoxicity, acute renal failure, and pancytopenia in a young child after repeated acetaminophen overdosing. *Clinical Pediatrics* 1994;1:42-45.
16. Joshi S, Zenser TV, Mattammal MB, Herman CA, Davis BB: Kidney metabolism of acetaminophen and phenacetin. *J Lab Clin Med* 1978;92(6):924-931.
17. Green MD, Fisher LJ(1981) Hepatotoxicity of acetaminophen in neonatal and young rats. II: Metabolic aspects. *Toxicol Appl Pharmacol* 74, 125-133.
18. Plotz PH, Kimberly RP(1981) Acute effects of aspirin and acetaminophen on renal function. *Arch Intern Med* 141, 343-348.
19. McMurtry RJ, Snodgrass WR, Mitchell JR(1978) Renal necrosis, glutathione depletion and covalent binding after acetaminophen. *Toxicol Appl Pharmacol* 46, 87-100.
20. Hart SG, Beierschmitt WP, Wyand DS, Khairallah EA, Cohen SD(1994) Acetaminophen nephrotoxicity in CD-1 mice. I: Evidence of a role for in situ activation in selective covalent binding and toxicity. *Toxicol Appl Pharmacol* 126(2), 267-275.
21. De Mararis SM, Chow SY, Wells PG(1992) Biotransformation and toxicity of acetaminophen in congenic RHA rats with or without hereditary deficiency in bilirubin. *Toxicol Appl Pharmacol* 117(1),81-87.
22. Trumper L, Girardi G, Elias MM(1992) Acetaminophen nephrotoxicity in male Wistar rats. *Toxicol Appl Pharmacol* 66(2), 107-111.
23. Klos C, Koob M, Kramer C, Dekat W(1992): P-aminophenol nephrotoxicity biosynthesis of toxic glutathione conjugates. *Toxicol Appl Pharmacol* 115(1), 98-106.
24. Terloff JB, Goldstern RS, Sozio RS, Hook JB(1991) Hepatic end renal conjugation enzyme activities in young, adult, middle-aged and senescent male Sprague Dawley rats. *Proc Soc Exp Biol Med* 197(3), 297-303.

Address for correspondence:

Mukaddes Eşrefoğlu
Atatürk Üniversitesi Tıp Fakültesi
Histoloji ve Embriyoloji ABD, 25240
Erzurum
Tel: 0 442 2331122/2024