



## The Role of Radiotherapy in Gliomatosis Cerebri: Two Case Reports

Öztun Temelli, Aysun Fatma Eraslan, Bahaddin Yaprak, Kemal Ekici

Inonu University, Faculty of Medicine, Department of Radiation Oncology, Malatya, Turkey

### Abstract

Gliomatosis cerebri is a rare diffuse involvement of the central nervous system by a malignant glioma that permeates the brain extensively without destroying the neural architecture. It involves more than two of the lobes. Oligodendroglial component can be predictive for a better prognosis. This is a report of two patients: a 33-year-old female patient and a 58-year-old male patient. A stereotactic biopsy was performed for our first patient. She was diagnosed with grade 2 astrocytoma. The second case was a grade 3 patient who was diagnosed with tumour infiltration in line with gliomatosis cerebri. Both cases underwent external beam radiotherapy at 44 Gy and 50 Gy, respectively, with a helical tomotherapy device. The patients tolerated the cure quite well and no acute complications (except for grade 1 skin reactions) were observed during the therapy. Radiotherapy volume and treatment dose are still controversial in the treatment of gliomatosis cerebri. Partial or whole brain radiotherapy can be applied.

**Key Words:** Gliomatosis Cerebri; Radiotherapy; Tomotherapy.

### Gliomatosis Serebride Radyoterapinin Yeri: İki Olgu Deneyimi

### Özet

Gliomatosis serebri, oldukça nadir görülen, beyinde en az iki lobu tutan, nöral yapıların korunduğu, diffüz neoplastik glial hücre proliferasyonudur. Oligodendroglial komponent varlığı prognoz açısından daha iyidir. Olgularımız 33 yaşında bayan ve 58 yaşında erkek hastadır. Birinci olgumuzda stereotaktik biyopsi yapılmış. Grade 2, astrositom olarak değerlendirilmiş. İkinci olgumuz ise biyopsi sonucu Grade 3, Gliomatosis serebri ile uyumlu tümör infiltrasyonu olarak değerlendirilmiş. Hastalarımıza Helikal Tomoterapi cihazında sırasıyla 44 Gy ve 50 Gy eksternal radyoterapi uygulandı. Hastalar tedaviyi iyi tolere etti ve tedavi süresince grade 1 cilt reaksiyonu dışında akut komplikasyon gözlenmedi. Gliomatosis serebride radyoterapi volümü, tedavi dozu tartışmalıdır. Tüm beyin veya parsiyel radyoterapi uygulanabilmektedir.

**Anahtar Kelimeler:** Gliomatosis Serebri; Radyoterapi; Tomoterapi.

## INTRODUCTION

Gliomatosis Cerebri (GC) is a rare diffuse neoplastic glial cell proliferation that involves at least two lobes of the brain while keeping neural structures undamaged. It was first described by Nevin in 1938. It is categorised as a neuroepithelial tumour by the World Health Organization (WHO) (1, 2).

The optimal treatment for GC is not yet clear. Due to diffuse involvement, surgical intervention is limited to biopsy in GC. Radiotherapy and chemotherapy are among the preferred treatment modalities. Many studies have shown that radiotherapy can at least stop GC's progress and sometimes cure the disease. However the effect of radiotherapy on the survival rate is unknown. Here, we would like to share the cases of two patients with GC, a disease with a very low incidence rate.

## CASE REPORT

**Case 1:** A thirty-three-year-old female patient consulted to a doctor with headache and weakness about 7 months ago. The cranial magnetic resonance (MR) imaging showed diffuse infiltrative involvement in the right frontal, temporal, parietal regions as well as in the

left frontal region (Figure 1). The patient underwent stereotactic biopsy. The histopathological result was evaluated as Grade 2 astrocytoma. The patient was given six cycles of temozolomide chemotherapy. Due to the progress in the lesions, the patient was referred to the department of radiotherapy.

**Case 2:** A fifty-eight-year-old male patient was admitted to the hospital with weakness in his legs 3-4 months ago. The MRI revealed diffuse involvement in the left frontal and right insular regions along with the right frontal cortex. After the stereotactic biopsy, the histopathological findings showed that the patient had Grade 3 GC-related tumor infiltration.

We performed computed tomography in the supine position. After achieving proper immobilization (flat headboard and head thermoplastic mask) and contrast enhanced planning, CT scans were taken with 3 mm slice thickness target volumes and contours for organs at risk were created within the Velocity treatment planning system fused with MRI scans. We delineated the clinical target volume (CTV) by using the tomography and MRI findings. The hyperintense involvement on the T2 sequence on MR was evaluated as CTV while PTV (planning target volume) was delineated by adding 5mm to CTV (Figure 2).

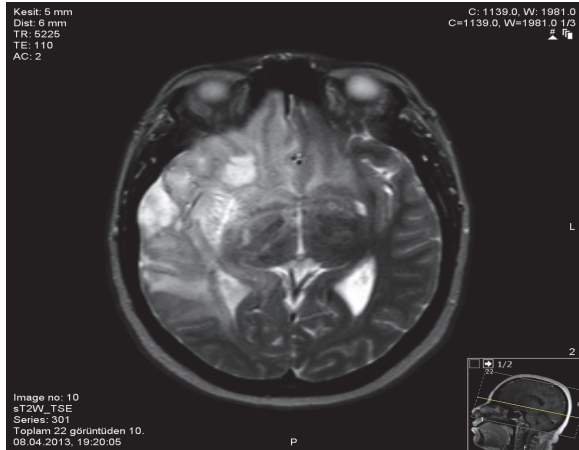


Figure 1. The MRI view of Case 1.

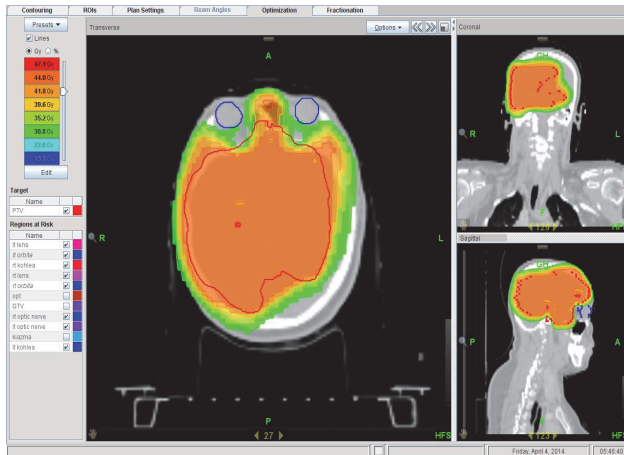


Figure 2. The planning image of Case 1.

We administered 44Gy with 2Gy fraction dose for the first patient and 50Gy with a fraction dose of 2Gy for the second patient. We planned to have a target dose of 95% of PTV, for which the planning treatment objectives were to cover at least 95% of the PTV with the 95% isodose. Prior to each treatment session, we performed MV-CT imaging and, after setting the PTV localisation, we initiated the treatment with a Helical Tomotherapy device. Throughout the radiotherapy, we did not observe acute complications other than grade 1 skin reactions; the patients tolerated the treatment well.

Both of our patients were still alive six months after the radiotherapy. The current cranial MRI shows that the disease is stable without any progress as in the case they were in when they first presented at our clinic.

## DISCUSSION

GC is a very rare brain malignancy. The WHO diagnostic criteria for GC are involvement of at least the two of the lobes of the brain despite well-protected brain architecture, the presence of a necrotic area in the middle and cellular structure. It can be differentiated

from other diffuse infiltrating gliomas by the lack of a mass in the middle and that it does not bring about tissue destruction (2, 3).

Because of its variable clinical features, it is difficult to diagnose GC. It can be seen in every age group. Its clinical symptoms are quite variable though headache, fatigue, and muscle weakness are among the most common symptoms.

The gold standard in the diagnosis of GC is the T2-weighted MR imaging. The common MRI finding is the diffuse infiltration from the cortex towards the sulcus and the loss of the boundary between the gray matter and white matter. FLAIR sequence is also good at revealing the extent of the lesion, callosum infiltration, and cortical involvement (4, 5). Though it is less revealing compared to MRI, brain positron emission tomography (PET / CT) imaging can also help in showing the extension of the tumour. It has been found out that the grey matter looks less hypometabolic than it is normally viewed in PET/CT. Therefore, radiological and histopathological correlation is important in the diagnosis of GC (6).

Many series have shown that radiotherapy contributes to survival. Survival rate varies from 1.5 to 55 months in several studies (7, 8). However, it should be kept in mind that some studies relate longer survival periods because they consider the start of complaints as the beginning of the survival time while other studies take the biopsy date as the start of the survival period (9). Survival in patients who do not undergo radiotherapy is highly variable (between 1 week and 15 years), the average being 3-6 months (8, 10).

Tallibert et al.'s survey of the ANOCEF database and the literature analyses 296 GC patients in terms of age, sex, histology, survival, and treatment. Their study relates that the median age of incidence is 42 (1 month-85 years) with a median survival rate of 14.5 months. This was 36 months in oligodendroglial GC, 14 months in mixed GC, and 11 months in astrocytic GC, respectively ( $p < 0.001$ ). Oligodendroglial component was found to be a good prognostic factor. Because oligodendroglial components are more common in male patients and because male patients are usually younger, the survival rate for these patients was higher (17 months to 11.5 months). The survival rate of the 105 patients who did not receive radiotherapy was 11 months (ranging between 1 month and 16 years). Radiotherapy has been found to have a positive effect in clinical and radiological improvement, but the full impact on survival could be detected (11).

Radiotherapy has proven to be an effective method in a 30-patient MD Anderson series. 87% of these patients have shown radiological improvement while 70% have come up with clinical improvement at the end of the treatment. The median survival rate was 18 months. Younger patients and patients with non-glioblastoma histology had higher survival rates (12).

Another modality in GC's treatment is temozolomide chemotherapy. Temozolomide is an agent used in malignant gliomas and Gliomatosis Cerebri (13, 14). It is hoped that temozolomide therapy, accompanied by radiotherapy, may lead to better results, but there is a need for further studies on this issue.

Both of the patients presented in this report are stable after the radiotherapy. The location, dose, or volume of radiotherapy in GC patients is still not clear. There is need for further studies on this subject.

Due to the new display methods and developments in molecular techniques, we learn more about GC each day. As we keep learning more about GC, we will be able to shape our treatment strategies for this disease in the coming years. In the light of the available information on GC, we can conclude that cranial radiotherapy may be a successful method in treating GC.

## REFERENCES

1. Nevin S. Gliomatosis cerebri. *Brain*.1938;170-91.
2. Kleihues P, Cavenee WK. World Health Organization classification of tumors. Pathology and genetics of tumors of the central nervous system. Lyon: IARC Press, 2000.
3. Elshaiikh MA, Stevens GH, Peereboom DM, Cohen BH, Prayson RA, Lee SY, Barnett GH, Suh JH. Gliomatosis Cerebri: Treatment results with Radiotherapy alone. *Cancer*. 2002 Nov 1;95(9):2027-31.
4. Bendszus M, Marmor-Metz M, Klein R, et al. MR Spectroscopy in gliomatosis cerebri. *AJNR Am J Neuroradiol*. 2000;21:375-380
5. Essig M, Schlemmer HP, Tronnier V, Hawighorst H, Wirtz R, van Kaick G. Fluid-attenuated inversion-recovery MR imaging of gliomatosis cerebri. *Eur Radiol*. 2001;11(2):303-8.
6. Plowman PN, Saunders CA, Maisey MN. Gliomatosis cerebri: disconnection of the cortical grey matter, demonstrated on PET scan. *Br J Neurosurg*. 1998 Jun;12(3):240-4.
7. Cozad SC, Townsend P, Morantz RA, Jenny AB, Kepes JJ, Smalley SR. Gliomatosis cerebri. Results with radiation therapy. *Cancer*. 1996 Oct 15;78(8):1789-93.
8. Fallentin E, Skriver E, Herning M, Broholm H. Gliomatosis cerebri--an appropriate diagnosis? Case reports. *Acta Radiol*. 1997 May;38(3):381-90.
9. Kim DG, Yang HJ, Park IA, Chi JG, Jung HW, Han DH, Choi KS, Cho BK. Gliomatosis cerebri: clinical features, treatment, and prognosis. *Acta Neurochir (Wien)*. 1998;140(8):755-62.
10. Artigas J, Cervos-Navarro, Iglesias JR, Ebhardt G. Gliomatosis cerebri: clinical and histopathologic findings. *Clin Neuropathol*. 1985;4:135-48
11. Taillibert S, Chodkiewicz C, Laigle-Donadey F, Napolitano M, Cartalat-Carel S, Sanson M. Gliomatosis cerebri: a review of 296 cases from the ANOCEF database and the literature. *J Neurooncol*. 2006 Jan;76(2):201-5.
12. Perkins GH, Schomer DF, Fuller GN, Allen PK, Maor MH. Gliomatosis cerebri: improved outcome with radiotherapy. *Int J Radiat Oncol Biol Phys*. 2003 Jul 15;56(4):1137-46.
13. O'Reilly SM, Newlands ES, Glaser MG, Brampton M, Rice-Edwards JM, Illingworth RD, Richards PG, Kennard C, Colquhoun IR, Lewis P, et al. Temozolomide: a new oral cytotoxic chemotherapeutic agent with promising activity against primary brain tumours. *Eur J Cancer*. 1993;29A(7):940-2.
14. Benjelloun A, Delavelle J, Lazeyras F, Dietrich PY. Possible efficacy of temozolomide in a patient with gliomatosis cerebri. *Neurology*. 2001 Nov 27;57(10):1932-3.

Received/Başvuru: 15.04.2014, Accepted/Kabul: 21.05.2014

## Correspondence/İletişim

Öztun TEMELLİ  
İnönü Üniversitesi Tıp Fakültesi, Radyasyon Onkoloji,  
Anabilim Dalı, MALATYA, TÜRKİYE  
E-mail: droztun@gmail.com

## For citing/Atf için

Temelli O, Eraslan AF, Yaprak B, Ekici K. The role of radiotherapy in gliomatosis cerebri: two case reports *J Turgut Ozal Med Cent* 2015;22:53-5 DOI: 10.7247/jtomc.2014.2047