

## Gastric Hepatoid Adenocarcinoma: A Case Report and Literature Update

Şamil Ecirli<sup>1</sup>, Yavuz Sultan Selim Akgül<sup>1</sup>, Orkide Kutlu<sup>2</sup>, Gökhan Güngör<sup>1</sup>, Abdullah Sakin<sup>3</sup>

<sup>1</sup>Konya Training and Research Hospital, Internal Medicine Clinic, Konya, Turkey

<sup>2</sup>Okmeydanı Training and Research Hospital, Internal Medicine Clinic, Istanbul, Turkey

<sup>3</sup>Okmeydanı Training and Research Hospital, Oncology Clinic, Istanbul, Turkey

### Abstract

Hepatoid adenocarcinomas (HAC) are very rare extrahepatic tumours that have very poor prognosis. The majority of these tumours are recognized by the height in serum AFP. The incidence rate for reported gastric tumours from the Far East is between 1,3% and 15% but there are only case reports available from other regions. There are two types of HAC: well-differentiated papillary/tubular type and medullary type with polygonal cells. AFP, CEA, CK7, and CK20 have effects on survival. HAC is treated in the way traditional gastric adenocarcinomas are treated. Hepatoid adenocarcinoma of the stomach has poor prognosis. It is often metastatic at diagnosis with an average life expectancy of 4,7 months. Here, we present a rare case of a chemotherapy-resistant patient diagnosed with hepatoid adenocarcinoma in our clinic.

**Key Word:** Hepatoid Adenocarcinoma; AFP; HCC.

### Gastrik Hepatoid Adenokarsinoma: Olgu Sunumu ve Literatür Güncellemesi

### Özet

Hepatoid adenokarsinomalar (HAC) çok nadir rastlanan ve oldukça kötü prognozlu ekstrahepatik tümörlerdir. Bu tümörlerin büyük çoğunluğu serumda AFP yüksekliği ile tanınmaktadır. İnsidansı en sık görüldüğü Uzakdoğu için gastrik tümörlerin %1,3–15 olarak bildirilmiş, diğer bölgelerden vakalar şeklinde bildirim mevcuttur. İyi differansiye papiller/tubuler ve poligonol hücrelerden oluşan medüller tip olmak üzere iki tipi tanımlanmıştır. AFP, CEA, CK7 ve CK20 nin survi üzerine etkisi gösterilmiştir. HAC lar da klasik mide adenokarsinomaları gibi tedavi edilmeye çalışılır. Adjuvan kemo-radyoterapi verilebilir. Midenin hepatoid adenokanseri kötü prognozlidir. Genellikle tanı konduğunda metastatik olup, ortalama yaşam beklentisi 4,7 aydır. Burada kliniğimizde hepatoid adenokarsinoma tanısı koyduğumuz ve kemoterapiye dirençli hastamızı nadir rastlanması sebebi ile sunduk.

**Anahtar Kelimeler:** Hepatoid Adenokarsinom; AFP; HCC.

## INTRODUCTION

Hepatoid adenocarcinomas (HAC) are very rare extrahepatic tumours with very poor prognosis and they share similar histopathological properties with hepatocellular carcinoma (HCC). The majority of these tumours synthesise alpha fetoprotein (AFP), which makes it easier to recognise them due to high AFP levels in the serum. Although they most frequently occur in the stomach, they can be seen in a variety of localisations such as lungs, bladder, renal pelvis, ureters, ovaries, uterus, jejunum, colon, rectum, oesophagus, gall bladder, pancreas, and papilla of Vater. Its incidence in the far east, where it is most common, reaches from 1,3% up to 15% among gastric tumours while there are only a few reported cases from Europe and North America (1).

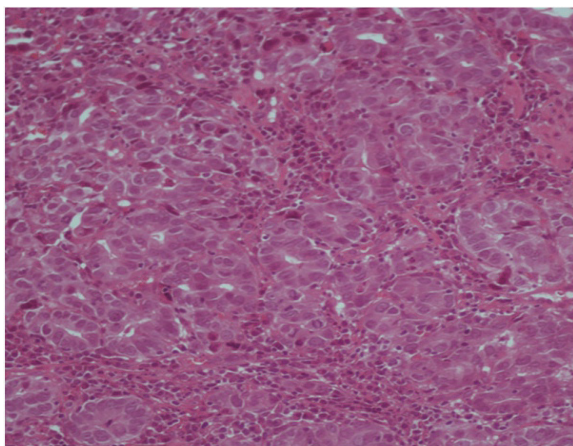
It was first defined by Bourelli in the 1970s. Later, it was Kodama et al. who defined the two types of the HACs consisting of well-differentiated papillary/tubular and medullary polygonal cells in AFP-producing gastric carcinomas. Histologically, it is made of trabecular or

solid islands with narrow stromal fibrosis and sinusoid-like capillaries. Vascular invasion is more common compared to other types of stomach cancers (2). In 1985, Ishikura et al. defined hepatoid adenocarcinoma of the stomach with hepatoid differentiation in gastric carcinomas and high levels of AFP secretions (3). However, there are still AFP-negative gastric carcinomas that have hepatoid properties without AFP secretion or tumours with AFP secretion that lack hepatoid differentiation. Today, this condition is still defined in single cases or series of cases. When diagnosed, it is usually metastatic and the average life expectancy is 4,7 months (4). Because of its rarity, we aim to present the case of one of our patients who, after having previously been admitted to various centers with complaints of abdominal pain for the last two years, was diagnosed with hepatoid adenocarcinoma and was chemotherapy-resistant.

## CASE REPORT

A female patient who had complaints of fatigue, loss of appetite, constipation, and abdominal pain for the last two years had a history of laparotomy and drainage due

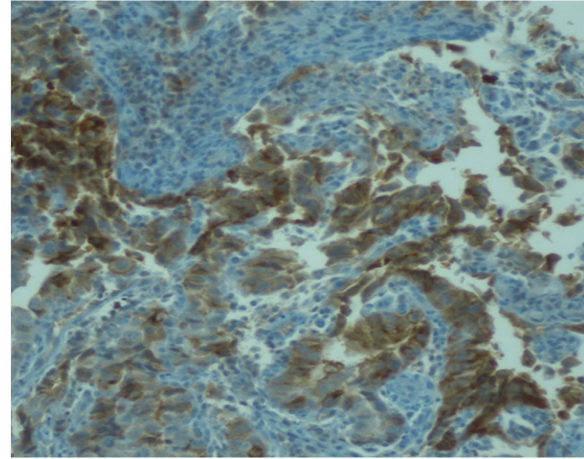
to acute abdomen in 2010. The patient, who could not define the exact location of abdominal pain that reared from time to time, had fatigue, aggravation, and significant weight loss over the past year. Having detected various metastases in the liver, the peripheral centre that admitted the patient initially referred the patient to our clinic for further investigations. The examination results were as follows: the blood pressure measured at the bilateral arm: 140/80mm/Hg; pulse: 76/min; temperature: 36,6 C degrees; body mass index: 30 kg/m<sup>2</sup>. The patient had pale skin and mucous membranes. The cardiac examination showed 2/6 short systolic murmur; the liver was midclavicular 5 cm palpable. The patient had a history of diabetes mellitus (1 year ago), laparotomy, (2 years ago), hysterectomy (15 years ago), and tonsillectomy (20 years ago). Her parents died because of lung cancers. Complete blood count, erythrocyte sedimentation, ALT, and CEA values were within normal limits. AST: 46 U/l (5-34 U/l); GGT: 105 U/L (9-36 U/L); uric acid: 7.4 mg/dL (0.2-6 mg/dL); CRP: 49 mg/L (0-5 mg/L); HBA1C: 7.1% (4-6%); AFP: 998 ng/ml (0-8 ng/ml); Dynamic MR of the liver showed many solid lesions, the largest of which was 2 cm in diameter. The lesions were hyperintense on T2 sequence and hypointense on T1 sequence; the lesions were portal in the arterial phase while they showed locational enhancement in the late phases. Because the lesions had enhancement, this was not compatible with hepatoma; therefore, we evaluated the medical picture in favor of metastasis. Gastroscopy showed fragile irregular ulcerated masses in gastric corpus on the side of the greater curvature in a segment of 7-8 cm. The lesions were grape-like and lobular. In the light of the available data, the patient was considered as having metastatic gastric cancer. Biopsy material obtained with endoscopy were stained with AFP, p53, and p-CEA although the tumor cells were not stained with Hep Par, CD 34, Cd 10, or CK 7 and showed intraluminal mucin deposition (Figure 1, 2).



**Figure 1.** Tumour, showing glandular formations is infiltrated by inflammatory cells (Hematoxylin eosinX200, original view).

The chest CT revealed two pleural nodules and metastatic lymph nodes in the gastrohepatic distance, the larger of which was 2 cm. Observing progression

after the implementation of 3 cycles of docetaxel, cisplatin, 5-FU, and 3 cycles of cisplatin and capecitabine throughout the chemotherapy, we started cisplatin and irinotecan treatment 10 months after the diagnosis.



**Figure 2.** Carcinoma cells showing positive staining with AFP (AFPX200, original view).

## DISCUSSION

The development mechanism of hepatoid adenocarcinoma from stomach is not exactly known but some researchers have stated that hepatoid adenocarcinoma develop from the remains of liver that stay in the stomach due to various shortcomings during embryogenesis when both stomach and liver develop out of the front intestine. Of the 85 cases reported in the literature, the average age of diagnosis has been found to be 63,5 (between 44-87 years of age) while the male-female ratio was 2,3-1. Tumours are usually localised in the antrum and pylorus with an average tumour size of 6,5 cm (ranging from 1,6 up to 14cm). There are no symptoms specific to this tumour. Abdominal pain and anemia-related weakness and fatigue are the most common symptoms. Many patients have lymph nodes and liver metastases at diagnosis (5).

The immunohistochemical examination showed strong AFP positivity. The positive Periodic Acid Schiff (PAS) and the presence of diastase-resistant intracytoplasmic eosinophilic globules were among other evidences supporting hepatoid gastric cancer diagnosis along with the immunohistochemical positivity of AFP, alpha-1 antitrypsin, alpha-1 antichymotrypsin, CDX2, and CD10 (6). In a recently published study, it has been put forward that AFP, CEA, CK7, and CK20 have an effect on survival. The suppressive effect of AFP on lymphocyte transformation and the effects of CEA on cancer cells resulting in malfunction and biological behavioural disorders may lead to poor prognosis. The epithelial markers CK18/CK19 and AE1/AE3 (100% and 74%, respectively) are often positive for HAC and this is a significant sign in differentiating it from HCC. Although CK7 and CK20 appear in low levels (35%), those which could not hold staining survived significantly longer (7). Primary and metastatic gastric HAC must also be

differentiated from HCC. Generally, there are concomitant cirrhotic lesions in HCC while tumour cells are immune positive for Hep Par-1, a sensitive and specific immunohistochemical indicator of hepatocyte differentiation. However, gastric HAC is usually negative for Hep Par-1 as it does not show any accompanying cirrhotic lesions either (8). Despite the fact that protein P53 is frequently expressed in traditional adenocarcinoma and, thus, pinpoints poor prognosis, the immunohistochemical expression of P53 in HAC is rare. The immune staining of PLUNC (palate, lung, and nasal epithelium carcinoma associated protein) is also a distinctive marker of HAC (9). However, markers showing hepatoid differentiation should not be considered as the sole diagnostic criteria for the diagnosis of HAC; these markers must always be supported by other accompanying histological patterns. Besides, practitioners should take other AFP producing tumors and germ cell tumours into account as well in the differential diagnosis.

Due to our lack of knowledge about the condition, the treatment of gastric HAC is carried out like that of other gastric adenocarcinomas. If possible, primary tumor should be removed in early stages. Adjuvant chemoradiotherapy may also be applied. Studies conducted have reported chemotherapy to be superior to supportive treatment. Palliative chemotherapy is recommended for all patients with good performance in advanced stages of gastric cancer. Although patients respond better to combined chemotherapy compared to monotherapy, it has been reported that these two options have similar effects on survival. Therapy with epirubicin alone or combination therapy with cisplatin+5-fluorouracil is considered the most effective treatments (10). An AFP-producing hepatoid gastric cancer patient with multiple liver metastasis has been reported to be successfully cured with paclitaxel-based chemotherapy (11). Besides, metastasectomy can also be applied in selected cases for liver metastases.

The hepatoid gastric adenocarcinoma has poor prognosis. Hepatoid tumours may be resistant to chemotherapy (6). The tumour was resistant to chemotherapy in our case; we did not observe the expected decrease in the tumour or good clinical state of the patient after chemotherapy.

A multidisciplinary approach should be targeted for optimal results in the treatment of gastric hepatoid adenocarcinoma. There is need for more studies to clearly understand the molecular pathogenesis of the disease; and, in this way, new treatments may be developed for the tumour if we know more about its origins.

## REFERENCES

1. Su JS, Chen YT, Wang RC, Wu CY, Lee SW, Lee TY. Clinicopathological characteristics in the differential diagnosis of hepatoid adenocarcinoma: a literature review. *World J Gastroenterol* 2013;19:321-7.
2. Liu X, Sheng W, Wang Y. An analysis of clinicopathological features and prognosis by comparing hepatoid adenocarcinoma of the stomach with AFP-producing gastric cancer. *J Surg Oncol* 2012;106:299-303.
3. Ishicura H, Fukosawa Y, Ogasawara K, Natori T, Tsukada Y, Aizawa M. An AFP producing gastric carcinoma with features of hepatic differentiation: a case report. *Cancer* 1985;56:840-8.
4. Bakır T, Aliyazicioğlu Y, Bektaş A, Siviloglu C, Ozgur O. Hepatoid adenocarcinoma of the stomach, report of five cases and review of the literature. *Acta Gastroenterol* 2006;69:330-7.
5. Inagawa S, Shimazaki J, Hori M et al. Hepatoid adenocarcinoma of the stomach: case report. *Gastric Cancer* 2001;4:43-52.
6. Gálvez-Muñoz E, Gallego-Plazas J, Gonzalez-Orozco V et al. Hepatoid adenocarcinoma of the stomach—a different histology for not so different gastric adenocarcinoma: a case report. *Int Semin Surg Oncol* 2009;6:13.
7. Yang J, Wang Rui, Zhang W, Zhuang W, Wang M, Tang C. Clinicopathological and Prognostic Characteristics of hepatoid adenocarcinoma of The stomach. *Hindawi* 2014;1-5.
8. Gao YB, Zhang DF, Jin XL, Xiao JC. Preliminary study on the clinical and pathological relevance of gastric hepatoid adenocarcinoma. *J dig dis* 2007;8:23-8.
9. Sentani K, Oue N, Sakamoto N, Arihiro K, Aoyagi K, Sasaki H. et al. Gene expression profiling with microarray and SAGE identifies PLUNC as a marker for hepatoid adenocarcinoma of the stomach. *Mod pathol* 2008;21:464-75.
10. Wöhrer SS, Raderer M, Hejna M. Palliative chemotherapy for advanced gastric cancer. *Ann Oncol* 2004;15:1585-95.
11. Takeyama H, Sawai H, Wakasugi T, Takahashi H, Matsuo Y, Ochi N et al. Successful Paclitaxel- based chemotherapy for an alpha- fetoprotein- producing gastric cancer patient with multiple liver metastases. *World J Surg oncol* 2007;5:79-83.

Received/Başvuru: 16.09.2014, Accepted/Kabul: 03.11.2014

Correspondence/İletişim

Orkide KUTLU  
Okmeydanı Eğitim ve Araştırma Hastanesi, İç Hastalıkları  
Kliniği, İSTANBUL, TURKEY  
E-mail: orkidekutlu@windowslive.com

For citing/Atıf için

Ecirli S, Akgül YSS, Kutlu O, Güngör G, Sakin A. hepatoid adenocarcinoma: a case report and literature update. *J Turgut Ozal Med Cent* 2015;22:210-2 DOI: 10.7247/jtomc.2014.2378