

Evaluation of Diagnostic Value of Imaging and Laboratory Tests in Patients Who Underwent Laparotomy with The Diagnosis of Acute Appendicitis

Ramazan Ünal ©
Dilek Atik ©
Ramazan Güven ©
Hasan Çam ©
Mustafa Sait Din ©
Başar Cander ©

Akut Apandisit Tanısı ile Apendektomi Yapılan Hastaların Laboratuvar ve Görüntüleme Tetkiklerinin Tanısal Değeri

ABSTRACT

Objective: Acute appendicitis (AA) is an inflammation of the appendix vermicularis tissue. In this study, we planned to investigate the efficacy of imaging, laboratory tests of patients who were followed up with the pre-diagnosis of AA and underwent laparotomy.

Method: In this study the files of patients who were operated on between 01.01.2018, and 12.30.2018 with the preliminary diagnosis of acute appendicitis in the Department of Emergency Medicine, Istanbul Kanuni Sultan Süleyman Education and Research Hospital of Istanbul Health Sciences University, were retrospectively reviewed. Abdominal computed tomography (ACT) revealed thickening of the appendiceal wall, increased streaking in the periceal region, the presence of appendicolitis, and free fluid in the periceal region were evaluated in favour of AA. The presence of non-compressible, blind-terminated tubular structure > 6 mm in diameter, target-sign on transverse examination, or presence of intraluminal hyperechoic appendicolith were considered as positive findings.

Results: Considering the correlation between AA and blood parameters, there was a statistically weak negative correlation between neutrophilia and leukocytosis. There was no statistically positive or negative correlation with CRP as acute phase reactant. We believe that leukocyte count, other inflammatory markers, USG, CT, especially along with clinical findings, should be the tests to aid the surgeon in the diagnosis. When deciding on a laparotomy in AA, the surgeon should see and interpret all examination results, evaluate the patient with clinical findings, and add his/her experience and foresight.

Conclusion: High diagnostic sensitivity of non-contrast CT compared to other imaging techniques comes to the fore as an auxiliary diagnostic tool in making diagnosis. It can be considered as the first choice instead of contrast-enhanced CT in patients who are thought to have AA in order to reduce the side effects of contrast media.

Keywords: computed tomography, acute appendicitis, ultrasound

ÖZ

Amaç: Akut apandisit (AA), apandiks vermikularis dokusunun iltihaplanmasıdır. Bu çalışmada, AA ön tanısı ile takip edilen ve laparotomi yapılan hastaların görüntüleme ve laboratuvar testlerinin etkinliğini araştırmayı planladık.

Yöntem: Bu çalışma, İstanbul Sağlık Bilimleri Üniversitesi Kanuni Sultan Süleyman Eğitim ve Araştırma Hastanesi Acil Tıp Kliniği'ne 01.01.2018-31.12.2018 tarihleri arasında akut apandisit ön tanısı ile ameliyat edilen hastaların dosyası geriye dönük olarak incelendi. Batın Bilgisayarlı Tomografide (BBT) apendiks duvarında kalınlaşma olması, pericekal bölgede çizgilenme artışı, apendikolit varlığı, pericekal bölgede serbest sıvı varlığı AA lehine kabul edildi. Kompresyona edilemeyen, kör sonlanan > 6 mm çaplı tübüler yapı görülmesi, transvers incelemede hedef görünümü (target-sign) veya intraluminal hiperekoik apendikolit odağı olması pozitif bulgu olarak kabul edildi.

Bulgular: AA ve kan parametreleri arasındaki korelasyon göz önüne alındığında, nötrofil ve lökosit arasında istatistiksel olarak zayıf bir negatif korelasyon vardı CRP akut faz reaktanı ile istatistiksel olarak pozitif veya negatif bir korelasyon yoktu. Lökosit sayısının, diğer inflamatuvar belirteçlerin, USG ve BT'nin, özellikle klinik bulgularla birlikte, tanıda cerrahi destekleyen testler olması gerektiğine inanıyoruz. AA'da laparotomiye karar verirken, cerrah tüm muayene sonuçlarını görmeli ve yorumlamalı, hastayı klinik bulgularla değerlendirmeli ve deneyimini ve öngörüsünü eklemelidir.

Sonuç: Diğer görüntüleme tekniklerine kıyasla kontrastsız BT'nin yüksek duyarlılığı, tanı koymada yardımcı bir tanı aracı olarak öne çıkmaktadır. Kontrast maddelerinin yan etkilerini azaltmak amacıyla AA olduğu düşünülen hastalarda kontrastlı BT yerine ilk seçenek olarak düşünülebilir.

Anahtar kelimeler: bilgisayarlı tomografi, akut apandisit, ultrason

Received/Geliş: 11.01.2020
Accepted/Kabul: 04.09.2020
Published Online/Online yayın: 30.09.2020

Atıf vermek için: Ünal R, Atik D, Güven R, Çam H, Din MS, Cander B. Evaluation of imaging and laboratory tests in patients who underwent laparotomy with the diagnosis of acute appendicitis. İKSSTD 2020;12(3):268-75.

Ramazan Ünal
S.B.Ü İstanbul Kanuni Sultan Süleyman
Eğitim ve Araştırma Hastanesi
Acil Tıp Kliniği
İstanbul - Türkiye
✉ dr.ramazanunal@gmail.com
ORCID: 0000-0002-6181-4644

D. Atik 0000-0002-3270-8711
Bozok Üniversitesi Tıp Fakültesi
Dahili Tıp Bilimleri Bölümü
Acil Tıp Anabilim Dalı
Yozgat - Türkiye

R. Güven 0000-0003-4129-8985
H. Çam 0000-0002-1088-7202
B. Cander 0000-0002-3308-5843
S.B.Ü İstanbul Kanuni Sultan Süleyman
Eğitim ve Araştırma Hastanesi
Acil Tıp Kliniği
İstanbul - Türkiye

M. S. Din 0000-0003-4158-0366
İnönü Üniversitesi Tıp Fakültesi
Acil Tıp Anabilim Dalı
Malatya - Türkiye

INTRODUCTION

Acute appendicitis (AA) is an inflammation of the appendix vermicularis tissue. AA can be confused with other diseases due to its varying clinical manifestations during development. AA is one of the most common diseases that requires urgent surgical intervention and delays in the diagnosis may lead to significant morbidities. Almost 7% of the entire population is diagnosed with AA at some time in their lives and undergo surgery, and the disease is frequently seen between 10 and 30 years of age ^(1,2). Despite technological advancements, history and physical examination have still important place in the diagnosis of AA. Abdominal pain, nausea, vomiting and loss of appetite are the most common symptoms of AA. For abdominal pain, it is important that the slight pain, which initially arises around the umbilicus, is located in the right lower quadrant within hours. A meticulous systemic examination is necessary for diagnosis. The most important findings on physical examination are tenderness in the right lower quadrant, rebound tenderness, pain and defense to percussion. These symptoms and findings are helpful in supporting the diagnosis. The diagnosis is easy in typical cases. Especially in atypical cases, the diagnosis is extremely difficult and auxiliary imaging and laboratory tests are used during the diagnostic process. The knowledge of inflammatory parameters (leukocyte counts and percentage of neutrophils, CRP value, etc.), in particular baseline laboratory parameters, and the course of these markers in serial follow-ups have also been regarded important in the diagnosis of AA ^(3,4). The risk of perforation increases if the diagnosis of acute appendicitis is delayed and accordingly, the rates of mortality and morbidity increase. In order to prevent this, the probability of encountering a normal appendix vermiformis during the operation, called negative laparotomy in previous years, has been reported to range between 13-36% ^(4,5). The importance of auxiliary imaging studies has increased in patients clinically suspected of acute appendicitis due to the postoperative complications and misdiagnoses. From past to the present, first ultrasound and then computed tomography in addition to the laboratory tests have been included in the tests ordered for the diagnosis of AA. The evaluation of appendicitis by ultrasonography was first initiated in the early 1980s ⁽⁶⁾. In

1986, Puylaert alleviated the negative doubts by demonstrating that appendicitis could be visualized with the graded compression technique described by him ⁽⁷⁾. Although the use of computed tomography (CT) was previously limited due to its disadvantages such as being expensive and not available everywhere, CT is now more widely used in the diagnosis of appendicitis ⁽⁸⁾. Diagnostic sensitivity and specificity are excellent for the entire spectrum of disease manifestations and do not decrease after appendiceal perforation. Unlike ultrasound, obesity rarely limits acquisition or interpretation of data, when optimized scanning methods are used ⁽⁹⁾. In this study, we planned to investigate the efficacy of imaging and laboratory tests of patients who were followed up with the pre-diagnosis of AA and underwent laparotomy.

In this study, the files of 576 patients who were operated with a pre-diagnosis of acute appendicitis were retrospectively reviewed. Clinical diagnosis was based on complete blood count and / or radiological findings. The definitive diagnosis was made by postoperative histopathological examination.

MATERIAL and METHOD

This study was carried out between the dates of 01.01.2018-31.12.2018 in the Department of Emergency Medicine, Istanbul Kanuni Sultan Süleyman Education and Research Hospital of Istanbul Health Sciences University. In this study the files of patients who were operated on with the preliminary diagnosis of acute appendicitis were retrospectively reviewed. This study was conducted with the permission of Ethics Committee of Kanuni Sultan Süleyman Training and Research Hospital of Istanbul Health Sciences University. A total of 576 patients, aged 18 years were included in the study, diagnosis and treatment process was completed in our hospital and at least one of the imaging tests was performed. Clinical diagnosis was based on complete blood count and / or radiological findings. The definitive diagnosis was made by postoperative histopathological examination. Laboratory tests were performed at admission, and leukocyte count and neutrophil percentage, CRP results were recorded in the study form. Leukocyte, and neutrophil counts were accepted as leucocytosis and neutrophilia respectively, if the relevant test results of the hospital laboratory

were above the cut-off values determined by age and sex. Patients with a CRP value of 5 mg/L or higher were considered to be CRP elevation. Patients diagnosed with cataract, simple, suppurative, gangrenous, perforated and phlegmenatous AA by histopathological examination were considered as other histopathologic diagnoses.

Imaging Technique

CT imaging; 128-section CT device (Toshiba Aquilion prime 160), (section thickness ≤ 2 mm; matrix 512 × 512 pixels; gantry angle 0°). The scan area was between the diaphragm level and the symphysis pubis. All images were reconstructed with the help of medical imaging program (AW Volume Share 5) and reconstructed in different imaging plans. Abdominal computed tomography (ACT) revealed thickening of the appendix wall, increased streaking in the pericheal region, the presence of appendicolitis, and free fluid in the pericheal region.

USG imaging was performed using Toshiba Aplio 500 with 9 MHz linear transducer. During ultrasonography, the right iliac fossa was scanned with a linear transducer. The presence of non-compressible, blind-terminated tubular structure >6 mm in diameter, target-sign on transverse examination, or presence of intraluminal hyperechoic appendicolith were considered as positive findings.

Statistical Analysis

Compliance with the parametric test criteria were evaluated with statistical analysis and Kolmogorov-Smirnov test. The data obtained from the study conducted within the scope of clinical research were statistically nonparametric. Correlation test was performed for clinical outcome and compliance. Significant differences were accepted if p<0.05. Sensitivity, specificity, positive, and negative identification and accuracy rates were calculated for leukocytosis and neutrophilia rates, and for ultrasonography, Contrast-enhanced Abdominal Computed Tomography (CABT) and non-contrast Abdominal Computed Tomography (nCABT). ROC Curve Analysis was performed to evaluate the superiority of the tests in blood parameters.

RESULTS

The data of 576 patients who met the inclusion cri-

teria were analyzed in the study. Of the patients, 65.45% (n=377) were male and 34.54% (n=199) were female and the age range was 18-79 years (the mean age, 32.75±11.77 years). Given the age distribution of the patients, the highest frequency of patients was determined to be in 20 years of age with 5% (n=29). Patients aged 18-30 years accounted for 51.8% and patients aged 18-38 years for 73.78% of the cases. It was found that the frequency of cases decreased with increasing age (Figure 1). Of the patients operated, 95.48% (n=550) were histopathologically diagnosed with AA. Of the 199 female patients, 94.47% (n=188) were histopathologically found to have AA, while 5.5% (n=11) had a different histopathologic diagnosis. Of the 377 male patients, 96% (n=362) were histopathologically found to have AA, while 4% (n=15) had a different histopathologic diagnosis (Table 1).

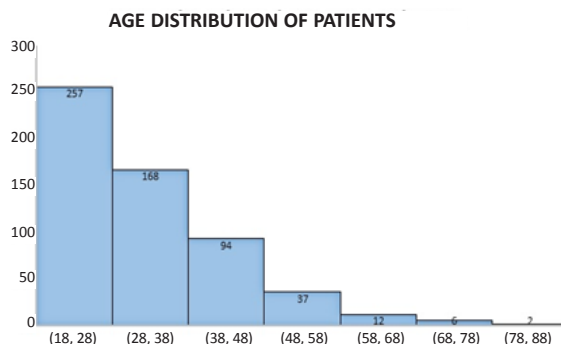


Figure 1. Age distribution of patients with acute appendicitis.

Other than AA, a histopathologically different diagnosis was made in the indicated number of patients in age groups of 18-28 (1.5%: n=4), 28-38 (4.7% :n=8), 38-48 (.2% (n=8), 51.8%) 48-58 (10.8% :n=4) , and ≥ 58 (10% :n=2) years. The incidence of histopathological diagnosis other than acute appendicitis increased with age (Figure 2).

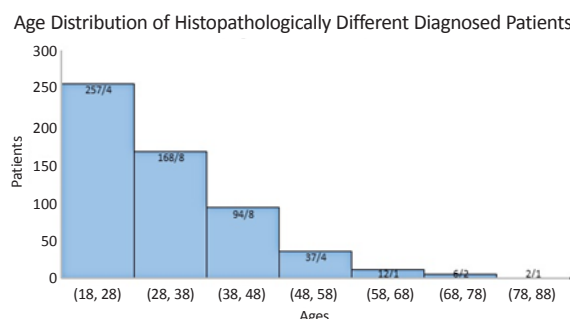


Figure 2. Age distribution of histopathologically different diagnosed patients.

Table 1. Distribution of histopathological diagnoses by sex.

Pathological Diagnosis	Sex		Total
	Female	Male	
Acute appendicitis	188	362	550
Adenocarcinoma	2	0	2
Fibrous obliteration	1	0	1
Carcinoid tumor	2	0	2
Cholecystitis	0	1	1
Lymphde hyperplasia	2	11	13
Mucocele	2	1	3
Mucinous neoplasm	2	1	3
Follicular hyperplasia, fibrous obliteration	0	1	1
Total	199	377	376

Table 2. Histopathological diagnosis and evaluation of neutrophil elevation.

	Histopathological Diagnosis		
	Positive	Negative	
Positive	413	8	421
Negative	136	18	154
Total	549	26	575

Neutrophil percentage was studied in 575 of the patients and neutrophilia was detected in 73.2% (n=421) of these patients. In our study, the diagnostic sensitivity, specificity, positive, and negative predictive values and accuracy rate of neutrophilia were 75.23%, 69.23, 98.1%, 11.69% and 74.96%, respectively (Table 2).

WBC was studied in 575 of the patients and leukocytosis was detected in 75.47% (n=434) of these patients. The sensitivity, specificity positive, and negative predictive values, and accuracy rate of leukocytosis were 76.87%, 53.85%, 97.24%, 9.93%, and 75.83%, respectively (Table 3). CRP was studied in

Table 3. Histopathological diagnosis and evaluation of WBC height.

WBC Height	Histopathological Diagnosis		
	Positive	Negative	
Positive	422	12	434
Negative	127	14	141
Total	549	26	575

545 of the patients and it was found to be higher than normal in 71.9% (n=392) of these patients. The diagnostic sensitivity, specificity, positive, negative predictive values, and accuracy rate of CRP were calculated as 71.4%, 16.67%, 94.9%, 2.61%, and 68.99%, respectively (Table 4).

Table 4. Histopathological diagnosis and assessment of CRP elevation.

CRP Height	Histopathological Diagnosis		
	Positive	Negative	
Positive	372	20	392
Negative	149	4	153
Total	521	24	545

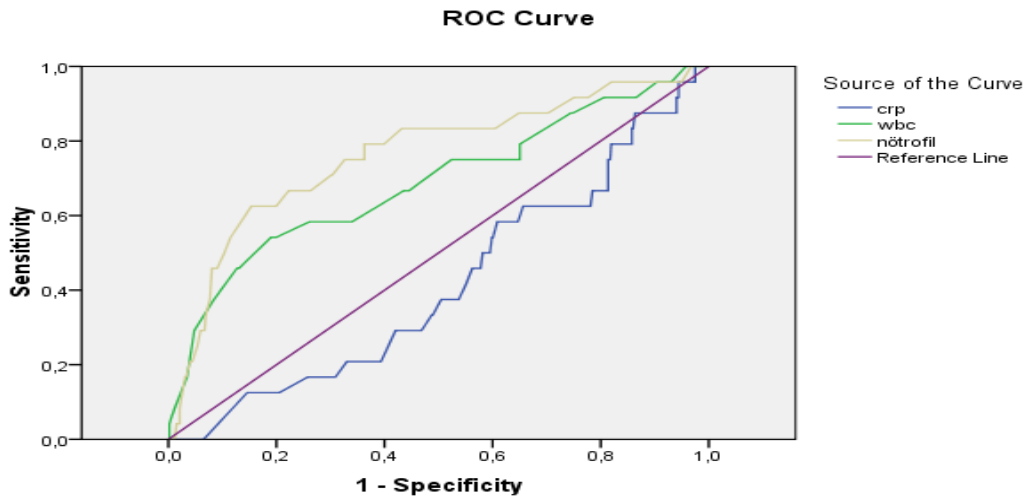
Considering the correlation between AA and blood parameters, there was a statistically weak negative correlation between neutrophilia and leukocytosis (r:-0.148, p<0.000 and r:-0.209, p<0.000). There was no statistically positive or negative correlation with CRP acute phase reactant (r:0.54, p=0.204) (Table 5).

Table 5. Relationship between blood parameters and Acute appendicitis.

Type of variable	Correlation Results	
	r	p
WBC Height	-0.209	0.000 ^a
Neutrophil Height	-0.148	0.000 ^a
CRP Height	0.540	0.204 ^b

^a: Significant at the 0.05 level (p<0.05); ^b: Not significant.

According to the ROC curve analysis results, the AUC values of WBC and neutrophil values were 0.689 (min: 0.564, max: 0.813) p=0.002 and 0.763 (min: 0.653, max: 0.872) p=0.000, respectively. Of both parameters, the AUC value was statistically above 0.5 and the p value was below 0.05, which was found to be statistically significant. Of the CRP blood parameter, the AUC value was 0.417, which was below 0.5, and the p value was 0.167, which was found to be statistically insignificant (Figure 3, Table 6).



Diagonal segments are produced by ties.

Figure 3. ROC curve analysis of WBC, Neutrophil and CRP blood values in acute appendicitis.

Table 6. Evaluation of blood parameters by ROC analysis.

Test Result Variable(s)	AUC	Std. deflection	P value	Asymptotic 95% Confidence Interval	
				Lower Bound	Upper Bound
CRP	,417	,056	,167	,306	,527
WBC	,689	,064	,002	,564	,813
Neutrophil	,763	,056	,000	,653	,872

Table 7. Histopathological diagnosis and evaluation of contrast-enhanced abdominal CT.

Contrast Abdominal CT Radiological Diagnosis	Histopathological Diagnosis		Total
	Positive	Negative	
Positive	307	14	321
Negative	26	4	30
Total	333	18	351

Table 8. Histopathological diagnosis and evaluation of non-contrast abdominal CT.

Non-Contrast Abdominal CT Radiological Diagnosis	Histopathological Diagnosis		Total
	Positive	Negative	
Positive	130	4	134
Negative	6	0	6
Total	136	4	140

Table 9. Histopathological diagnosis and ultrasound imaging method values.

Ultrasound	Histopathological Diagnosis		Total
	Positive	Negative	
Positive	345	15	360
Negative	153	7	160
Total	498	22	520

When the imaging tests were evaluated, 351 patients underwent contrast-enhanced abdominal CT (CEACT), and 321 had radiological findings suggestive or suspicious of AA, and 333 patients were histopathologically diagnosed with AA postoperatively. In our study, the diagnostic sensitivity, specificity, positive predictive value, negative predictive value, and accuracy rate of CEACTION were 92.19%, 22.2%, 95.6%, 13.3%, and 88.6%, respectively. Of the patients, 140 underwent non-contrast abdominal CT (nCACTION) and 134 had radiological findings suggestive or suspicious

Table 10. Sensitivity / specificity ratios of imaging and laboratory tests.

	Contrast Abdominal CT	Non-Contrast Abdominal CT	Ultrasound	Neutrophil	CRP	WBC
Sensitivity	92.19	95.5	69,28	75,23	71.4	76,87
Specificity	22.2	0	31,82	69,23	16,67	53,85
Positive predictive value, (+PV)	95,6	97	95,8	98,1	94,9	97,24
Negative predictive value, (-PV)	13,3	0	4,38	11,69	2,61	9,93
Accuracy rate	94.87	92.86	67,69	74,96	68,99	75,83

of AA. Of these 140 patients, 136 were histopathologically diagnosed with AA. In our study, the diagnostic sensitivity, specificity, positive predictive value, negative predictive value and accuracy of nCACT were 95.5%, 0%, 97%, 0% and 92.86%, respectively.

Of the patients, 520 underwent superficial USG for the abdomen and lower right quadrant, and 360 had findings sonographically suggestive or suspicious of AA. While 15 patients with sonographic findings of AA on USG were histopathologically diagnosed with non-AA, 153 patients without any sonographic finding of AA were histopathologically diagnosed with AA. In our study, the diagnostic sensitivity, specificity, positive predictive value, negative predictive value and accuracy rate of USG were 69.28%, 31.82%, 95.83%, 4.38%, and 67.69%, respectively.

Four hundred and thirty-four patients underwent USG along with CT imaging due to inability to exclude the diagnosis of appendicitis or suboptimal examination.

DISCUSSION

The most common cause of acute surgical abdomen is appendicitis. The most common age for the incidence of AA is between 10 and 30 years in parallel with the development of lymphoid tissue ^(1,2). According to the results of our study, patients aged 18-30 years account for 51.8% the cases, which is similar with the literature ^(10,11). Obstruction of the appendix lumen is the primary cause of AA, and the disruption of venous and lymphatic circulation due to this obstruction leads to bacterial invasion from the appendiceal wall. Delay in the diagnosis causes perforation of the appendix and peritoneal spread of purulent material ^(1,12).

An accurate clinical history and physical examination

are essential for the diagnosis. In appendicitis, pain starting periumbilically and migrating to the right iliac fossa is classic and characteristic.

However, there may be atypical clinical conditions or conditions mimicking other pathologies. In such cases, the most important problem is missing and delaying the diagnosis or misdiagnosis. At this point, some laboratory tests and imaging techniques should be brought into play. In previous studies, acute inflammation markers as leukocytosis, neutrophilia and increased CRP values were also used ^(10,13,14). Unlike our study, the diagnostic sensitivity of leukocytosis among laboratory tests was found to be between 19-60% in some studies ^(7,22).

In a study by Köksal et al. leukocyte –to- neutrophil ratios yielded different results from our study. The percentage of patients with leukocytosis was higher, but those with neutrophilia was lower than our study. In another study by Köksal et al., the diagnostic sensitivity and specificity of leukocytosis and neutrophilia were similar ⁽¹⁵⁾.

In a study, it was indicated that CRP value would increase in complicated appendicitis and would guide the clinician in the absence of tomography ⁽¹⁶⁾. According to the results of another study, similar to our study, it was reported that CRP value could not be used as a surgical indicator like leukocytosis and neutrophil percentage ⁽¹⁷⁾. The imaging method to be used (USG or CT) may vary depending on the center, experience and patient's characteristics. AA may not be detected in about 10-20% of patients undergoing appendectomy ^(18,19). In our study, the rate of patients without the diagnosis of AA was 4.5% among 576 patients operated with the pre-diagnosis of AA. In the study by Celep et al., the rate of negative appendectomy was 15.8% ⁽¹⁹⁾. The reason for our lower

negative rates than the literature is thought to be due to the concurrent evaluation of imaging, laboratory and patient's clinic by the clinician in order to reduce the frequency of negative appendectomy and the defensive approach. In a previous study in the literature, results compatible with our study when AA was evaluated histopathologically and using CT scans ⁽²²⁾.

In the studies, the diagnostic sensitivity and selectivity of USG performed by applying gradual pressure on the right iliac fossa have ranged between 75-90% and 86-100%, respectively.

The main advantages of USG are its low cost, lack of exposure to ionizing radiation (especially in pregnant women and children), its non-invasiveness, no need for patient preparation, and use of contrast media. The disadvantages include being dependent on the person performing it, inability of retrospective examination, inability to perform optimally due to some problems caused by the patient (excessive abdominal fat mass, too much intestinal gas etc.) or inability to visualize the appendix ^(18,20). Unlike the literature, the diagnostic sensitivity and selectivity of USG were found to be quite low in our study (71.5% and 4.3%, respectively). In a similar study, the diagnostic sensitivity and specificity of USG were found to be low compared to our study ⁽²¹⁾. In a retrospective study on appendicitis from Turkey, the diagnostic sensitivity of USG was low similar to our study, unlike the literature, and the specificity was high compared to our study (61% and 75%, respectively). Because USG is a relative test, its reliability should always be questioned. The reason for the results of our study is thought to be due to the fact that emergency USG is not performed by specialist staff, but is performed in the form of service procurement, and the patient intensity is excessive. For these reasons, the reliability of the emergency USG service is always questioned. In addition, the reason for such low selectivity is that these statistics are not made with patients presenting to the emergency department with abdominal pain, but with patients who were operated.

Based on the literature data, it is seen that the frequency of CT use in the diagnosis of AA has started to increase. However, we have difficulty in deciding on the use of CT as the first choice due to the reasons

such as its higher cost, time spent during preparation phase and scanning procedure, requirement for contrast media, and its adverse effects as contrast nephropathy and allergic reactions ⁽¹⁹⁾.

We believe that leukocyte counts, relevant inflammatory markers, results of USG and CT, especially along with clinical findings, should be used to support the surgeon in the diagnosis. When deciding on a laparotomy in AA, the surgeon should see and interpret all examination results, evaluate the patient with clinical findings, and use his/her experience and foresight.

The most important limitation of this study is that the results cannot be generalized. Because the data of the patients who were admitted to the emergency department of a hospital and underwent laparotomy with the preliminary diagnosis of AA were collected retrospectively. Moreover, since the study was conducted retrospectively and did not include all patients with abdominal pain, the data of patients who were admitted to the emergency department with abdominal pain and whose AA diagnosis was excluded by follow-up and examinations could not be evaluated. This results in statistically weaker calculation of the diagnostic sensitivity, selectivity, positive and negative predictive values of imaging and laboratory tests used during the diagnostic process.

CONCLUSION

In conclusion, the diagnostic sensitivity of non-contrast CT in AA was found to be higher than that of leukocyte count, neutrophil percentage and CRP elevation. Although USG appears to be in the first preference as an imaging test, the diagnostic sensitivity of USG was found to be lower than that of leukocyte count. As the diagnostic value of USG depends on the experience of the performer and the structural characteristics of the patient, it should only be considered as an auxiliary diagnostic tool by the surgeon. Especially in the presence of leukocytosis and strong clinical suspicion, either further examination (such as CT) should be performed or the laparotomy threshold should be kept low in order to strengthen the diagnosis.

High sensitivity of non-contrast CT compared to

other imaging techniques comes to the fore as an auxiliary diagnostic tool in making diagnosis. It can be considered as the first choice instead of contrast-enhanced CT in patients who are thought to have AA in order to reduce the side effects of contrast media.

Ethics Committee Approval: Approval was obtained from the Ethics Committee of the Ministry of Health Istanbul Health Sciences University Kanuni Sultan Süleyman Training and Research Hospital. (2019/03/74).

Conflict of Interest: There is no conflict of interest between the authors.

Funding: This research received no specific grant from any funding agency.

Informed Consent: Informed consent was obtained from all patients included in the study.

REFERENCES

1. Perry JP, et al. Diagnostic performance of multidetector computed tomography for suspected acute appendicitis. *Annals of Internal Medicine* 2011;154(12):789-96. <https://doi.org/10.7326/0003-4819-154-12-201106210-00006>
2. Aneel B, et al. Acute appendicitis: modern understanding of pathogenesis, diagnosis, and management. *The Lancet* 386.10000 2015;1278-87. [https://doi.org/10.1016/S0140-6736\(15\)00275-5](https://doi.org/10.1016/S0140-6736(15)00275-5)
3. Andy P. Diagnosis of acute appendicitis. *International Journal of Surgery* 2012;10(3):115-9. <https://doi.org/10.1016/j.ijssu.2012.02.006>
4. Hale DA, Molloy M, Richard HP, Pearl R, Schutt DC, Jaques DP. Appendectomy A contemporary appraisal. *Ann Surg.* 1997;225:252-61. <https://doi.org/10.1097/0000658-199703000-00003>
5. Steven LL, Alicia JW, Hung SH. Computed tomography and ultrasonography do not improve and may delay the diagnosis and treatment of acute appendicitis. *Arch Surg.* 2001;136:556-62. <https://doi.org/10.1001/archsurg.136.5.556>
6. Deutsch A, Leopold GR. Ultrasonic demonstration of the inflamed appendix: Case report. *Radiology* 1981;140:163-4. <https://doi.org/10.1148/radiology.140.1.6941334>
7. Puylaert JBCM. Acute appendicitis: Ultrasound evaluation using graded compression. *Radiology.* 1986;158:355-60. <https://doi.org/10.1148/radiology.158.2.2934762>
8. Leite PN, Pereira JM, Cunha R, Pinto P, Sirlin C. Computed tomography evaluation of appendicitis and its complications: Imaging techniques and key diagnostic findings. *Am J Roentgenol.* 2005;185:406-17. <https://doi.org/10.2214/ajr.185.2.01850406>
9. Ashraf K, Ashraf O, Bari V, Rafique MZ, Usman MZ, Chisti I. Role of focused appendiceal computed tomography in clinically equivocal acute appendicitis. *JPMA* 2006; 56:200-203.
10. Hardin MD. Acute apandicitis. Review and update. *Am Fam Physician.* 1999;60:2027-34.
11. Addiss DG, Shaferr N, Fowler BS, Tauxe RV. The epidemiology of appendicitis and appendectomy in the United States. *Am J Epidemiol.* 1990;132(5):910-25. <https://doi.org/10.1093/oxfordjournals.aje.a115734>
12. Yu CW, et al. Systematic review and meta-analysis of the diagnostic accuracy of procalcitonin, C-reactive protein and white blood cell count for suspected acute appendicitis. *British Journal of Surgery.* 2013;100(3):322-9. <https://doi.org/10.1002/bjs.9008>
13. Birnbaum BA, Wilson SR. Appendicitis at the millennium. *Radiology.*2000 ;215(2):337-48. <https://doi.org/10.1148/radiology.215.2.r00ma24337>
14. Graffeo CS, Counselman FL. Appendicitis. *Emerg Med Clin North Am.* 1996;14(4):653-71. [https://doi.org/10.1016/S0733-8627\(05\)70273-X](https://doi.org/10.1016/S0733-8627(05)70273-X)
15. Köksal H, Uysal B, Sarıbabıckı R. Acute appendicitis experience of a state hospital. *Akademik Acil Tıp Dergisi* 2010;9(1): 41-4.
16. Lai CY, Leung YK, Graham CA. Could C-reactive protein be a potential biomarker of complicated acute appendicitis?. *Hong Kong Journal of Emergency Medicine* 2014;21(6):354-60. <https://doi.org/10.1177/102490791402100603>
17. Yokoyama S, Takifuji K, Hotta T, Matsuda K, Nasu T, Nakamori M, et al. C-reactive protein is an independent surgical indication marker for appendicitis: a retrospective study. *World J Emerg Surg.* 2009;31(4):36. <https://doi.org/10.1186/1749-7922-4-36>
18. Bulent D, et al. New parameter in diagnosis of acute appendicitis: platelet distribution width. *World Journal of Gastroenterology* 2015;21(6):1821. <https://doi.org/10.3748/wjg.v21.i6.1821>
19. Celep B et al. Akut AA tanısında bilgisayarlı tomografinin yeri. *Bozok Tıp Dergisi* 2014;4(3):29-33.
20. Coursey, Courtney A, et al. Making the diagnosis of acute appendicitis: do more preoperative CT scans mean fewer negative appendectomies? A 10-year study. *Radiology.* 2010;254(2):460-8. <https://doi.org/10.1148/radiol.09082298>
21. Franke C, Böhner H, Yang Q, Ohmann C, Röher HD, Acute Abdominal Pain Study Group. Ultrasonography for diagnosis of acute appendicitis: Results of a prospective multicenter trial. *World Journal of Surgery* 1999;23(2):141-6. <https://doi.org/10.1007/PL00013165>
22. Hershko DD, Sroka G, Bahouth H, Ghersin E, Mahajna A, Krausz MM. The role of selective computed tomography in the diagnosis and management of suspected acute appendicitis. *Am Surg.* 2002;68(11):1003-7.