

Effects of Aqueous Artichoke (*Cynara scolymus*) Leaf Extract on Hepatic Damage Generated by Alpha-Amanitine ^[1]

Mustafa Bahadır KAYMAZ ¹  Fatih Mehmet KANDEMİR ² Esra PAMUKÇU ³
Yesari ERÖKSÜZ ⁴ Necmi ÖZDEMİR ⁵

^[1] This study had been presented at VII. National Congress of Veterinary Biochemistry and Clinical Biochemistry Congress, 28-30 May 2015, Samsun-Turkey

¹ Department of Pharmacology, Faculty of Pharmacy, University of Inonu, TR-44280 Malatya - TURKEY

² Department of Biochemistry, Faculty of Veterinary Medicine, University of Ataturk, TR-25240 Erzurum - TURKEY

³ Department of Statistics, Faculty of Science, University of Firat, TR-23200, Elazig - TURKEY

⁴ Department of Pathology, Faculty of Veterinary Medicine, University of Firat, TR-23200 Elazig - TURKEY

⁵ Department of Biochemistry, Faculty of Veterinary Medicine, University of Firat, TR-23200 Elazig - TURKEY

Article Code: KVFD-2016-16094 Received: 09.05.2016 Accepted: 25.07.2016 Published Online: 27.07.2016

Citation of This Article

Kaymaz MB, Kandemir MF, Pamukcu E, Eröksüz Y, Özdemir N: Effects of aqueous artichoke (*Cynara scolymus*) leaf extract on hepatic damage generated by alpha-amanitine. *Kafkas Univ Vet Fak Derg*, 23, 155-160, 2017. DOI: 10.9775/kvfd.2016.16094

Abstract

Approximately 90% of mushroom poisoning deaths in the world is caused by types of *Amanita phalloides*. Alpha-amanitine has a bicyclic octapeptide structure, which is the main structure responsible for these poisoning cases. In the present study, it was aimed to investigate effects of leaf extracts with artichoke extract on this toxicity. In the study, 28 male rats of Sprague-Dawley species were randomized to 4 groups. The groups were designed as control; receiving serum physiological solution of 0.1 mL intraperitoneally (ip), alpha-amanitine; receiving 3 mg/kg single dose ip, artichoke leaf extract; receiving 1.5 g/kg orally for 14 d, and treatment group, receiving alpha-amanitine 3 mg/kg single dose ip+artichoke leaf extract 1.5 g/kg orally for 14 d. It was determined that alpha-amanitine increased hepatic malondialdehyde (MDA) levels, and decrease superoxide dismutase (SOD), glutathione peroxidase (GSH-Px), catalase (CAT) activities with decreasing glutathione (GSH) levels. The supplementation with extract with artichoke, decreased MDA levels, it improved antioxidant parameters, and histopathological findings, so it was decided that extract with artichoke juice might be beneficial in alpha-amanitine related hepatic damage.

Keywords: Artichoke, Alpha-Amanitine, *Amanita phalloides*, Antioxidant, Hepatotoxicity

Alfa-Amanitin İle Oluşturulmuş Karaciğer Hasarı Üzerine Enginar (*Cynara scolymus*) Sulu Yaprak Ekstresinin Etkileri

Özet

Dünyada mantar zehirlenmelerine bağlı ölümlerin yaklaşık 90%'ına *Amanita phalloides* türü mantarlar neden olmaktadır. Alfa-amanitin, bisiklik oktapeptid yapıda bu zehirlenmelerden sorumlu ana yapıdır. Bu çalışmada, enginar sulu yaprak ekstresinin oluşturulan toksite üzerine etkilerinin araştırılması amaçlanmıştır. Çalışmada, Sprague-Dawley cinsi 28 erkek rat rastgele 4 gruba ayrıldı. Gruplar, kontrol grubu (serum fizyolojik 0.1 mL ip), alfa-amanitin (3 mg/kg tek doz ip), enginar yaprak ekstresi (oral 1.5 g/kg, 14 gün) ve tedavi uygulanan (alfa-amanitin 3 mg/kg tek doz ip+ enginar yaprak ekstresi oral 1.5 g/kg, 14 gün) olmak üzere belirlendi. Alfa-amanitinin karaciğer malondialdehit (MDA) düzeyini arttırdığı, süperoksit dismutaz (SOD), glutatyon peroksidaz (GSH-Px), katalaz (CAT) aktiviteleri ile glutatyon (GSH) düzeyini düşürdüğü tespit edilmiştir. Enginar sulu yaprak ekstresi takviyesinin MDA seviyesini düşürürken antioksidan parametrelerde ve histopatolojik bulgularda iyileşmeye neden olduğu saptanmıştır. Çalışma sonucunda, alfa-amanitin kaynaklı karaciğer hasarına karşı enginarın sulu ekstresinin kullanımının, tedaviye destek olarak kullanılabileceği düşünülmektedir.

Anahtar sözcükler: Enginar, Alfa-Amantin, Antioksidan, *Amanita phalloides*, Hepatotoksisite

INTRODUCTION

Of approximately 1.5 million types of mushrooms distributed worldwide, 2000 types are toxic, and the

ones causing mortality have cyclopeptide structures. *Amanita* species are the mushrooms containing these structures and that are responsible for 90% of death cases worldwide ^[1].



İletişim (Correspondence)



+90 533 4329409



kaymazbahadir@gmail.com

Among amanita species, the most common death cases are reported with *A. phalloides* mushroom. It is known that approximately 50 g of this type is lethal. It contains octapeptides such as amanitines and phalloidines, which are the main sources of toxicity and can dissolve in liquid environment, but resistant to high temperatures and against digestive enzymes. It has been reported that lethal doses for amanitines are 0.1 mg/kg, and for phalloidines are 1-2 mg/kg [2-4].

It has been indicated that the primary cause of toxicity in amanita species alpha-amanitine which exists among amanitine derivatives. Alpha-amanitine is absorbed and distributed to tissues within 1.5-2 h in the body. As it is not bound to circulating proteins, toxicity is rapid and severe. Mechanism of toxicity acts through binding of alpha-amanitine to RNA polymerase II enzyme, and inhibiting of DNA transcription. Therefore, it is reported that necrosis is observed in hepatocytes, in which excessive protein synthesis is performed [5].

Currently, there is no specific antidote present for *A. phalloides* intoxication. For treatment, supportive treatments such as gastric lavage, activated charcoal, and balancing liquid and electrolyte losses are performed. In addition to these, silybin, which is the active ingredient of intravenous crystallized penicillin G and *Silybum marianum* herb, is being performed. It has been shown in different studies that administration of silybin may be lifesaving [6,7].

Artichoke (*Cynara scolymus*) is a vegetable, which is grown in countries with borders to the Mediterranean Sea, like our country, and is known to be rich in antioxidants and has preserving effects on liver. It has cynarine and chlorogenic acid which are caffeoylquinic acid derivatives, and flavonoids (luteolin, apigenin) in its structure. It has been reported in the literature that leaves of artichoke may be beneficial for liver intoxication, and it may also be antimicrobial and has cholesterol-lowering effects. Additionally, it has been reported that it can prevent hepatic damage by its strong antioxidant structure. Because of its peppery taste, and dissolution capacity of its active substances in water, liquid extracts of dried leaves and teas are being used medically [8-11].

In the present study, it was aimed to investigate effects of artichoke that was endemically grown in our country, on hepatic toxicity.

MATERIAL and METHODS

The study dated 04.04.2013 was performed, with 45 numbered countenance, providing approval of the Local Ethics Committee for Experimental Animal at Firat University Experimental Research Center (FUDAM). The study was performed on 28 male Sprague-Dawley species rat, which were 8 weeks old, and body weights were between 200 and 220 gram. Before and during the study, all rats were

fed in 12 h light and 12 h darkness photo periods at 22-24°C fixed room temperature with standard rat feed *ad libitum*. 28 rats were randomized to four groups, so that each group was consisted of seven rats.

Alpha-amanitine, used in the study, has been supplied at least 95% purity from AppliChem (ABD) company. Artichoke leaf extract was taken from Arı Engineering (Ankara). Extracts 6.5% caffeoylquinic acid (3.7% monocaffeoylquinic acid and 2.6% dicaffeoylquinic acid named of cynarine) that is containing is cited from the company. Both of these materials can dissolve in water.

The first group, as the control group, received serum physiological solution (0.1 mL) ip infusion. The second group received alpha-amanitine was administered at 3 mg/kg in single ip infusion. The third group received orally liquid form of artichoke leaf extract at 1.5 g/kg dose for 14 d. The last group received single dose of 3 mg/kg alpha-amanitine ip and then they were given liquid form of artichoke leaf extract at 1.5 g/kg dose for 14 d. All groups were decapitated under anesthesia at the end of day 14. Toxicity formation and administration route of the extract were defined according to previous studies in the literature [12-14].

Obtained hepatic samples were washed by 0.9% NaCl, and stored at -80°C until the day of study. Tissue homogenization was performed in a Teflon homogenizer with 1.15% KCl tamponade at 1:10 (w/v) ratio.

Following the euthanasia, some of samples were embedded in %10 formalin solution, and then they were passed through alcohol and xylol series and embedded in paraffin blocks. The blocks were cut at 5-µm thickness by using microtome, and prepared samples were stained by hematoxylin-eosin and they were evaluated under the light microscope for histopathological findings.

Hepatic MDA levels were determined according to method performed by Placer et al. [15], SOD activity was measured according to the method performed by Sun et al. [16], CAT activity was measured according to the method performed by Aebi [17], GSH-Px activity was measured according to the method performed by Matkovic et al. [18], and GSH level was determined according to the method performed by Sedlak et al. [19].

Statistically Analysis

In order to test statistical significant differences between intergroup means of MDA, SOD, GSH, GSH-Px and CAT values, One-Way Variation Analysis was performed. Groups were independent and measurement levels were quantitative. Levene homogeneity test and Shapiro-Wilk normality test in small samples were employed to determine whether one-way variation analysis could satisfy other assumptions.

Homogeneity assumption was satisfied between groups for all variables, and normality assumption was satisfied for all other variables except for MDA variable. When homogeneity was preserved between the groups, F testing was not extensively affected from deviation from normality assumption [20]. Therefore, performing one-way variation analysis was applicable. As the result of one-way variation analysis all differences between groups were statistically significant for all variables ($P < 0.001$). Scheffe Test, which was one of the most conservative tests in errors of multiple comparisons, was used to determine which groups caused intergroup differences.

RESULTS

The results are shown in *Table 1*. *Fig. 1* shows the mean values between groups for each variable. Using the same letters indicate that there is no difference among variable in one line, whereas using different letters indicate that there are differences between groups.

When MDA means were compared between the groups, artichoke extract using group increased MDA level when compared to the control group. Increasing MDA values by administration of alpha-amanitine were nearly returned those observed in the control group by administration of artichoke treatment ($P < 0.05$). While SOD activities of hepatic tissues were observed closer between control and artichoke receiving groups, it was observed that the activity lowered by administration of alpha-amanitine was increased after administration of artichoke extract ($P < 0.05$). GSH levels were determined very different in four groups. While GSH level of the group receiving artichoke extract was higher than the control group, GSH levels were very decreased by administration of alpha-amanitine, but they were increased to the values of the control group after artichoke extract administration. When compared with the control group, artichoke extract group had differences only in MDA and GSH variables. While alpha-amanitine caused differences in all variables, alpha-amanitine+artichoke group had differences in SOD, GSH-Px and CAT values.

Histopathological Findings

In trial groups (alpha-amanitine and alpha-amanitine+

artichoke leaf extract receiving groups) various degrees of degenerations were observed in all hepatic samples (hydropic degeneration, fat degeneration, and blurred swelling), and prominent changes with single cell necrosis were observed. In the control group, no pathological change was observed. No necrotic areas or inflammatory changes were observed in both trial groups.

DISCUSSION

Currently as there is no antidote for alpha-amanitine, some treatment methods about elimination and blocking the toxic substance into cells are being performed. It was reported that silybin which was derived from *Silybum marianum* herb, and was water-soluble substance of silimarine derivative, decreased entrances of amatoxins into cells, so that they showed hepatoprotective effect [21].

Artichoke vegetable, which was used in our study, is still being used as a medication for liver and gallbladder. Cynarine, which is the biological active substance in artichoke is present in all of the vegetable, but mainly concentrated in its leaves. Therefore, artichoke containing drugs and extracts are generally prepared as liquid extracts from the leaves [22].

Cynarine, a component of phenolic acid, is a substance with hepatoprotective and regenerative effects. It is the main derivative of caffeoylquinic acid and stated that antiatherosclerotic, antioxidative, and cholesterol-lowering effects. Also cynarine was reported that it showed cholagogue and chlorotic effects, and it provided hepatic detoxification by bile secretion [23]. According to study on cell culture made by Gezer et al. [24], cell culture treatment of cancerous human cells in cynarine gave an affirmative answer, increases survival rates, decreased of oxidative stress. In 1987, Adzet et al. [25] reported in their study that they observed effects of cynarine in hepatic toxicity induced by carbon tetra chloride (CCl_4), and it had a hepatoprotective effect. In our study, hepatoprotective effects and oxidative results might based on cynarine was main and effective structure of caffeoylquinic acid derives.

Majeed et al. [26] analysed anti-inflammatory activities of artichoke leaf extract obtained with different methods.

Table 1. Scheffe Test results

Tablo 1. Scheffe Test sonuçları

Group/ Variable	Control	Artichoke	Alpha-amanitine	Aa+artichoke
MDA (nmol/g)	121.82±12.67 (a)	68.23±6.29 (b)	427.07±13.20 (c)	122.15±11.49 (a)
SOD (units/mg protein)	20.99±2.52 (a)	21.22±2.26 (a)	12.34±1.68 (b)	16.37±1.38 (c)
CAT (k/mg protein)	2.47±0,30 (a)	2,42±0,31 (a)	1.39±0,38 (b)	1.91±0,23 (c)
GSH-Px (units/mg protein)	3.39±0,37 (a)	3,63±0,48 (a)	1,01±0,19 (b)	2,08±0,24 (c)
GSH (nmol/g)	6.85±0.37 (a)	7.61±0.45 (b)	5.55±0.34 (c)	6.89±0.59 (a)

(a-c): Different superscript letters in same row indicate statistical differences

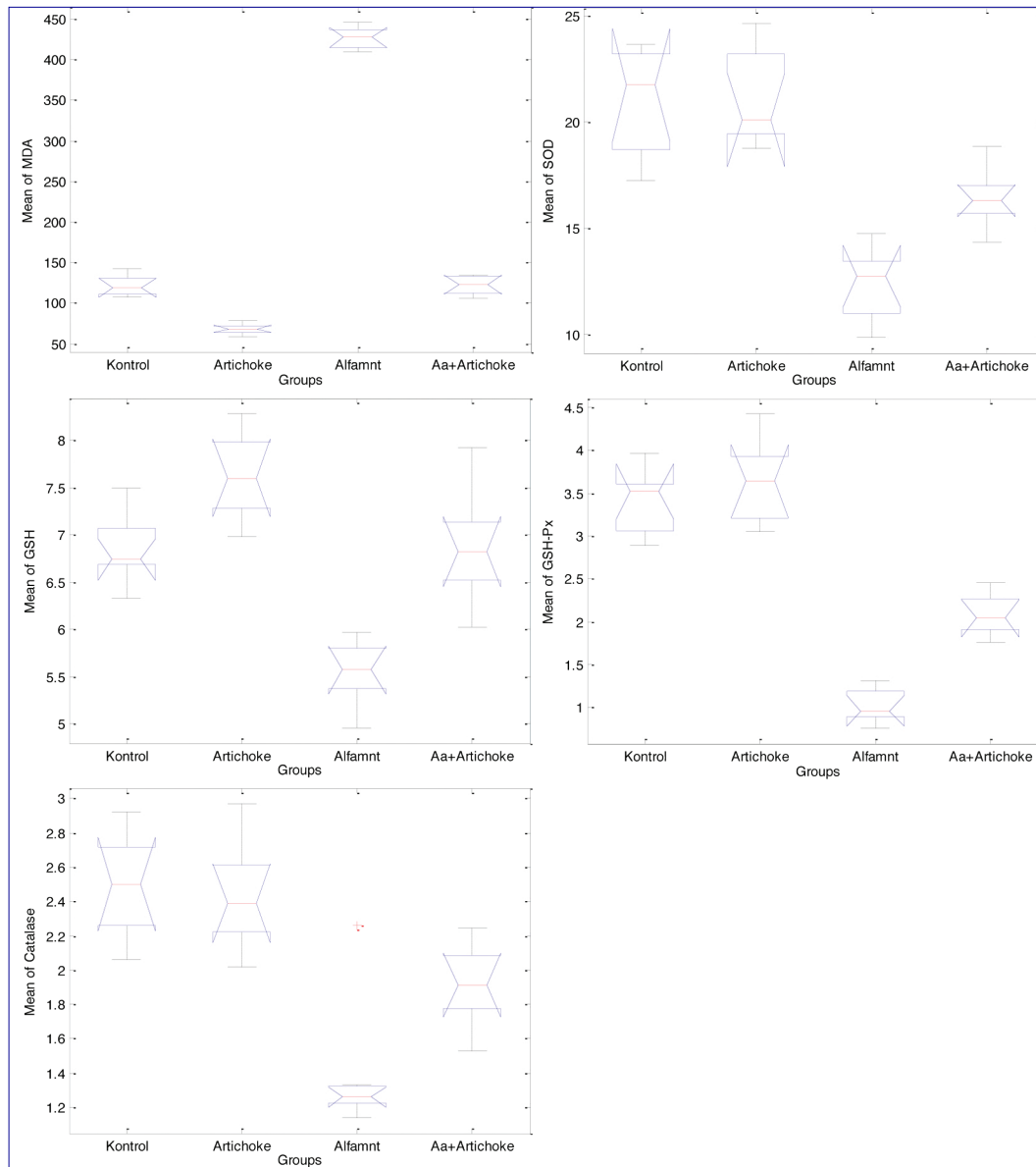


Fig 1. The mean values of all variables for the groups

Şekil 1. Tüm değişken grupların ortalama değerleri

They got close result from dexamethasone and diclofenac sodium group, chosen as positive control group, and got meaningful results from negative control implemented dimethylsulfoxide. Today's current treatment of caused from Alpha-amanitine, immune-suppressive and anti-inflammatory medicines are used as supportive medicines. According to Majeed et al.^[26], supportive effect of artichoke leaf extract, used in our study, has shown that the parallelism.

In another study, Colak et al.^[27] analyzed the artichoke's regenerated property on liver. CCl_4 induced liver damage studied by Colak et al.^[27], applying artichoke leaf extract demonstrates that as like in our study also at antioxidant parameters how to reduce inflammation caused by to heal.

Antonio Jimenez-Escrig et al. performed a study in

which they extracted polyphenols form active substances of artichoke, and they tried them on rats. They reported that there were significant differences in SOD, GSH, GSH-Px and 2-aminoadipic semi aldehyde, which is a protein oxidation parameter, when compared to the control group^[28].

Küçükgergin et al.^[29] reported that hepatic and cardiac oxidative stress damage, which was caused in rats fed by high cholesterol diet, and caused by high cholesterol, could be decreased by artichoke leaf extract.

Under the light of these results, we aimed at determining whether artichoke leaf extract would be effective against *A. phalloides* intoxication that had no present antidote. As the results of our trial, it was observed that alpha amantadine caused oxidative stress and damage in all groups significantly. Significant changes were determined

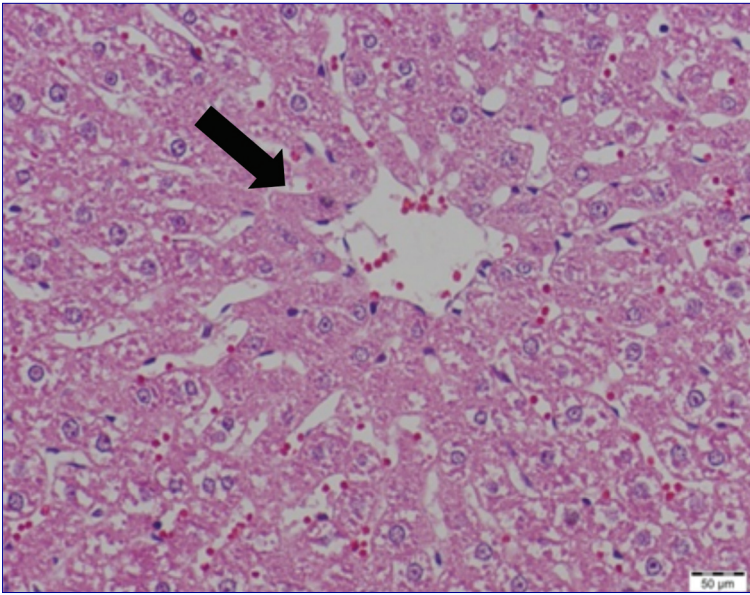


Fig 2. Mild-moderate blurred swelling in centrilobular area of liver (*arrow*) (alpha-amanitine+artichoke leaf extract receiving group)

Şekil 2. Karaciğerde sentrolobüler (*ok*) bölgede hafif- orta şiddette bulanık şişkinlik (alfa-amanitin+enginar yaprak ekstresi verilen grup)

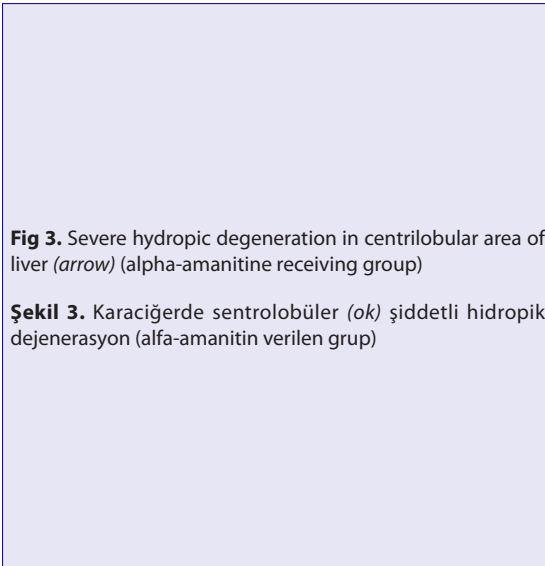
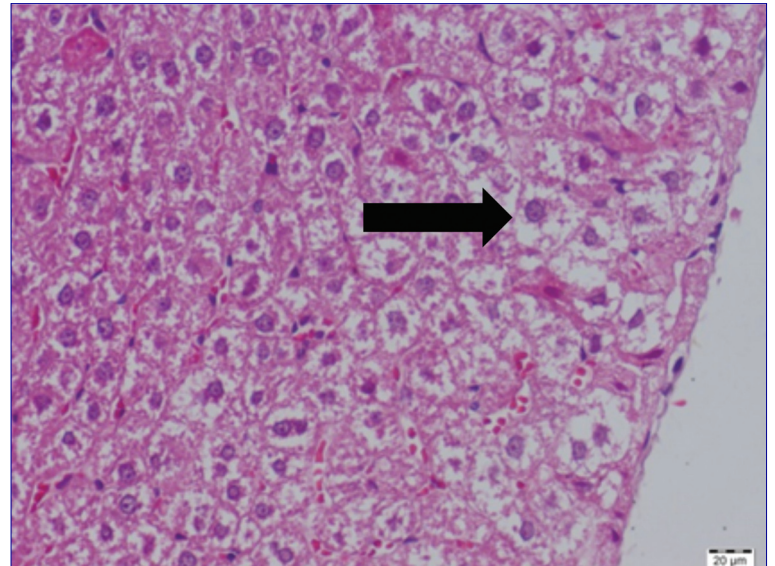


Fig 3. Severe hydropic degeneration in centrilobular area of liver (*arrow*) (alpha-amanitine receiving group)

Şekil 3. Karaciğerde sentrolobüler (*ok*) şiddetli hidropik dejenerasyon (alfa-amanitin verilen grup)



in all of investigated antioxidant parameters between alpha-amanitine and alpha-amanitine+artichoke leaf extract groups, so it was decided that the extract might have positive effects on toxicity, and it might have a protective effect on hepatocytes. Moreover, significant decreases observed in MDA and GSH levels in control and only in artichoke extract groups could indicate the antioxidant effect of artichoke. Also, statistical insignificances in especially MDA and GSH levels between control and alpha-amanitine+artichoke groups suggested the idea that artichoke might recover negative effects of the toxin. SOD, GSH-Px and CAT levels were significantly increased in alpha-amanitine group when compared with the control group, and they were significantly decreased after administration of the extract. This condition has suggested that artichoke may be a helpful treatment in this intoxication.

In conclusion, it is determined that liquid leaf extract

of artichoke, which is endemically grown in our country, and had the antioxidant effect, has a healing effect on alpha-amanitine induced hepatic toxicity, and it has been decided that using artichoke as a supportive treatment will be beneficial in cases with alpha-amanitine induced hepatic toxicity.

REFERENCES

1. Flomenbaum NE, Goldfrank LR, Hoffman RS, Howland MA, Lewin NA, Nelson LS: Mushrooms. In, Goldfrank LR (Ed): Goldfrank's Toxicologic Emergencies. 8th edn., 1564-1569, Mc Graw-Hill Company, New York, 2006.
2. Vural N: Doğal Kaynaklı Zehirler. In, Vural N (Ed): Toksikoloji. 73th edn., 610-623, Ankara Üniv Ecz Fak Yayınları, Ankara, 1996.
3. Klein AS, Hart J, Brems JJ, Goldstein L, Lewin K, Busuttill RW: Amanita poisoning treatment and the role of liver transplantation. *Am J Med*, 86, 187-193, 1989. DOI: 10.1016/0002-9343(89)90267-2
4. Himmelmann A, Mang G, Schnorf-Huber S: Lethal ingestion of stored Amanita phalloides mushrooms. *Swiss Med Wkly*, 131, 616-617, 2001.

- 5. Nguyen VT, Giannoni F, Dubois MF, Seo SJ, Vigneron M, Kédinger C, Bensaude O:** *In vivo* degradation of RNA polymerase II largest subunit triggered by alpha-amanitin. *Nucleic Acids Res*, 24, 2924-2929, 1996. DOI: 10.1093/nar/24.15.2924
- 6. Goldfrank LR, Flamenbaum NE, Lewin NA, Weisman RS, Hawland MA, Hoffman RS:** Mushrooms: Toxic and hallucinogenic. In: Goldfrank LR (Ed): *Goldfrank's Toxicologic Emergencies*. 6th edn., 1207-1220, Mc Graw-Hill Company, New York, 1998.
- 7. Garcia J, Costa VM, Carvalho A, Baptista P, Pinho PG, Bastos ML, Carvalho F:** Amanita phalloides poisoning: Mechanisms of toxicity and treatment. *Food Chem Toxicol*, 86, 41-55, 2015. DOI: 10.1016/j.fct.2015.09.008
- 8. Llorach R, Espin JC, Tomas-Barberan FA, Ferreres F:** Artichoke (*Cynara scolymus* L.) byproducts as a potential source of health-promoting antioxidant phenolics. *J Agr Food Chem*, 50, 3458-3464, 2002. DOI: 10.1021/jf0200570
- 9. Aktay G, Deliorman D, Ergun E, Ergun F, Yesilada E, Cevik C:** Hepatoprotective effects of Turkish folk remedies on experimental liver injury. *J Ethnopharmacol*, 73, 121-129, 2000. DOI: 10.1016/S0378-8741(00)00286-5
- 10. Speroni E, Cervellati R, Govoni P, Guizzardi S, Renzulli C, Guerra MC:** Efficiency of different *Cynara scolymus* preparations liver complaints. *J Ethnopharmacol*, 86, 203-211, 2003. DOI: 10.1016/S0378-8741(03)00076-X
- 11. Tanker M, Tanker N:** Flavonozitler. In: Tanker M, Tanker N (Eds): *Farmakognozi*. 218-219, Ankara Üniversitesi Basımevi, Ankara, 1991.
- 12. Bergö M, Wu G, Ruge T, Olivecrona T:** Down-regulation of adipose tissue lipoprotein lipase during fasting requires that a gene, separate from the lipase gene, is switched on. *J Biol Chem*, 277, 11927-11932, 2002. DOI: 10.1074/jbc.M200325200
- 13. Wieland T, Faulstich H:** Amatoxins, phallotoxins, phallolysin, and antamanide: The biologically active components of poisonous *Amanita mushrooms*. *CRC Crit Rev Biochem*, 5, 185-260, 1978. DOI: 10.3109/10409237809149870
- 14. Mehmetcik G, Ozdemirler G, Toker NK, Cevikbas U, Uysal M:** Effect of pretreatment with artichoke extract on carbon tetrachloride-induced liver injury and oxidative stress. *Ex Toxicol Pathol*, 60, 475-480, 2008. DOI: 10.1016/j.etp.2008.04.014
- 15. Placer ZA, Cushman L, Johnson BC:** Estimation of products of lipid peroxidation (malonyl dialdehydes) in biological fluids. *Anal Biochem*, 16, 359-364, 1966. DOI: 10.1016/0003-2697(66)90167-9
- 16. Sun Y, Oberley WL, Li Y:** A simple method for clinical assay of superoxide dismutase. *Clin Chem*, 34, 497-500, 1988.
- 17. Aebi H:** Catalase *in vitro*. *Methods Enzymol*, 105, 121-126, 1984. DOI: 10.1016/S0076-6879(84)05016-3
- 18. Matkovic B, Szabo L, Varga LS:** Determination on enzyme activities in lipid peroxidation and glutathione pathways. *Laboral Diagn*, 15, 248-249, 1988.
- 19. Sedlak J, Lindsay RH:** Estimation of total, protein-bound, and nonprotein sulfhydryl groups in tissue with Ellman's reagent. *Anal Biochem*, 25, 192-205, 1968. DOI: 10.1016/0003-2697(68)90092-4
- 20. Ferguson GA, Takane Y:** Repeated Measurements and Other Designs. In: Ferguson GA, Takane Y (Eds): *Statistical Analysis in Psychology and Education*. 6th edn., 347-390, McGraw-Hill Ryerson Ltd, Montreal, 2005.
- 21. Enjalbert F, Rapior S, Soulé JN, Guillon S, Amouroux N, Cabot C:** Treatment of amatoxin poisoning: 20-year retrospective analysis. *J Toxicol Clin Toxicol*, 40, 715-757, 2002. DOI: 10.1081/CLT-120014646
- 22. Edwards SE, Heinrich M, Rocha I, Williamson ME:** Artichoke. In: Edwards SE (Ed): *Phytopharmacy: An Evidence-based Guide to Herbal Products*. 29-31, John Wiley&Sons Ltd, Oxford, 2015.
- 23. Ben-Hod G, Basnizki Y, Zohary D, Mayer AM:** Cynarin and chlorogenic acid content in germinating seeds of globe artichoke (*Cynara scolymus* L.). *J Genet Breed*, 46, 63-67, 1992.
- 24. Gezer C, Yücecan S, Rattanc SIS:** Artichoke compound cynarin differentially affects the survival, growth, and stress response of normal, immortalized, and cancerous human cells. *Turk J Biol*, 39, 299-305, 2015. DOI: 10.3906/biy-1407-67
- 25. Adzet T, Camarasa J, Carlos Laguna J:** Hepatoprotective activity of polyphenolic compounds from *Cynara scolymus* against CCl₄ toxicity in isolated rat hepatocytes. *J Nat Prod*, 50, 612-617, 1987. DOI: 10.1021/np50052a004
- 26. Majeed MF, Numan IT, Noori M:** Study the anti-inflammatory activity of artichoke (*cynara scolymus*) different extracts in experimental models of acute inflammation in rats. *Pharmacie Globale (IJCP)*, 6, 4-5, 2015.
- 27. Colak E, Ustuner MC, Tekin N, Colak E, Burukoglu D, Degirmenci I, Gunes HV:** The hepatocurative effects of *Cynara scolymus* L. leaf extract on carbon tetrachloride-induced oxidative stress and hepatic injury in rats. *Springerplus*, 5, 216, 2016. DOI: 10.1186/s40064-016-1894-1
- 28. Escrig AJ, Dragsted LO, Daneshvar B, Pulido R, Saura-Calixto F:** *In vitro* antioxidant activities of edible artichoke (*Cynara scolymus* L.) and effect on biomarkers of antioxidants in rats. *J Agric Food Chem*, 51, 5540-5545, 2003. DOI: 10.1021/jf030047e
- 29. Küçükgergin C, Aydın AF, Özdemirler-Erata G, Mehmetcik G, Toker NK, Uysal M:** Effect of artichoke leaf extract on hepatic and cardiac oxidative stress in rats. Fed on high cholesterol diet. *Biol Trace Elem Res*, 135, 264-274, 2010. DOI: 10.1007/s12011-009-8484-9