



A Case with Idiopathic Bilateral Multifocal Retinal Pigment Epithelium Detachment

Bilateral İdyopatik Multifokal Retina Pigment Epitel Dekolmanlı Bir Olgu

Mehmet Ragıp Ekmen

Malatya State Hospital, Ophthalmology Clinic, Malatya, Turkey

Abstract

A 47-year-old woman presented with near sight issues with 10/10 best corrected visual acuity in both eyes. The intraocular pressure was 14mmhg in right eye and 16mmhg in left eye. The slit-lamp examination showed a normal anterior chamber. The dilated fundus examination showed that there were cystic, hypopigmented, and swollen lesions in the both fovea. The patient did not have metamorphopsia. At the same time in serological tests performed on the patient did not develop any pathology. With no present systemic problem, the patient was diagnosed with idiopathic retina pigment epitel detachment at the end of examination with fluorecein anjiography and optical chorenence tomography.

Keywords: Idiopathic Retina Pigment Epitel Detachment; Fluorecein Anjiography; Optical Cohorence Tomography.

Öz

Göz polikliniğine yakını görememe şikayeti ile başvuran 47 yaşındaki bayan hastanın yapılan oftalmolojik muayenesinde en iyi düzeltilmiş görme keskinliği sağ gözde: 10/10, sol gözde 10/10' idi. Hastanın göz içi basınçları sırasıyla sağ:14 mmhg, sol: 16 mmhg 'idi. Biyomikroskopik muayenede her iki göz ön segment muayeneleri doğal görünümdeydi. Hastanın dilate fundus muayenesinde her iki foveada kistik ve yüzeyden hafif kabarık hipopigmente değişiklikler olduğu gözlemlendi. Hastanın metamorfopsi şikayeti yoktu. Aynı zamanda hastanın yapılan serolojik testlerinde herhangi bir patoloji saptanmadı. Sistemik herhangi bir problemi olmayan hastaya yapılan flöresein anjiografi (FA) ve optik kohorens tomografi (OCT) tetkikleri sonucunda, İdyopatik retina pigment epitel dekolmanı tanısı konuldu.

Anahtar Kelimeler: İdyopatik Retina Pigment Epitel Dekolmanı; Floresein Anjiografi; Optik Kohorens Tomografi.

Received/Başvuru: 17.06.2015
Accepted/Kabul: 28.06.2015

Correspondence/İletişim

Mehmet Ragıp EKMEN
Malatya Devlet Hastanesi Göz
Hastalıkları Kliniği, MALATYA,
TÜRKİYE
E-mail: mrekm.80@outlook.com

For citing/Atf için

Ekmen MR. A case with
idiopathic bilateral multifocal
retinal pigment epithelium
detachment. J Turgut Ozal Med
Cent 2016;23(1):111-3

DOI:10.5455/jtomc.2015.06.010

INTRODUCTION

Serous pigment epithelial detachment (PED) can be seen without any significant clinical or angiographic choroidal neovascularization. Developing without any systemic or ophthalmic causes at young ages (<50 years), PEDs is considered to be a variant of central serous chorioretinopathy (CSC) (1). According to another view, serous PEDs occur as a result of increased choroidal permeability secondary to choroidal ischemia (2, 3).

In this report, we aim to present the case of a patient who was admitted to our ophthalmology clinic with complaints of near sight and no systemic diseases, and diagnosed with idiopathic serous PED.

CASE REPORT

A forty-seven-year-old female patient was admitted to the clinic with near sightedness. The complete ophthalmic examination with Snellen visual acuity chart showed the best corrected acuity of 10/10 in both eyes and an intraocular pressure of 14 mmHg in the right eye and 16 mmHg in the left eye. The anterior segments of both eyes were normal in the biomicroscopic examination. The dilated funds examination revealed cystic, hypo-pigmented lesions with protuberant surface in the fovea in both eyes (Figure 1). The patient did not

have any metamorphopsia complaints. We evaluated the patient for systemic and serological components and applied immunological tests. The test results showed that the patient had negative anti TORCH and normal ASO and CRP. With no detected systemic diseases, the patient was scheduled for FA and OCT.

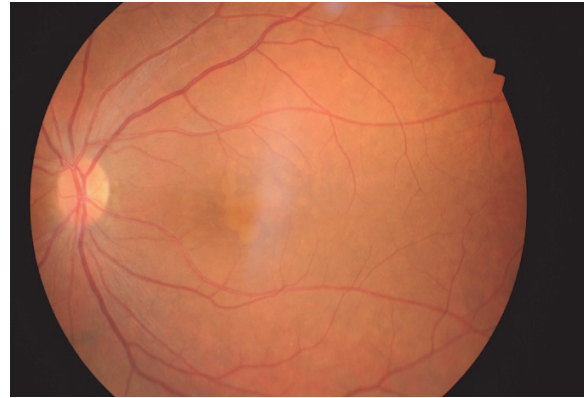

Figure 1. Hypo-pigmented, lobulated lesion in the fovea of the left eye.

The fluorecein angiography of the patient showed hyper-fluoresceined foci that had started in the early period and increased in the later period (Figures 2a, 2b).

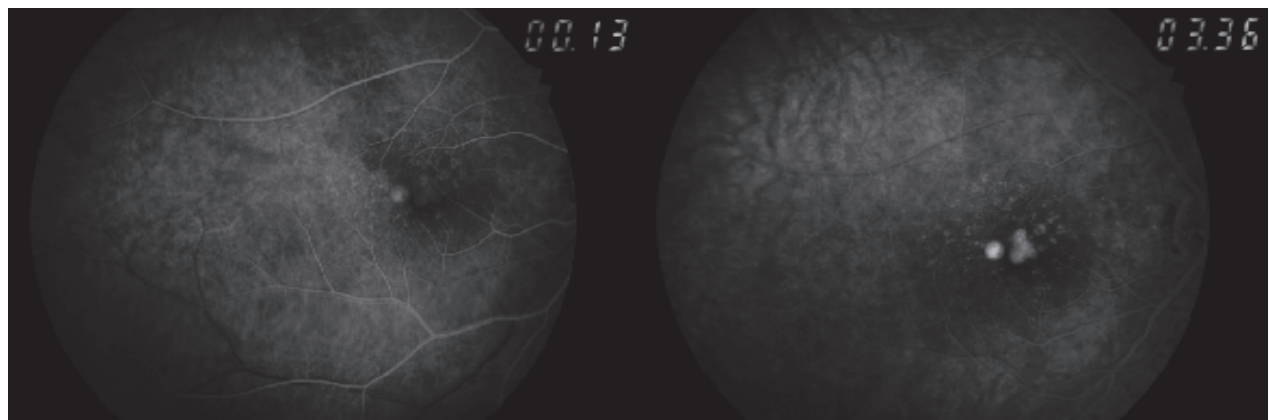


Figure 2a. Early and late FA findings of the right eye.

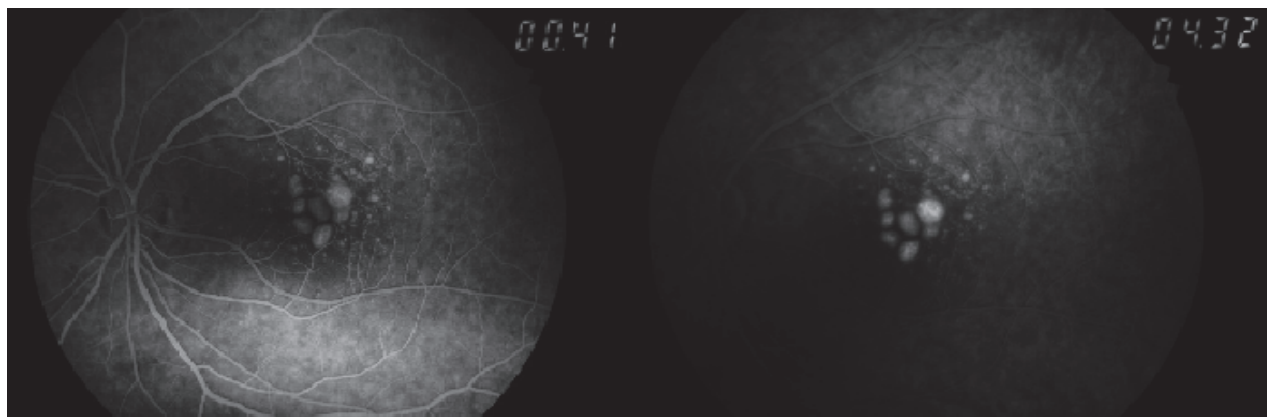
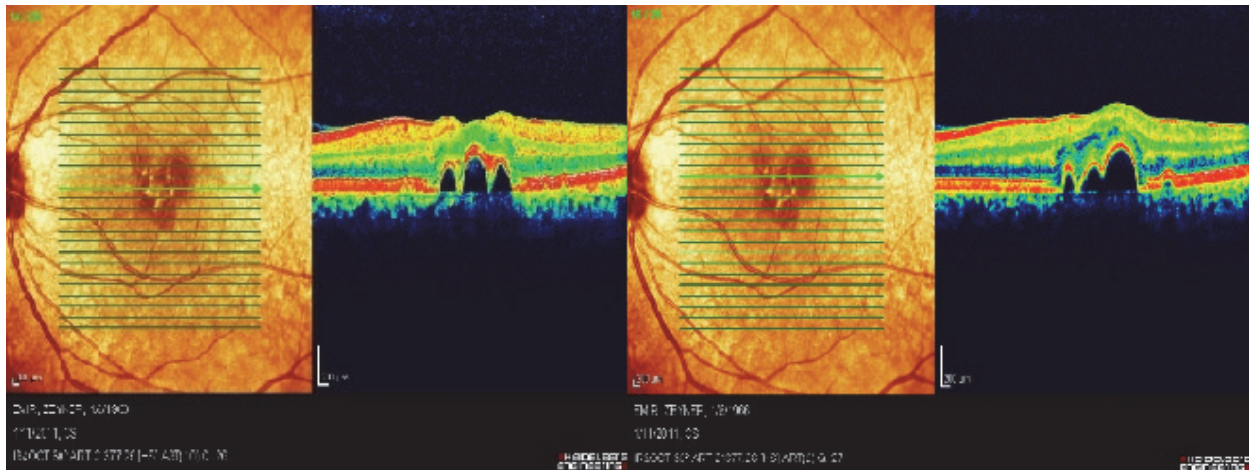


Figure 2b. Early and late FA findings of the left eye.

The OCT sections of the patient showed neighbouring serous PED areas in both fovea (Figures 3a, 3b).



Figures 3a and 3b. OCT results of the patient.

DISCUSSIONS

Serous detachment of the retinal pigment epithelium can be seen in healthy individuals as well (1). This case is either because of a variant of CSC (2) or of an increase in permeability in the choriocapillary layer (3, 4).

The PED was observed bilaterally in our case; considering the age of the patient and because there were no systemic diseases, we diagnosed our patient with idiopathic PED. This picture was thought to be a sequelae of a previous CSC. Close to the large PED areas in the OCT, there were smaller PED areas which made us think that the patient must have had CSC before (Figure 3b).

Nobel et al. have detected serous PEDs in the posterior retina pole in 5 middle-aged patients and diagnosed the patients with idiopathic PED when they failed to detect certain underlying causes (5).

In their case study of a patient with suspected neurosyphilis, Anan and Mushin have identified multifocal serous PED areas and concluded that this was related to permeability increase in the choriocapillary layer (6). In our case, we did not detect any serologic findings including syphilis.

Multifocal PED areas can be in certain numbers in various cases. The largest number of PED areas related to this is found in Japanese patients. In a seven-case series, researchers have identified more than 100 PED areas (7, 8). In our case, the number of PED areas was no more than 3 and these areas were connected to each other (Figures 3a-3b).

In this paper, our aim was to present the case of a disease-free young female patient with bilateral idiopathic multifocal PED which was identified by chance during routine outpatient visits.

REFERENCES

1. Gass JD, Bressler SB, Akduman L, Olk J, Caskey PJ, Zimmerman LE. Bilateral idiopathic multifocal retinal pigment epithelium detachments in otherwise healthy middle-aged adults: a clinicopathologic study. *Retina* 2005;25(3):304-10.
2. Giovanni A, Scassellati-Sforzolini B, D'Altobrando E, Mariotti C, Rutili T, Tittarelli R. Choroidal findings in the course of idiopathic serous pigment epithelium detachment detected by indocyanine green videoangiography. *Retina* 1997;17(4):286-93.
3. Uyama M, Matsunaga H, Matsubara T, Fukushima I, Takahashi K, Nishimura T. Indocyaninegreen angiography and pathophysiology multifocal posterior pigment epitheliopathy. *Retina* 1999;19(1):12-21.
4. Prunte C, Flammer J. Choroidal capillary and venous congestion in central serous chorioretinopathy. *Am J Ophthalmol* 1996;121(1):26-34.
5. Noble KG, Levitzky MJ, Carr RE. Detachments of the retinal pigment epithelium at the posterior pole. *Am J Ophthalmol* 1976;82(2):246-51.
6. Anand S and Mushin AS. Multifocal asymptomatic retinal pigment epithelial detachments in neurosyphilis *Eye* 2003;17(4):524-5
7. Koide K, Suto K, Hikoya A, Toshiba T, Hotta Y. Bilateral multifocal retinal pigment epithelial detachments associated with abnormal multifocal electroretinograms. *Jpn J Ophthalmol* 2009;53:546-63.
8. Murakami M, Kawakubo H, Yuzawa M, et al. Two cases of multiple retinal pigment epithelial detachments. *Jpn J Ophthalmol* 1995;37:73-81.