

## An Uncommon Presentation of a Common Benign Tumour

Elif Usturalı Keskin<sup>1</sup>, Emel Ebru Pala<sup>1</sup>, Ebru Çakır<sup>1</sup>, Cüneyt Eftal Taner<sup>2</sup>, Serhat Sarıkaya<sup>2</sup>,  
Fatih Keskin<sup>3</sup>

<sup>1</sup>İzmir Tepecik Research and Training Hospital, Pathology Clinic, İzmir, Turkey

<sup>2</sup>İzmir Ege Gynecology, Obstetrics, and Pediatrics Research and Training Hospital, Gynecology and Obstetrics  
Clinic, İzmir, Turkey

<sup>3</sup>Buca Maternity Ward and Children Hospital, Gynecology and Obstetrics Clinic, İzmir, Turkey

### Abstract

Lipom en yaygın benign mezenkimal yumuşak doku tümörüdür. Matür adipositlerden oluşur, daha sık obez hastalarda subkutan dokuda görülür. Subkutan lipom genellikle baş boyun bölgesi yerleşimlidir. Vulvar lipom oldukça nadirdir.

72 yaşında obez kadın hasta vulvada ağrısız şişlik şikayeti ile başvurdu. Fizik muayenede sağ vulvada yaklaşık 15 cm çaplı tek, yumuşak, mobil kitle palpe edildi. Eksize edilen materyal 13 cm çaplı fibröz kapsülle örtülü matür yağ dokusu görünümündeydi. Mikroskopik inceleme sonucu lipom tanısı konuldu.

Vulvar lipom benign klinik gidiş gösterir. Tedavi edilmezse büyük boyuta ulaşabilir. Malignite olasılığını dışlamak için tedavi komplet cerrahi eksizyon olmalıdır. Bu olgu İngilizce literatürde rapor edilmiş en büyük vulvar lipomlardan biridir.

**Key Words:** Lipom; Vulva; Dev Lipom.

### Oldukça Sık Görülen Benign Bir Tümörün Nadir Lokalizasyonu

### Özet

Lipoma is the most common benign mesenchymal soft tissue tumor. It consists of mature adipocytes, usually located in subcutaneous tissues and occurs more frequently in obese patients. Subcutaneous lipoma is usually found in the head and neck regions. Vulvar lipoma is extremely rare.

A 72-year-old obese woman was admitted to our hospital with a painless vulvar mass. Physical examination revealed a single, soft, mobile mass in the right vulvar area that measured about 15 cm in its widest dimensions. The excised specimen measured 13 cm and had a yellow cut surface, surrounded by a fibrous capsule. Microscopic examination confirmed the diagnosis of lipoma.

Vulvar lipoma has benign clinical course. If this lesion is untreated, it may grow large. To exclude the possibility of malignancy, surgical excision must be performed. This case is one of the biggest vulvar lipoma cases reported in the Anglophone medical literature.

**Anahtar Kelimeler:** Lipoma; Vulva; Large Lipoma.

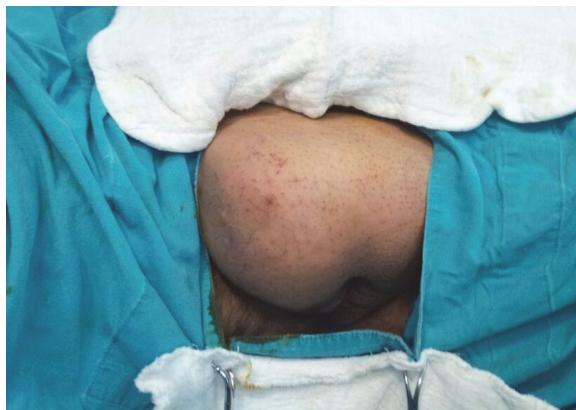
## INTRODUCTION

Lipomas are the most common benign mesenchymal soft tissue tumors (1). They consist of mature adipocytes, usually located in subcutaneous tissues and occur more frequently in obese patients (2, 3). Rare presentations are cervicomedial, deep, endovaginal, hernial, incisional, infiltrating, intramuscular/intermuscular, lumbosacral, myxoid, parosteal, retroperitoneal, sclerotic, and subcutaneous (superficial) lipomas of tendon sheaths and joints (2). Lipomas arising from subcutaneous tissues usually present as single/multiple, well defined, slowly growing, painless soft tissue masses (3). Histological variants include anjiolipoma, myolipoma, myelolipoma, chondroid lipoma, spindle cell/pleomorphic lipoma, hibernoma, and lipoblastoma/lipoblastomatosis (2, 4). Subcutaneous lipomas are usually found in the head and neck regions, shoulders, dorsum, abdomen, and extremities (5). Vulva is an extremely rare location. We present a rare case of giant vulvar lipoma and a review the literature.

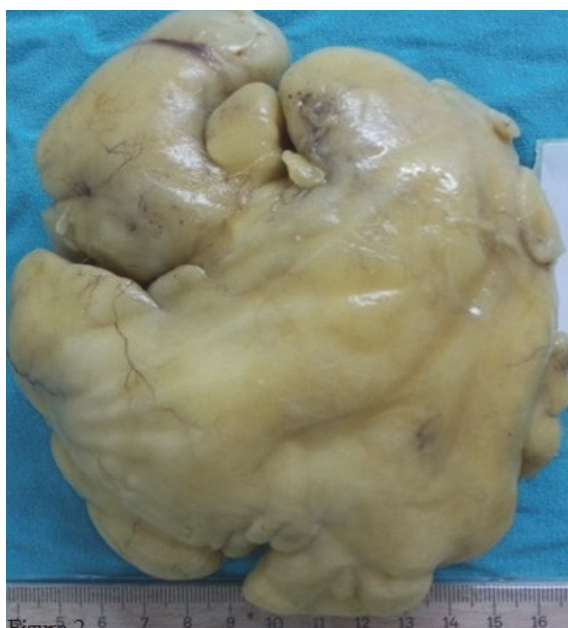## CASE REPORT

A 72-year-old obese woman was admitted to our hospital with a painless, right vulvar mass growing for a few months. She had no history of trauma. Physical examination revealed a single, soft, non-tender, mobile mass in the right vulvar area that measured about 15 cm in its widest dimensions (Figure1). There was no inguinal lymphadenopathy. Pelvic examination and laboratory analyses including tumor markers were both normal. Ultrasonographic examination of the mass indicated a fatty mass with multiple fibrillar structures. Preoperative diagnosis was lipoma. Enucleation and complete excision by median incision was performed under spinal anesthesia. The excised specimen measured 13x11x4,5 cm and surrounded by a fibrous capsule (Figure2). The tumor was well circumscribed and showed a homogenous yellow-cut surface. Microscopic examination revealed capsulated benign mesenchymal tumor composed of mature adipocytes confirming the diagnosis of vulvar lipoma (Figure3).

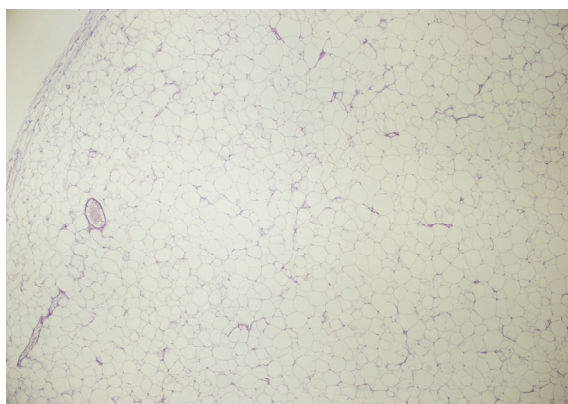
## DISCUSSION



**Figure 1.** Single, soft, non-tender, mobile mass located in the right vulvar area.



**Figure 2.** Macroscopically the tumor was lobulated, well circumscribed, surrounded by a fibrous capsule and measured 13x11x4,5 cm.



**Figure 3.** Microscopically the tumor was encapsulated and composed of mature uniform adipocytes (H&E, X10).

Benign tumors of the vulva are classified according to their origins as epithelial or mesenchymal cell tumors (6). Lipomas are benign mesenchymal tumors that may be observed in all ages but typically appearing between 40-60 years (1). These tumors are the most common soft tissue tumors. Lipomas are usually found in the head and neck regions (4). When they arise from subcutaneous fat tissues, they present as painless, mobile, and soft tumors. Lipomas are usually asymptomatic. They may be symptomatic by neural irritation (3).

Vulva is an extremely rare location for these tumors and the review of the literature we conducted showed approximately 70 cases of vulvar lipomas (2). The etiology and pathogenesis are not clear. Genetic, endocrine, and inflammatory mechanisms have been suspected as potential reasons (3). Also, chronic mechanic irritation in adults has been considered in its etiology (6). Some vulvar lipomas are congenital. Only 15 cases of vulvar lipomas developing before adulthood have been reported in the literature (1). 12 of them were congenital and 10 were located in right vulvar region (1, 2). The majority of cases are right sided and this suggests possible embryologic origin (1).

There are only a few large adult vulvar lipomas which measure over 10 cm in their widest diameter in medical literature in English. Kehagias et al. have reported a case of a 52 years old woman with 17 cm and De Lima Filho et al. have reported a 35 years old woman with 10 cm vulvar lipomas (6, 7). Jozvik et al. have reported a case of 16 cm pedunculated lipoma located in the right labium majus in a 19-year-old woman (1). The present case is a 72-year-old woman with a large right vulvar lipoma measured 13 cm in its widest dimensions. Our case is one of the largest vulvar lipomas detected in adults in the literature in English.

Vulvar lipomas can be diagnosed by clinical examination (1, 8). They must be differentiated from the Bartholin's gland cysts and the canal of Nuck (7, 8). Ultrasound, computed tomography, and magnetic resonance imaging are useful in differentiating them from vulvar cysts and inguinal hernias (7, 8). Vulvar lipomas consist of mature fat cells, intersperse with strands of fibrous connective tissues. They must be distinguished from well differentiated liposarcomas/atypical lipomatous tumors histologically (8). To exclude the possibility of malignancy, surgical excision must be performed (1, 6). Well-differentiated liposarcomas/atypical lipomatous tumors are low grade, slow growing, locally aggressive malignant mesenchymal neoplasms composed entirely within or in a part of a mature adipocytic proliferation showing variation in cell sizes. But at least focal nuclear atypia in both adipocytes and stromal cells provide the differentiation of these neoplasms from ordinary lipomas (4, 8). The treatment of the vulvar lipoma is surgical excision or liposuction (3, 7). In large extensive lipomas, liposuction may be a less invasive method, however, leaving the fibrous capsule behind may cause recurrence

and histopathological examination may not be possible (3, 8).

Vulvar lipomas have a benign clinical course. They grow slowly and arise a localized mass that may cause mechanical problems (2). If these lesions are untreated, they may grow large so that the preferred treatment must be complete surgical excision (2, 6, 7, 8).

We have hereby presented a case of a 72-year-old woman who was admitted with a large mass in the right side of the vulva. Histopathological examination revealed that it was a vulvar lipoma. This case is one of the largest vulvar lipomas ever reported in medical literature in English.

#### ACKNOWLEDGEMENTS

Authors of this report have no conflict of interest.

#### REFERENCES

1. Jóźwik M, Kołodziejczak M, Klonowska-Dziatkiewicz E, Jóźwik M. Giant Vulvar Lipoma in an Adolescent Girl: A Case Study and Literature Review. *J Pediatr Adolesc Gynecol.* 2014;27(5):e117-9.
2. Goldblum JR, Folpe AL, Weiss SW. Benign lipomatous tumors. In: Weiss SW, Goldblum JR, eds. *Enzinger and Weiss's Soft Tissue Tumors.* 6th edition. Philadelphia: Elsevier Saunders; 2014. p.443-83.
3. Lee JH, Chung SM. Large vulvar lipoma in an adolescent: a case report. *J Korean Med Sci.* 2008;23(4):744-6.
4. Odoi AT, Owusu-Bempah A, Dassah ET, Darkey DE, Quayson SE. Vulvar lipoma: is it so rare? *Ghana Med J.* 2011;45(3):125-7.
5. Kehagias DT, Smyrniotis VE, Karvounis EE, Gouliamos AD, Creatas G. Large lipoma of the vulva. *Eur J Obstet Gynecol Reprod Biol.* 1999;84(1):5-6.
6. Oh JT, Choi SH, Ahn SG, Kim MJ, Yang WI, Han SJ. Vulvar lipomas in children: an analysis of 7 cases. *J Pediatr Surg.* 2009;44(10):1920-3.
7. Aust MC, Spies M, Kall S, Gohritz A, Boorboor P, Kolokythas P, et al. Lipomas after blunt soft tissue trauma: are they real? Analysis of 31 cases. *Br J Dermatol.* 2007;157(1):92-9
8. Fletcher CDM, Bridge JA, Hogendoorn PCW, Mertens F. Lipoma, Atypical lipomatous tumour. In: Nielsen GP, Mandahl N, Dei Tos AP, Pedetour F, eds. *World Health Organization Classification of Tumours of Soft Tissue and Bone.* 4th edition. Lyon: IARC; 2013. p.20-21,35-6.

Received/Başvuru: 20.10.2014, Accepted/Kabul: 12.01.2015

#### Correspondence/İletişim

Elif USTURALI KESKİN  
İzmir Tepecik Eğitim Araştırma Hastanesi, Patoloji Kliniği,  
İZMİR, TÜRKİYE  
E-mail: drelikkeskin@gmail.com

#### For citing/Atıf için

Keskin EU, Pala EE, Çakir E, Taner CE, Sarikaya S, Keskin F.  
An uncommon presentation of a common tumour. *J Turgut  
Ozal Med Cent* 2015;22:191-3 DOI:  
10.7247/jtomc.2014.2375