

A case with pyopericardium and cardiac tamponade induced by migration of ventriculoperitoneal shunt catheter

Ventriküloperitoneal şant kateter migrasyonuna bağlı gelişen pürülan perikardit ve kardiyak tamponad olgusu

Cemşit Karakurt,¹ Serkan Fazlı Çelik,¹ Mehmet Öztürk,² Olcay Murat Dişli,³ Cengiz Yakıncı⁴

Institution where the research was done:

Department of Pediatric Cardiology, Medical Faculty of İnönü University, Malatya, Turkey

Author Affiliations:

Departments of ¹Pediatric Cardiology, ²Radiology, ³Cardiovascular Surgery and ⁴Pediatrics, Medical Faculty of İnönü University, Malatya, Turkey

Ventriculoperitoneal (VP) shunt is a method used in the treatment of hydrocephalus. In this article, we report a four-year-old girl who was implanted a VP shunt due to hydrocephalus, and referred to our clinic due to dyspnea and cardiomegalia. Echocardiographic examination revealed cardiac tamponade and pericardial effusion. Thorax computed tomography, which was performed due to suspicion of migration of the VP catheter to the pericardium, showed that the VP catheter tip was inside the pericardium. Pericardiectomy was performed due to pericardial constriction was developed after tube drainage, and the VP shunt catheter was shortened and replaced into the abdominal cavity.

Keywords: Complication; pericardial effusion; ventriculoperitoneal shunt.

A ventriculoperitoneal (VP) shunt procedure is one of the treatment options for hydrocephalus, but complications such as the occlusion and separation of the catheter, accumulation of cerebrospinal fluid (CSF), shunt infection, and migration of the distal end of the catheter to the stomach, heart, pulmonary artery, thoracic cavity, bladder, and scrotum have been reported.^[1-4] Although two cases of cardiac tamponade after a ventriculoatrial (VA) shunt procedure exist in the literature, to our knowledge, this the first reported case of a patient with pyopericardium and cardiac tamponade due to the migration of a VP shunt catheter.

Ventriküloperitoneal (VP) şant hidrosefali tedavisinde başvuru- lan bir yöntemdir. Bu yazıda, daha önce hidrosefali nedeniyle VP şant takılan ve kliniğimize dispne ve kardiyomegali nedeniyle sevk edilen dört yaşında bir kız hasta sunuldu. Ekokardiyografi incelemesinde kardiyak tamponad ve perikardiyal efüzyon sap- tandı. Ventriküloperitoneal kateterin perikard içerisine göç etti- ğinden şüphelenildiği için çekilen toraks bilgisayarlı tomografi- de, VP kateter ucunun perikard içerisinde olduğu görüldü. Tüp drenaj sonrası perikardiyal konstriksiyon gelişmesi nedeniyle perikardiyektomi yapıldı ve VP şant kateteri kısaltılarak batın içerisine alındı.

Anahtar sözcükler: Komplikasyon; perikardiyal efüzyon; ventriküloperitoneal şant.

CASE REPORT

A four-year-old girl who had a VP shunt because of hydrocephalus was admitted to our facility with dyspnea. In addition, she also had a markedly enlarged cardiac silhouette on her chest X-ray. The patient had previously been hospitalized at another center for two weeks due to septicemia, and she had a history of a neurogenic bladder which required intermittent urinary catheterization. Upon admission, echocardiography revealed a fibrinous pericardial effusion measuring 35 mm along with the diastolic collapse of the right ventricle



Available online at
www.tgkdc.dergisi.org
doi: 10.5606/tgkdc.dergisi.2014.9761
QR (Quick Response) Code

Received: December 31, 2013 *Accepted:* March 31, 2014

Correspondence: Cemşit Karakurt, M.D. İnönü Üniversitesi Tıp Fakültesi Pediatrik Kardiyoloji Bilim Dalı, 44280 Malatya, Turkey.

Tel: +90 422 - 341 06 60 e-mail: ckarakurt@yahoo.com

(Figure 1). After confirming the pericardial effusion, under fluoroscopy, we inserted a 4-French (4F) pigtail catheter to drain the pericardium (Figure 2) and also initiated antibiotic treatment (vancomycin and imipenem) at the same time. On the first day, 350 ml pericardial fluid was drained from the catheter, and this had the following biochemical characteristics: a pH of 6.5, a white blood cell (WBC) count of 97/HPF, specific gravity of 1.024, a glucose level of 7 mg/dL, and a total protein level of 3.9 g/dL. In addition, the fluid culture identified both *Escherichia coli* and *Klebsiella pneumoniae*. The purulent and fibrinous pericardial drainage was continued during the patient's follow-up despite the presence of the pigtail catheter. Hence, the catheter was removed and tube drainage was performed by the cardiovascular surgeon. An echocardiographic examination was then performed which confirmed the increased

pericardial thickness as well as the constrictive pericarditis and pericardial effusion that had been identified during follow-up (Figure 3). Additionally, during the procedure, the shunt catheter was seen in the pericardial cavity and it caused perforation (Figure 4a, b). After confirming the presence of the catheter in the pericardial cavity, a pericardiectomy was performed because of constriction after drainage. In this procedure, the VP shunt catheter was shortened and subsequently moved into the abdominal cavity. The antibiotic treatment continued for six weeks, and after then the patient discharged from hospital.

DISCUSSION

Complications associated with the VP shunt include shunt obstruction, infection, seizure, and shunt disconnection.^[1,2] A review of the literature revealed numerous sites for distal catheter migration, for example the chest, heart, umbilicus, colon, stomach, bladder, scrotum, and anus, with these migrations usually involving the perforation or penetration of abdominal and thoracic organs.^[3,4] Several cases of VP shunt catheter migration into the heart or pulmonary artery have been reported^[2,4] in which the distal catheter of the VP shunt migrated into the two sites via the internal jugular vein. Therefore, careful, proper placement of the distal catheter during the tunneling procedure should be emphasized to prevent life-threatening complications. Several cases have also been reported of the VP shunt catheter migrating into the lungs via diaphragm.^[3] Moreover, we found two cases in the literature of cardiac tamponade after VA shunt placement. Mastroianni et al.^[5] presented a

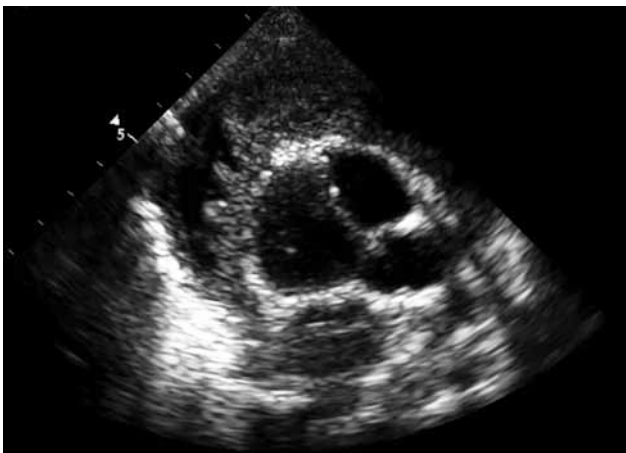

Figure 1. Echocardiography showing the fibrinous pericardial effusion.

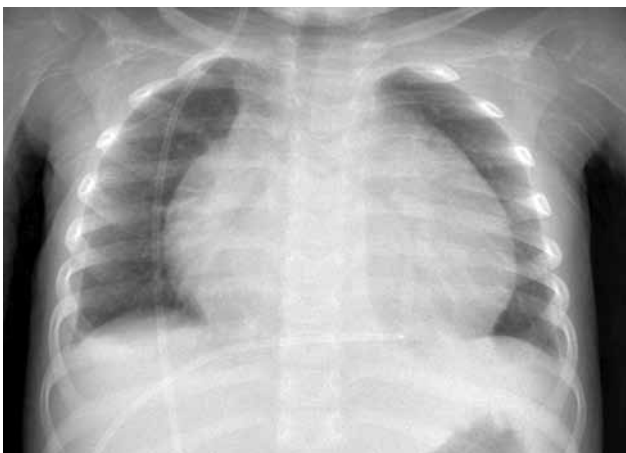

Figure 2. Chest X-ray showing the cardiomegaly and ventriculoperitoneal shunt catheter tip in the pericardium.

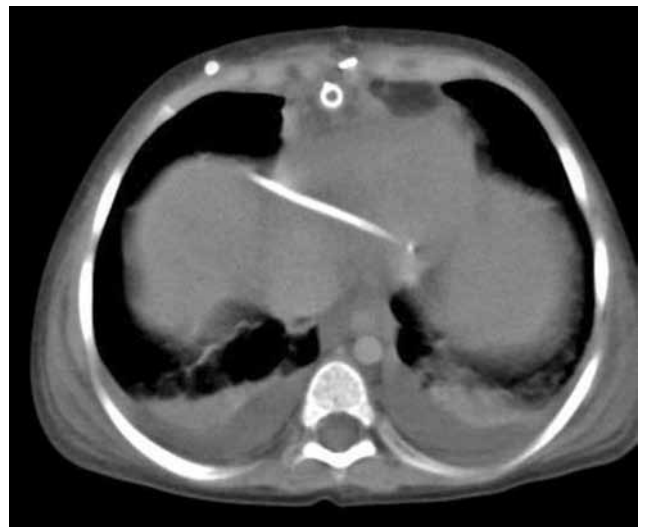

Figure 3. Computed tomography showing the shunt catheter tip in the pericardial cavity along with pericardial effusion.

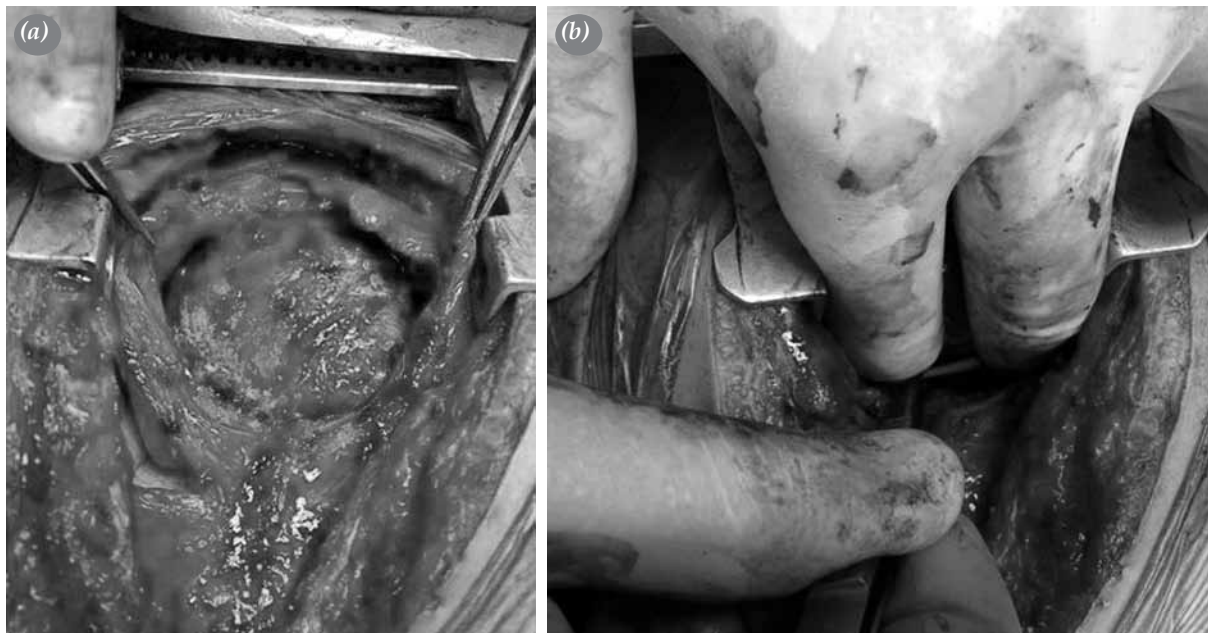


Figure 4. (a, b) During the pericardiectomy, the pericardium appeared to be thickened, and the shunt catheter tip was seen in the pericardial cavity.

48-year-old woman who had late cardiac tamponade after undergoing this type of surgery. In her case, the shunt had become disconnected at the craniocervical section between the second and seventh cervical vertebra and then migrated into the pericardial cavity. El-Eshmawi et al.^[6] also presented an eight-month-old infant who had cardiac tamponade after the VA shunt procedure. They found that the shunt tip had perforated the ventricular wall and subsequently migrated into the pericardial cavity. In both of these cases, gradual erosion of the atrial or ventricular wall caused by the distal tip of the VA shunt was one of the main sources of the cardiac tamponade. However, to our knowledge, there are no previously published reports about VP shunt migrating into the pericardium via a transdiaphragmatic pathway (or any other route) that resulted in pyopericardium and cardiac tamponade.

In conclusion, our patient had pyopericardium and pleural effusion that developed after VP shunt placement. Respiratory distress and cardiac tamponade after this type of operation are rare, but they should still be considered since they are important cardiac and thoracic complications. Based on our patient, it is also important to keep in mind the possibility of VP shunt catheter migration into the pericardial cavity.

Declaration of conflicting interests

The authors declared no conflicts of interest with respect to the authorship and/or publication of this article.

Funding

The authors received no financial support for the research and/or authorship of this article.

REFERENCES

1. Cheng JY, Lo WC, Liang HH, Kun IH. Migration of ventriculoperitoneal shunt into the stomach, presenting with gastric bleeding. *Acta Neurochir (Wien)* 2007;149:1269-70.
2. Miyamoto J, Nijima K. Migration of the distal catheter of ventriculo-peritoneal shunt into the thoracic cavity. *No Shinkei Geka* 2012;40:241-5.
3. Pohlman GD, Wilcox DT, Hankinson TC. Erosive bladder perforation as a complication of ventriculoperitoneal shunt with extrusion from the urethral meatus: case report and literature review. *Pediatr Neurosurg* 2011;47:223-6.
4. Beach C, Manthey DE. Tension hydrothorax due to ventriculopleural shunting. *J Emerg Med* 1998;16:33-6.
5. Mastroianni C, Chauvet D, Ressencourt O, Kirsch M. Late ventriculo-atrial shunt migration leading to pericardial cerebrospinal fluid effusion and cardiac tamponade. *Interact Cardiovasc Thorac Surg* 2013;16:391-3.
6. El-Eshmawi A, Onakpoya U, Khadragui I. Cardiac tamponade as a sequela to ventriculoatrial shunting for congenital hydrocephalus. *Tex Heart Inst J* 2009;36:58-60.