

JIUMF
Vol 17, No 2 (2010): Journal of
Inonu University Medical
Faculty

[Table of Contents](#)

Reading Tools

Knot Formation of...

*Jahollari, Günay, Guler, Şahin,
Yokuşoğlu*

- [Abstract](#)
- [Review policy](#)
- [About the author](#)
- [How to cite item](#)
- [Indexing metadata](#)
- [Print version](#)
- [Look up terms](#)
- Notify colleague*
- Email the author*
- Add comment*
- [Finding References](#)

Related items

- [Author's work](#)
- [Related studies](#)
- [Multimedia](#)
- [Book searches](#)
- [Pay-per-view](#)
- [Government health sites](#)
- [Relevant portals](#)
- [Databases](#)
- [Online forums](#)
- [Teaching files](#)
- [Government policy](#)
- [Media reports](#)
- [Web search](#)

Search journal

All

[Close](#)

* Requires [registration](#)



Knot Formation of a Metallic Guide Wire: A Mechanical Complication of Central Venous Catheterization

Artan Jahollari*, Celalettin Günay*, Adem Güler*, Mehmet Ali Şahin*, Mehmet Yokuşoğlu**

* Gulhane Military Medical School, Department of Cardiovascular Surgery, Ankara

** Gulhane Military Medical School, Department of Cardiology, Ankara

Central venous catheter is a cornerstone of perioperative care and also a reliable way for hemodialysis. Due to its invasive nature complication rate can be as high as 5 to 29% and several factors have been associated with mechanical complications. Herein, we present a 58-year-old male with acute renal failure who underwent internal jugular vein catheter placement for hemodialysis, however, in this knot formation of the guide wire in the subcutaneous tissue before entering the vein lumen occurred. The knot formation was found between platysma fibers and the wire retraction was possible at this point.

After a slight compression of the vein, bleeding control was performed and the day after the patient was discharged uneventfully. Although venous catheterization is a simple procedure, it requires maximal care, experience and suitable conditions.

Key Words: Central Venous Catheterization, Peripheral Catheterization, Mechanical Complication

Metalik Kılavuz Telin Dügümlenmesi: Santral Venöz Kateterizasyonun Mekanik bir Komplikasyonu

Santral venöz kateterizasyon perioperatif bakımın köşe taşıdır ve bununla birlikte hemodiyaliz için de güvenilir bir yoldur. İnvazif doğasından dolayı komplikasyon oranı %5' den %29'a kadar varabilmektedir ve mekanik komplikasyonlar birçok faktörle ilişkilidir. Burada 58 yaşında erkek bir hastada akut renal yetersizlik nedeniyle internal juguler vene kateter yerleştirilen ancak cilt altı dokuda ven lümeninden önce kılavuz telin düğüm olduğu bir olgu sunulmaktadır. Düğüm platysma liflerinin arasında bulundu ve bu noktada kılavuz teli geri çekmek mümkün oldu. Vene hafifçe kompresyon yapılarak kanama kontrolü sağlandı ve ertesi gün hasta sorunsuz şekilde taburcu edildi. Venöz kateterizasyon basit bir işlem olmasına rağmen maksimal dikkat, tecrübe ve uygun koşullar gerektirmektedir.

Anahtar Kelimeler: Santral Venöz Kateterizasyon, Periferik Kateterizasyon, Mekanik Komplikasyon

Central venous catheterization is a cornerstone of perioperative care. It provides a good way for medication delivery and hemodynamic monitorization. Also, when needed, it is a reliable way for hemodialysis. Due to the invasive nature of the procedure mechanical, infectious and thromboembolic complication rate can be as high as 5 to 29% of the attempts.¹ Besides, Horner syndrome and malpositions were reported.^{2,3} Several factors such as low or high body mass index, prior catheterization, surgery or radiotherapy, number of punctions, emergency state, operator experience, ultrasonography usage, etc. have been associated with mechanical complications.⁴

A 58 year-old male patient with acute renal failure was admitted to cardiovascular surgery department after two attempts of placement of internal jugular vein catheter by an attending staff of nephrology. During the second attempt, it was noted that there was a difficulty in

The X-ray examination showed a knot formation in the subcutaneous tissue prior to the introduction into the vein and the distal part of the catheter was advancing into the right heart (Figure 1).

At the cardiovascular surgery department, the incision of the introduction site posed the knot formation between platysma fibers (Figure 2) and made the retraction of the catheter possible. After the bleeding was controlled by a gentle compression of the vein, the layers were sutured thoroughly. The patient was discharged on the next day. Although central venous catheterization is a relatively simple procedure, it requires maximal care, experience and suitable conditions. Mechanical complications are very common and can lead to further invasive interventions, therefore multidisciplinary approach may be necessary.

Başvuru Tarihi: 30.04.2010, Kabul Tarihi: 01.06.2010

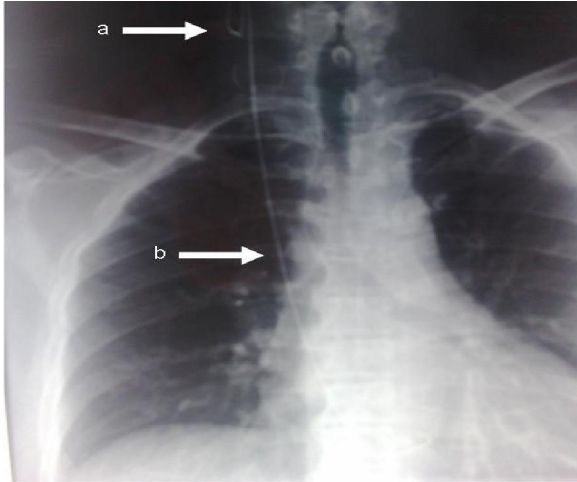


Figure 1. X-Ray showing the knot formation (a) and the presence of the distal guide inside the vascular structures and right heart (b).

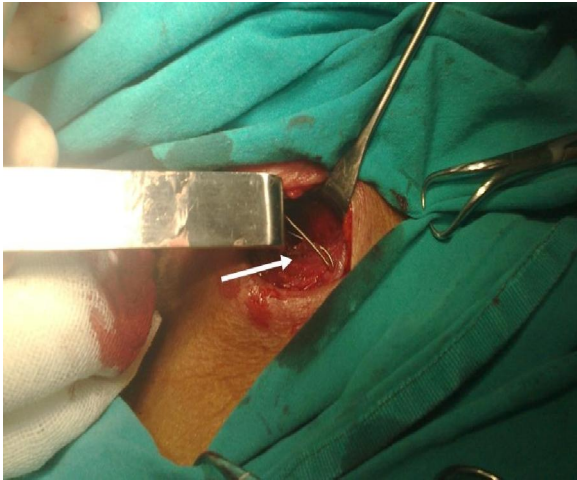


Figure 2. Presence of the knot formation between the platysma fibers (arrow). A simple retraction from this point served to liberate the entrapped guide.

References

1. McGee DC, Gould MK. Preventing complications of central venous catheterization. *N Engl J Med.* 2003;348:1123-33.
2. Keskinbora HK, Keskinbora K, Gönen T. Horner Syndrome Following Venous Catheterization for Chemotherapy: Scientific Letter. *Türkiye Klinikleri J Med Sci* 2009;29:508-9.
3. Erçelen Ö, Şahin A, Ramzi N, Aypar Ü. [Central venous catheter malposition: case report]. *Türkiye Klinikleri J Med Sci* 1997;17:213-6.
4. Lefrant JY, Muller L, De La Coussaye JE, Prudhomme M, Ripart J, Gouzes C, Peray P, Saissi G, Eledjam JJ. Risk factors and immediate complication of subclavian vein catheterization in critically ill patients. *Intensive Care Med.* 2002;28:1036-41.

Corresponding Address: Mehmet YOKUSOGLU, MD
Gulhane Military Medical School, Department of Cardiology,
ANKARA

Phone: 90 (312) 304 42 67

Fax: 90 (312) 304 42 50

e-mail: myokusoglu@gata.edu.tr

e-mail: myokusoglu@yahoo.com