

# Vacuum-assisted closure in the treatment of biliary leakage following gunshot injury to the liver

Arife Şimşek , Mahmut Burak Kılıcı , Ertuğrul Karabulut , Müfit Sansal , Bülent Ünal 

Department of General Surgery, İnönü University School of Medicine, Malatya, Turkey

**Cite this article as:** Şimşek A, Kılıcı MB, Karabulut E, Sansal M, Ünal B. Vacuum-assisted closure in the treatment of biliary leakage following gunshot injury to the liver. *Turk J Gastroenterol* 2019; 30(7): 658-9.

Dear Editor,

High velocity gunshot injuries result in extensive tissue loss. Tissue necrosis almost always facilitates infection. The bacterial load of the affected organ in abdominal injuries may increase the severity of the infection (1). Open surgery, percutaneous drainage, and endoscopic procedures have been described for the management of biliary leakage following gunshot injury to the liver (2). In this study, we present a case of biliary leakage following gunshot injury to the liver that was treated with vacuum assisted closure (VAC) system. Informed consent was obtained from the patient.

A 29-year-old female with gunshot injury was admitted to the hospital. She was hypotensive with reflex tachycardia. There was a 4x4 cm entrance gunshot wound on right 5<sup>th</sup>-6<sup>th</sup>-7<sup>th</sup> rib along the midclavicular line and an exit gunshot wound on right 7<sup>th</sup>-8<sup>th</sup>-9<sup>th</sup> rib in the back. On the right side, there was also an entrance gunshot wound inferolateral to the inguinal ligament and an exit gunshot wound in the posterior superior iliac spine. She had an open fracture in the right knee and an avulsion in the left arm. Due to hemodynamic instability, emergency laparotomy was performed. Complete rupture of hepatic segments 6 and 7 and contusion of hepatic segments 5 and 8 (grade IV injury) were managed by resection of both segments 6 and 7. Four drains were inserted into the abdomen. The bullet holes were debrided, and external fixator was applied for knee fusion.

The patient was scheduled to have an endoscopic retrograde cholangiopancreatography (ERCP) postoperatively for biliary leakage that was detected on day 2 of the operation. Unfortunately, before the time of day her ERCP was scheduled she had to undergo surgery for necrotizing fasciitis extending from right side of the iliac crest to

the level of 5<sup>th</sup> rib in the back (Figure 1). On exploration, it was observed that bile flowed to the open wound (instate of drainage system) through the large defect created by the bullet in the thoracolumbar region. Although the large defect hampered the function of the subhepatic drain, it preserved the intraabdominal cavity from biliary content by giving rise to biliary-cutaneous fistula. The nonfunctional subhepatic drain was removed, and the VAC system (ATMOS S 042 NPWT) was applied to manage the infected wound. In this process, patient was kept often in the right-side lying position, and the VAC system was renewed more often than routine practice (10 times in 10 days) to keep biliary leakage under strict control. During the course, it was observed that biliary leakage was arrested spontaneously. The patient was discharged on postoperative day 51 after the wound was repaired with a skin graft (Figure 2).

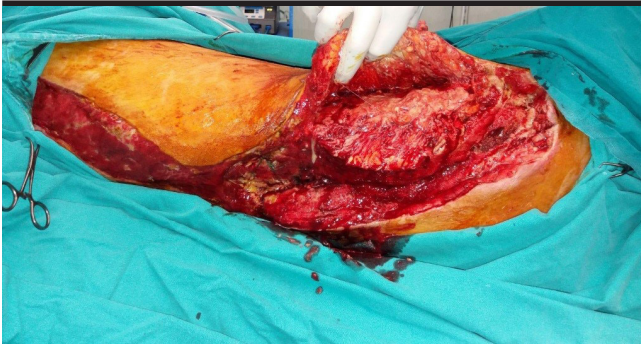
Surgery is a widely accepted method for the treatment of penetrating abdominal trauma. However, in appropriate candidates who are hemodynamically stable and free of injury to the gastrointestinal tract, non-operative management (NOM) can be chosen for penetrating liver injury (3). In most of the cases, hepatic bleeding ceases spontaneously or necessitates an angiographic embolization (3). Hemodynamic instability of the current patient did not allow NOM to be performed; thus, emergency laparotomy was chosen. However, a postoperative complication of penetrating liver injury, biliary leakage, was successfully managed non-operatively by the VAC system. The VAC system is gaining in popularity for the treatment of abdominal trauma, intraabdominal sepsis, and abdominal compartment syndrome (4). It also appears to be effective in the treatment of enteroatmospheric fistula (5). In literature, a case was described wherein a biliary leakage secondary to the duodenal fistula was treated with the VAC system (6). To our knowledge, this was the first

Corresponding Author: Arife Şimşek; [draksimsek@yahoo.com.tr](mailto:draksimsek@yahoo.com.tr)

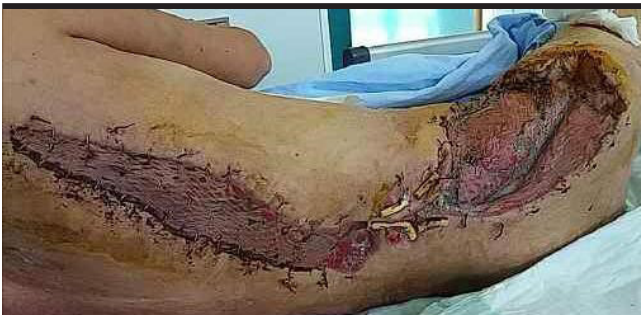Received: May 13, 2018 Accepted: September 17, 2018 Available online date: November 28, 2018

© Copyright 2018 by The Turkish Society of Gastroenterology · Available online at [www.turkjgastroenterol.org](http://www.turkjgastroenterol.org)

DOI: 10.5152/tjg.2018.18373



**Figure 1.** Appearance of the wound after extensive debridement due to necrotizing fasciitis



**Figure 2.** Appearance of the wound after grafting

case wherein biliary leakage following gunshot injury to the liver was controlled by the VAC system. Because they are well known, open surgery, percutaneous drainage, and endoscopic procedures have been described for the management of biliary leakage following gunshot injury to the liver (2). The current patient was scheduled to have an ERCP, but an unexpected circumstance (necrotizing fasciitis) forced her to undergo surgery followed by application of the VAC system. Fortunately, the success of the VAC system turned the disadvantage of necrotizing fasciitis into the advantage by managing both biliary leakage and infected wound non-operatively.

In conclusion, the VAC system may be effective in controlling biliary leakage following gunshot injury to liver because it can treat infected wounds with large tissue loss.

**Informed Consent:** Informed consent was obtained from the patient who participated in this study.

**Peer-review:** Externally peer-reviewed.

**Author Contributions:** Concept - A.S., B.U.; Design - A.S., B.U., M.B.K.; Supervision - A.S., B.U., M.B.K.; Data Collection and/or Processing - A.S., B.U., M.B.K., E.K., M.S.; Analysis and/or Interpretation - A.S., B.U., M.B.K., E.K., M.S.; Literature Search - A.S., M.B.K., E.K.; Writing Manuscript - A.S., B.U., M.B.K., E.K., M.S.; Critical Reviews - A.S., M.B.K., B.U.

**Conflict of Interest:** The authors have no conflict of interest to declare.

**Financial Disclosure:** The authors declared that this study has received no financial support.

## REFERENCES

1. Gorgulu S, Gencosmanoglu R, Akaoglu C. Penetrating abdominal gunshot wounds caused by high-velocity missiles: a review of 51 military injuries managed at a level-3 trauma center. *Int Surg* 2008; 93: 331-8.
2. LeBedis CA, Bates DDB, Soto JA. Iatrogenic, blunt, and penetrating trauma to the biliary tract. *Abdom Radiol* 2017; 42: 28-45. [\[CrossRef\]](#)
3. Starling SV, de Azevedo CI, Santana AV, Rodrigues Bde L, Drummond DA. Isolated liver gunshot injuries: nonoperative management is feasible? *Rev Col Bras Cir* 2015; 42: 238-43. [\[CrossRef\]](#)
4. Mutafchiyski VM, Popivanov GI, Kjossev KT, Chipeva S. Open abdomen and VAC® in severe diffuse peritonitis. *J R Army Med Corps* 2016; 162: 30-4. [\[CrossRef\]](#)
5. Tavusbay C, Genc H, Cin N, Kar H, Kamer E, Atahan K, Hacıyanlı M. Use of a vacuum-assisted closure system for the management of enteroatmospheric fistulae. *Surg Today* 2015; 45: 1102-11. [\[CrossRef\]](#)
6. Obolenskii VN, Ermolov AA, Oganessian KS, Aronov LS. Vacuum-assisted laparostomy in complex treatment of patient with peritonitis and internal biliary fistula. *Khirurgiia (Mosk)* 2013; 91-4.