

A case of chronic granulomatous disease presented with pulmonary abscess and pleural effusion

Lale Guliyeva¹, Erdem Topal², Sinan Kutuk², Mustafa Yavuz Koker²

¹Inonu University, Faculty of Medicine, Department of Pediatrics, Malatya, Turkey

²Erciyes University, Faculty of Medicine, Department of Pediatric Allergy and Immunology, Kayseri, Turkey

Copyright © 2019 by authors and Annals of Medical Research Publishing Inc.

Dear Editor

Chronic granulomatous disease (CGD) is a hereditary primary immunodeficiency disorder, which is a predisposition to bacterial and fungal infections resulting from the deterioration of the ability of microbicidal oxygen metabolites to play an important role in killing bacteria and fungi from leukocytes. The disease is mostly diagnosed in the first year of life and its incidence is 1 in ~200,000 live births. Lung, skin, lymph nodes and liver are the most common organs due to infection (1,2).

A 25-month-old male patient presented with cough that started one month ago and fever for 5 days. In his history, it was known that the patient who was healthy before was diagnosed with CGD as was his cousin. There was no consanguinity between parents. The patient's general condition was moderate, fever was 39° C, pulse 124 / min, respiratory rate was 28 / min, blood pressure was 115/60 mm Hg and oxygen saturation was 93%. During physical examination, crepitation was present in the right lung. In the laboratory examination of the patient, white blood cells 15,400 / mm³, hemoglobin 7,1 g / dl, platelet 255,000 / mm³, 75% polymorphonuclear leukocyte in peripheral blood smear, 20% lymphocyte, C-reactive protein: 6,17 mg / dl, biochemical parameters and electrolytes was normal. The serum immunoglobulin levels were investigated and found to be between the normal ranges. On the chest X-ray, inferior opacity was observed in the right middle and lower zone, and the right sinus was closed. Thoracic ultrasound (US) showed pleural fluid up to 2 cm in the right hemithorax. The patient was diagnosed with pneumonia and antibiotherapy was started. During follow-up, the fever and respiratory distress regressed, but the patient's fever increase again on the 10th day of treatment. There was an increase in the right opaist on the chest X-ray (Figure 1). Recurrent thoracic US revealed effusion in the

right hemithorax containing intense septations. In the contrast-enhanced thoracic computed tomography (CT), a lesion with a 4.5 cm diameter abscess located in the left lingular segment (Figure 2). The immunoglobulins of the patient were within the normal limit for their age. Because her cousin had chronic granulomatous disease, the patient was checked for CGD with the DHR test. Neutrophil respiratory burst activity was measured by DHR assay. After stimulation with phorbol myristate acetate (PMA) neutrophil oxidative burst not activated and SI (stimulation index):1 (normal range 50-80). There was no residual oxidase activity of NADPH oxidase. Additionally mother has a bimodal histogram pattern by DHR assay which is specific for X-linked CGD carrier pattern. Carrier mother has a mixture of %60 defective neutrophil and 40% normal neutrophil (Figure 3). In addition, Empirical vancomycin + voriconazole and interferon gamma treatment were started at 50 mcg / m² two times a week. During follow-up, the fever dropped and the lung abscess decreased.

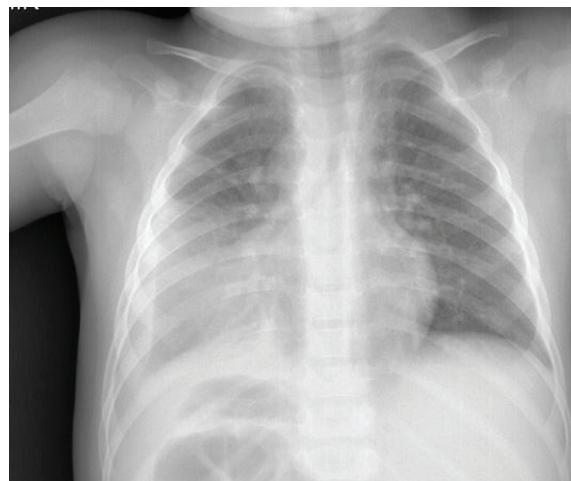


Figure 1. There was an increase in the right opaist on the chest X-ray

Received: 23.03.2018 Accepted: 27.04.2019 Available online: 29.05.2019

Corresponding Author: Erdem Topal, Inonu University, Faculty of Medicine, Department of Pediatrics, Malatya, Turkey

E-mail: draliyilmaz19@gmail.com

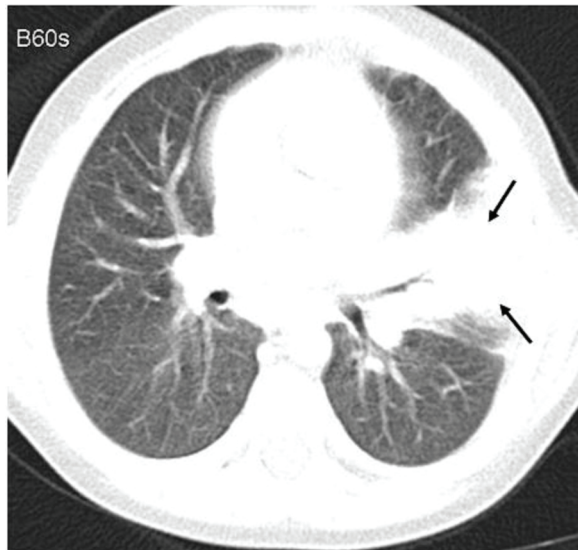


Figure 2. Computed tomography (CT), a lesion with a 4.5 cm diameter abscess located in the left lingular segment

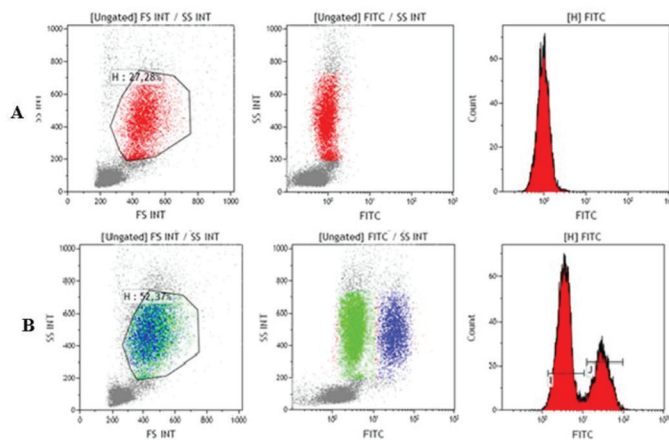


Figure 3. A. Patient' DHR test results. B. Mother' DHR test results. (DHR assay of mother with bimodal histogram pattern which is specific for X-CGD)

The disease is characterized by bacterial, fungal infections as well as granuloma formation secondary to increased inflammation and was first described by Janeway et al. in 1954 (3). The nicotinamide adenine dinucleotide phosphate oxidase system consists of cytochrome b558 (gp91phox and p22phox) and cytoplasmic proteins (p47 phox, p67 phox, p40 phox). Because of the mutations that occur in the construction of these proteins, the phagocytized microorganisms cannot be killed because of the inhibition of superoxide radicals (4). The most common clinical symptoms in the disease are skin lesions, drainage lymphadenitis, pneumonia, empyema, perianal abscess, and osteomyelitis. Granulomas secondary to increased inflammation may occur (5,6). She presented with pleural effusion and pulmonary abscess in our case.

The most common infectious complication of chronic granulomatous disease is pulmonary infections. In two retrospective cohort studies, it was found that 80% of patients with CGD had pneumonia at least once in a lifetime and more than 50% had multiple lung infections (7,8). The

most common pathogens in North America are *Aspergillus* species. *Staphylococcus aureus*, *Burkholderia cepacia* complex, *Serratia marcescens* and *Nocardia* species are other common pathogens (9). Therefore, patients with suspected CGD and suspected pneumonia should be treated empirically with broad-spectrum antibacterial and antifungal drugs. In our case, antibacterial and antifungal therapy was started empirically after the diagnosis was made.

Diagnosis is based on the medical history, clinical findings and tests showing that the respiratory burst is not realized. According to the results of diagnostic tests, verification and specific genotyping are performed with immunoblot or molecular sequence studies (1).

Today, the main treatment methods are antibiotic and antifungal prophylaxis, interferon-gamma prophylaxis, treatment of acute infections and inflammatory complications, hematopoietic stem cell transplantation and gene therapy.

Acknowledgment: The patient's diagnose was kindly supported by TÜBİTAK with project number 114S352

Competing interests: The authors declare that they have no competing interest.

Lale Guliyeva ORCID: 0000-0003-0386-8764

Erdem Topal ORCID: 0000-0002-4439-2689

Sinan Kutuk [no valid email entered ORCID: 0000-0002-6602-3040

Mustafa Yavuz Koker ORCID: 0000-0001-7061-8525

REFERENCES

- Holland SM. Chronic granulomatous disease. Clin Rev Allergy Immunol 2010;38:3-10.
- Köker MY, Yıldız Camcıoğlu Y, Leeuwen K, et al. Clinical, functional, and genetic characterization of chronic granulomatous disease in 89 Turkish patients. J Allergy Clin Immunol 2013;132:1156-63.
- Janeway CA, Craig J, Davison M, Doroney W, Gitlin D, Sullivan JC, et al. Chronic granulomatous disease of childhood: a saga of discovery and understanding. Pediatr Infect Dis J 1993;12:395-8.
- Segal BH, Leto TL, Gallin JI, et al. Genetic, biochemical, and clinical features of chronic granulomatous disease. Medicine (Baltimore) 2000;79:170-200.
- Celiksoy MH, Koker MY, Sensoy G, et al. Chronic granulomatous disease; Three different clinical presentation, J Turgut Ozal Med Cent. 2017;24:217.
- Marciano BE, Spalding C, Fitzgerald A, et al. Common severe infections in chronic granulomatous disease. Clin Infect Dis 2015;60:1176-83.
- Salvator H, Mahlaoui N, Catherinot E, et al. Pulmonary manifestations in adult patients with chronic granulomatous disease. Eur Respir J 2015;45:1613-23.
- Winkelstein JA, Marino MC, Johnston RB Jr, et al. Chronic granulomatous disease: report on a national registry of 368 patients. Medicine (Baltimore) 2000;79:155-69.
- Cansever M, Kırçıl N, Koker MY, et al. Chronic granulomatous disease in a boy who presented with dactylitis caused by *serratia marcescens*, mimicking rheumatic monoarthritis in the newborn period: a case presentation. Erciyes Med J 2018; 40: 95-8.