

A case of cardiac cyst hydatid with multiple system involvement

 Gulec Mert Dogan¹,  Sait Murat Dogan²,  Sevgi Tasolar¹,  Gokalp Okut²,  Ahmet Sigirci¹,  Ozlem Elkiran³,  Cemsit Karakurt³

¹Department of Radiology, Division of Pediatric Radiology, Faculty of Medicine, Inonu University, Malatya, Turkey

²Department of General Surgery, Faculty of Medicine, Inonu University, Malatya, Turkey

³Department of Pediatric, Division of Pediatric Cardiology, Faculty of Medicine, Inonu University, Malatya, Turkey

Copyright@Author(s) - Available online at www.annalsmedres.org

Content of this journal is licensed under a Creative Commons Attribution-NonCommercial 4.0 International License.



Abstract

The larval form of the *Echinococcus granulosus* causes cystic echinococcosis. The liver and the lungs are the most commonly affected organs. Echinococcosis can also be present in other organs although it is rare. We reported a case with sacral bone, cardiac, lung and liver involvement. Clinical and radiological findings of this unique case were discussed. At the Thoracic Computed On the thoracic computed tomography (CT) scan of a 16-year-old female patient was seen multiple parenchymal and subpleural nodular lesions and a cystic mass in the right ventricular cavity. Echocardiographic examination of the patient also observed on CT. Most cases of cardiac cystic echinococcosis were occurred on adult patients, while only 20 cases were in children. For the 20 reported cases in children, there were 9 cases of cardiac echinococcosis involving left ventricle. Because of the possible complications in the presence of cardiac hydatid cyst, treatment should be surgery.

Keywords: Cyst hydatid; computed tomography; heart

INTRODUCTION

The larval form of the *Echinococcus granulosus* causes cystic echinococcosis (1). The liver and the lungs are the most commonly affected organs (2). Echinococcosis can also be present in other organs although it is rare. According to World Health Organization (WHO) data, the incidence of cardiac echinococcosis is about 0.03% to 1.1% in all cases of Echinococcosis (3). Cardiac Echinococcosis (CE) is often caused by *Echinococcus granulosus* and there is no report about involvement of heart by alveolar echinococcosis. The clinical presentation of the Cardiac Echinococcosis can vary. The course of the disease is usually asymptomatic if there is no rupture. The involvement of the bone is rare (0.5–4%), and the typical presentation site is the vertebral body without disk space involvement in the form of multiloculated cysts (4).

We reported a case with sacral bone, cardiac, lung, and liver involvement. Clinical and radiological findings of this unique case are discussed.

CASE REPORT

A 16-year-old female patient was admitted to our hospital with the complaint of cough. She had undergone surgery due to hydatid cyst of the lung 7 years ago and right kidney 3 years ago. She had been given albendazole treatment 7 years ago, but she did not use her medication regularly. Non-contrast thoracic CT scan showed multiple parenchymal and subpleural nodular lesions with cystic density in both lungs (figure 1). A 60 * 30 mm bilobulated lesion was observed on the left side of the sacrum extending to retroperitoneal area causing bone destruction (figure 2). In addition, a 35 * 20 mm cyst was observed in the right side of the anterior mediastinum, which was slightly compressing heart (figure 3). A 36*18 mm interconnected mass in the right ventricular cavity without tricuspid valve obstruction was observed in the echocardiographic examination of the patient that also observed on CT (figure 3, 4). There were also multiple hypodense lesions with <15 mm diameter in all segments of the liver (figure 5). Also, no brain cyst was detected in the patient's brain CT

Received: 21.02.2020 **Accepted:** 30.04.2020 **Available online:** 22.03.2021

Corresponding Author: Gulec Mert Dogan, Department of Radiology, Division of Pediatric Radiology, Faculty of Medicine, Inonu University, Malatya, Turkey, **E-mail:** dr_gulecmert@hotmail.com

excluding brain involvement. Since the cardiac cyst in the right ventricle had a risk of rupture, surgery was planned. A written informed consent had received from the family for surgery. After partial cystic wall excision, protoscolices and daughter cysts were extracted and the cystic wall was capitoned at the operation. The postoperative course of the patient was uneventful. There was no residual mass in the postoperative control echocardiography and control CT (figure 6). The family of the patient had given an informed consent for participation in this study.

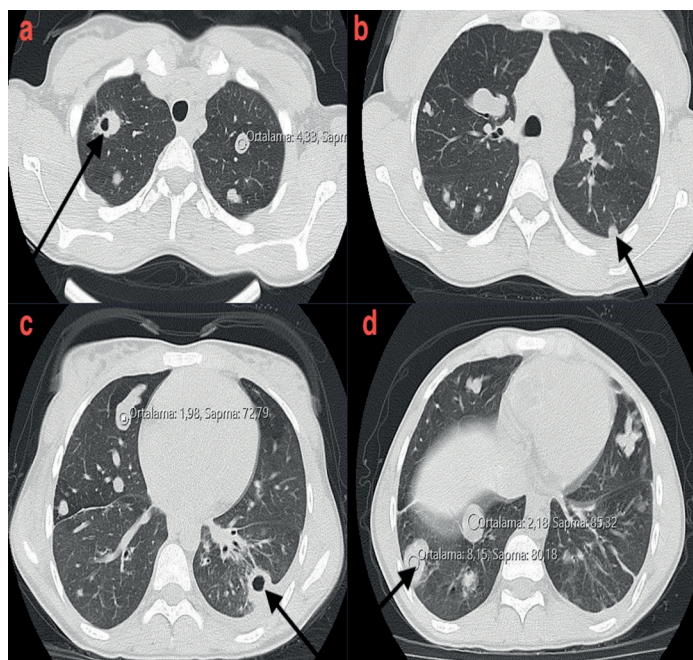


Figure 1a-d. Unenhanced thorax CT

On axial thoracic CT images at parenchymal window, there are multipl millimetric nodular lesions in parenchyma and subpleural areas at all lobes and segments (figure 1a-1d). Some of these nodules have millimetric cavitary areas (figure 1a, figure 1c). Radiodensity measurements of the lesions are compatible with cysts (figure 1a, figure 1d).

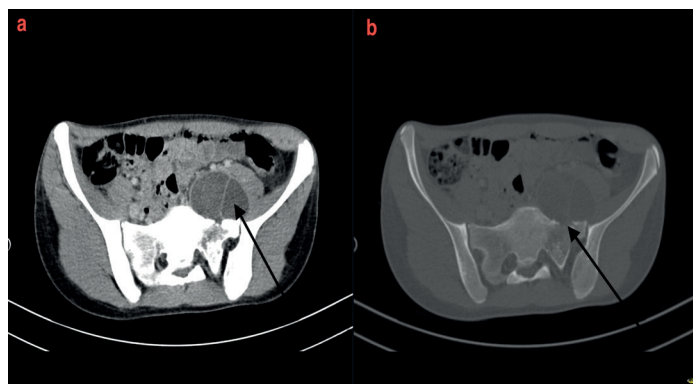


Figure 2a-b. Contrast enhanced abdominal CT

On axial abdomen CT images at bone window, there is a 60 * 30 mm bilobulated hypodense lesion on the left side of the sacrum extending to retroperitoneal area (figure 2a). This lesion causes bone destruction in the sacrum (figure 2b).

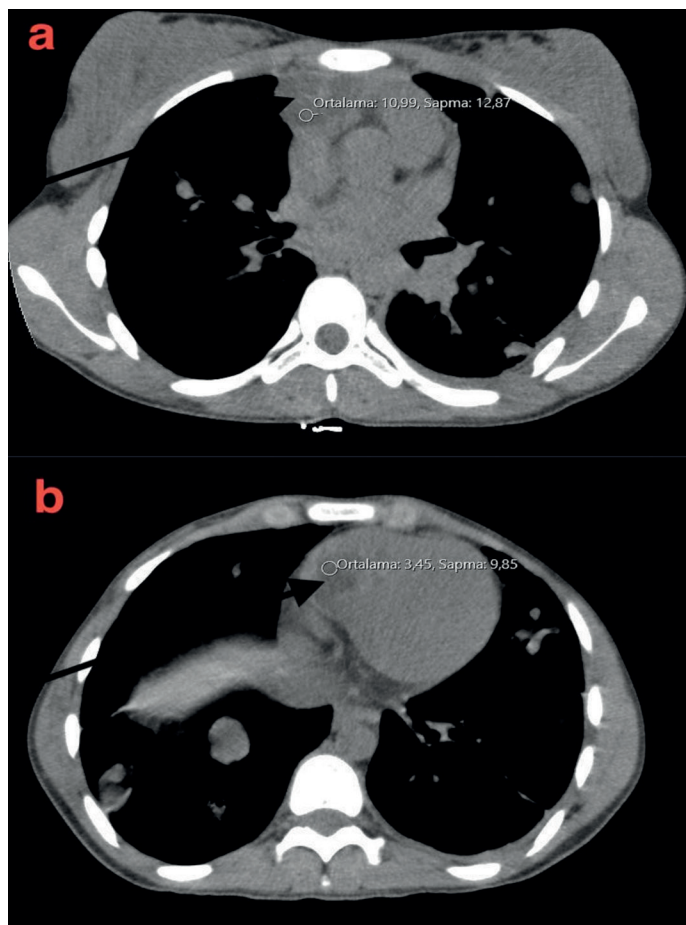


Figure 3a-b. Unenhanced thorax CT

On axial thoracic CT images at mediastinal window, there is a 35 * 20 mm hypodense lesion in the right side of the anterior mediastinum (figure 3a), which is slightly compressing heart. There is a 36 * 18 mm hypodense lesion in the right ventricular cavity (figure 3b). Radiodensity measurements of the lesions are compatible with cysts.

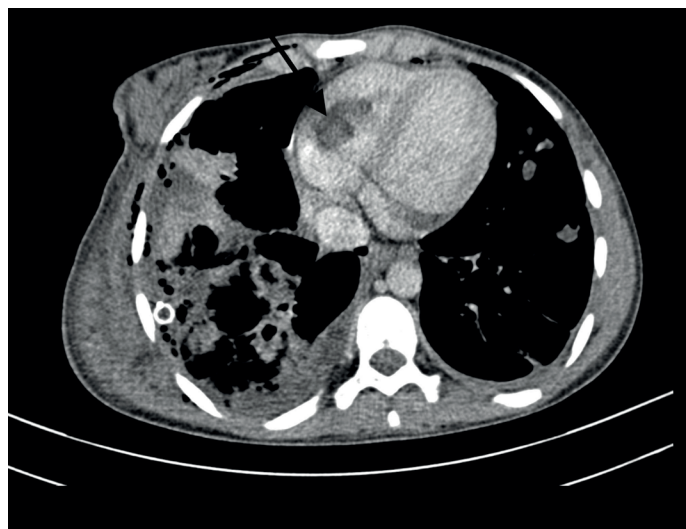


Figure 4. Contrast enhanced thorax CT

On axial thoracic CT images at mediastinal window, there is a 36 * 18 mm hypodense lesion in the right ventricular cavity.

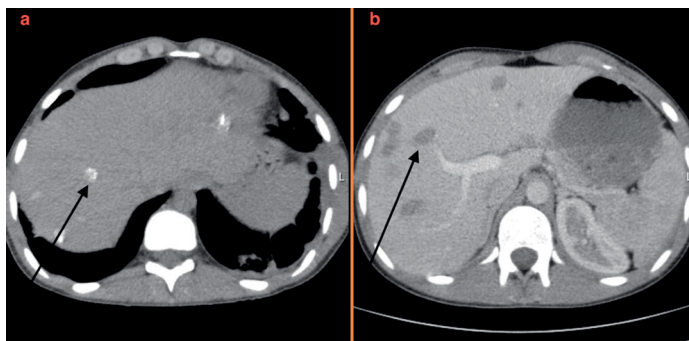


Figure 5a. Unenhanced abdominal CT **b.** Contrast enhanced abdominal CT

On axial abdomen CT images, there are multiple hypodense lesions with <15 mm diameter in all segments of the liver and some of them are calcific (figure 5a).

On axial abdomen CT images, there are multiple hypodense lesions with <15 mm diameter in all segments of the liver (figure 5b).

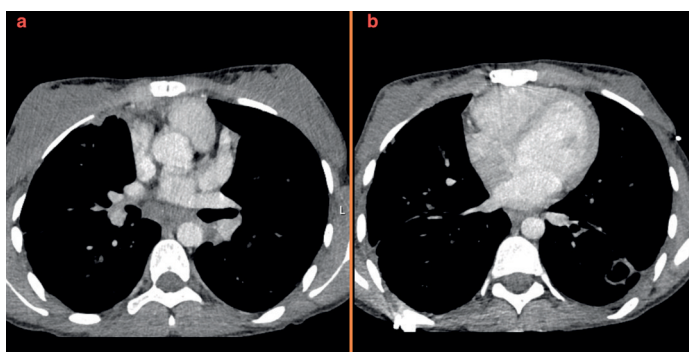


Figure 6a-b. Contrast enhanced thorax CT

There is no any lesion in the right ventricle or anterior mediastinum after surgery on axial thoracic CT images at mediastinal window.

DISCUSSION

In all cyst hydatid with multiple system involvement cases, the most frequently affected site of the heart is the left ventricle (55–60%), followed by the right ventricle (10%), pericardium (7%), pulmonary artery (6%), left atrial appendage (6%), and interventricular septum (4%) (5). The right ventricular involvement was seen in our case, which is a rare form of cardiac echinococcosis.

For the diagnosis of cardiac echinococcosis, noninvasive imaging methods such as CT, MRI, and USG have a critical role (6). There is no routine blood test specific for echinococcosis; however, serology may be used as a first line test and plays an important role for the correct diagnosis of CE (7). The imaging feature of Echinococcus granulosus is a well-defined cystic or multicystic mass containing liquid or septa, some with calcification of the cyst wall, matrix, or both, mainly in the liver or lung (8). It is necessary to do CT scanning to find additional information on the accurate location of lesion and its relation to extracardiac structures, such as liver, lung, bone, muscle, and for detecting calcified cysts (9). In our case, cardiac cyst hydatid was detected on thorax CT, which was taken in consideration of lung involvement since the patient was

presented with cough.

Most cases of cardiac cystic echinococcosis were occurred on adult patients (8), while only 20 cases were in children (10). For the 20 reported cases in children, there were 9 cases of cardiac echinococcosis involving left ventricle. In those 20 cases, 7 cases were associated with extracardiac system involvement (10). In our case besides the cardiac involvement, there was also lung, liver, kidney and bone involvement.

The main pathway of infection is hematogenous seeding by way of the coronary circulation when cardiac involvement is considered (11). The main site of cardiac involvement is the left ventricle due to the dominant left coronary artery.

The larvae reach the right ventricle via the portal vein, inferior vena cava, and right atrium (12). In our case due to lesions in the liver, we think that the cyst in the right ventricle occurred with the transport of larvae from liver to right ventricle via inferior vena cava.

The growths of the cysts are slow, at a rate of 1 cm/year. Cardiac cysts need 1–5 years for maturation and they are encased in an adventitial pericystic coat (12). In our case the cardiac manifestation of the cyst was 7 years after the first diagnosis of lung involvement.

The characteristics of the right-sided cardiac hydatid cysts usually have some differences from the left-sided cysts. The left-sided cysts tend to grow subepicardial. Because of the tendency of intracavitary and subendocardial expansion of right-sided cysts, rupture is more frequent in the right ventricular cysts causing pulmonary embolus, anaphylaxis, or sudden death. If the rupture occurs into the pericardial cavity pericarditis, effusion, and cardiac tamponade can be seen (13). Because of all these risks, surgical treatment was planned for the cardiac cyst in our patient.

CONCLUSION

As a result, multiple system involvement should be kept in mind in the presence of hydatid cyst in countries where hydatid cysts are endemic like our country. CT-MRI should be performed especially in patients with liver involvement in terms of the possibility of cardiac cyst. Because of the possible complications in the presence of cardiac hydatid cyst, treatment should be surgery.

Conflict of interest : The authors declare that they have no competing interest.

Financial Disclosure: There are no financial supports.

Informed Consent: Additional informed consent was obtained from the patient's wife since the patient is dead.

REFERENCES

1. Santivanez S, Garcia HH. Pulmonary cystic echinococcosis. *Curr Opin Pulm Med* 2010;16:257-261.
2. Feki W, Ketata W, Bahloul N, et al. Secondary pleural hydatidosis: Complication of intrapulmonary echinococcosis. *Lung India* 2014;31:270-273.

3. Eckert J, Deplazes P. Biological, epidemiological, and clinical aspects of echinococcosis, a zoonosis of increasing concern. *Clin Microbiol Rev* 2004;17:107-35.
4. El Ibrahimy A, Ankouz A, Daoudi A, et al. Pelvic bone and hip joint hydatid disease revealing a retroperitoneal location. *Orthop Rev (Pavia)* 2009;1:e8.
5. Dursun M, Terzibasoglu E, Yilmaz R, et al. Cardiac hydatid disease: CT and MRI findings. *AJR Am J Roentgenol* 2008;190:226-32.
6. Ipek G, Omeroglu SN, Goksedef D, et al. Large cardiac hydatid cyst in the interventricular septum. *Tex Heart Inst J* 2011;38:719-722.
7. Kaplan M, Demirtas M, Cimen S, et al. Cardiac hydatid cysts with intracavitary expansion. *Ann Thorac Surg* 2001; 71:1587-1590.
8. Pedrosa I, Saíz A, Arrazola J, et al. Hydatid disease: Radiologic and pathologic features and complications. *Radiographics* 2000; 20:795-817.
9. Gormus N, Yeniterzi M, Telli HH, et al. The clinical and surgical features of right-sided intracardiac masses due to echinococcosis. *Heart Vessels* 2004;19:121-124.
10. Sanaei DA, Kadivar MR, Alborzi A, et al. Analysis of hospital records of children with hydatid cyst in south of Iran. *J Parasit Dis* 2017;41:1044-8.
11. Working Group WHOI International classifications of ultrasound images in cystic echinococcosis for application in clinical and field epidemiological settings. *Acta Trop* 2003;85:253-61.
12. Rinaldi F, Brunetti E, Neumayr A, et al. Cystic echinococcosis of the liver: a primer for hepatologists. *World J Hepatol* 2014;6:293-305.
13. Canpolat U, Yorgun H, Sunman H, et al. Cardiac hydatid cyst mimicking left ventricular aneurysm and diagnosed by magnetic resonance imaging. *Turk Kardiyol Dern Ars* 2011;39:47-51.