

# Outcomes of vitreoretinal surgery in patients with posterior segment intraocular foreign body

Seyhan Dikci<sup>1</sup>, Turgut Yilmaz<sup>2</sup>

<sup>1</sup>Department of Ophthalmology, Faculty of Medicine, Inonu University, Malatya, Turkey

<sup>2</sup>Department of Ophthalmology, Elazig Medical Park Hospital, Elazig, Turkey

Copyright@Author(s) - Available online at [www.annalsmedres.org](http://www.annalsmedres.org)

Content of this journal is licensed under a Creative Commons Attribution-NonCommercial 4.0 International License.



## Abstract

**Aim:** This study aims to examine the outcomes of vitreoretinal surgery (VRS) in the treatment of cases detected to have posterior segment intraocular foreign body (IOFB) due to eye trauma.

**Materials and Methods:** Files of patients who were detected to have posterior segment intraocular foreign bodies due to eye trauma and underwent VRS in our clinic between January 2014 and December 2018 were retrospectively reviewed. Patient age, sex, preoperative and final best corrected visual acuity (BCVA), initial eye examinations, nature of the foreign body and site of penetration into the eye, methods of foreign body removal, surgical methods, and complications were recorded.

**Results:** Of the 16 patients included in the study, 15 (93.7%) were male and 1 (6.3%) was female. Mean age of the cases was 32.8±13.7 (14-58) years. Foreign body was metallic in 15 eyes, and a stone in one eye. Median time between trauma and IOFB removal was 3 days. Foreign bodies were removed via an enlarged sclerotomy in 13 eyes, and a limbal incision in 3 eyes. Visual acuity improved during postoperative follow-up in 12 patients, deteriorated in three patients, and remained unchanged in one patient. Mean initial BCVA of the cases was 1.54±0.57 logMAR and mean final BCVA was 1.03±0.6 logMAR (p=0.014). Four eyes demonstrated recurrent/new retinal detachment (RD), two eyes macular scarring, one eye a transient increase in intraocular pressure, one eye aphakia, one eye hemorrhagic choroidal detachment, and one eye phthisis bulbi. Median follow-up time was 14 (3-58) months.

**Conclusion:** VRS is an effective and safe procedure for the removal of posterior segment intraocular foreign bodies; however, visual and anatomic outcomes can be affected by various factors in these cases. Macular scarring and a recurrent or new RD are associated with poor final visual outcomes.

**Keywords:** Intraocular foreign body; posterior segment; retinal detachment; vitreoretinal surgery

## INTRODUCTION

Approximately 17-41% of open-globe traumas involve intraocular foreign body (IOFB) and posterior segment IOFBs continues to be the leading cause of eye injury-related morbidity (1-3). In the classification of trauma, open globe injuries involving IOFBs are categorized separately, as the associated treatment and visual prognosis are different compared with other perforating and penetrating injuries (4,5). Posterior segment IOFBs are more likely to cause complications such as traumatic cataract, vitreous hemorrhage and retinal detachment (RD) than anterior segment IOFBs, resulting in a less favourable prognosis. Posterior segment IOFBs can also cause significant vision loss by inducing macular scarring, inflammation, endophthalmitis, and toxicity (6,7). In these patients, the visual outcome is dependent on various factors. Factors such as the presence of hyphema, vitreous hemorrhage, uveal prolapse, an afferent pupillary defect, retinal detachment, and poor initial visual acuity have been linked

to an unfavorable visual prognosis (3,8,10). Large IOFBs were also reported to be associated with a worse final best corrected visual acuity (BCVA) (8,10).

Identifying and performing the appropriate surgical approach in patients with posterior segment IOFBs are important for the anatomical and functional outcomes. Early repair of the globe is thought to maximize visual potential and reduce the risk of endophthalmitis and sympathetic ophthalmia (11). The timing of IOFB removal is controversial; however, all foreign bodies must be removed from the eye due to the risk of endophthalmitis and toxicity, except for certain exceptional cases (2,12,15). Various IOFB removal techniques have been reported by different authors. Pars plana vitrectomy (PPV) is the key surgical procedure for the removal of posterior segment IOFBs and allows direct visualization and well-controlled surgery. This study aims to evaluate the demographic and clinical characteristics and surgical outcomes of cases that underwent VRS for posterior segment IOFB.

**Received:** 30.12.2020 **Accepted:** 08.02.2021 **Available online:** 18.10.2021

**Corresponding Author:** Seyhan Dikci, Department of Ophthalmology, Faculty of Medicine, Inonu University, Malatya, Turkey

**E-mail:** [seyhandikci@gmail.com](mailto:seyhandikci@gmail.com)

## MATERIALS and METHODS

This study was approved by Inonu University Health Sciences Non-invasive Clinical Research Ethics Committee (date: 30.07.2019, approval number: 2019/286) and conducted in accordance with the Helsinki Declaration. Files of patients who presented to the Ophthalmology Department of Inonu University, Faculty of Medicine due to eye trauma and were detected to have IOFBs between January 2014 and December 2018 were retrospectively reviewed. Cases with anterior segment foreign bodies and missing data in the patient files were excluded from the study. Cases with IOFB localized in the posterior segment who were treated with VRS had undergone a complete ophthalmological examination involving patient age, sex, initial and final BCVA, intraocular pressure and biomicroscopic examination data, as well as orbital X-ray and orbital computed tomography (CT) examinations. In cases where the posterior pole could not be evaluated, B-scan ultrasounds were performed. Additionally, the nature of the IOFB, site of penetration into the eye, iris and retinal damage, presence of hyphema or vitreous hemorrhage, time between trauma and IOFB removal, duration of postoperative follow-up, surgical methods and complications were recorded.

Visual acuity of the patients was assessed using the Snellen eye chart. Visual acuity values were converted to units of log-MAR for statistical analysis. Intraocular pressure was assessed digitally prior to the operation and using Goldmann applanation tonometry in postoperative follow-up. Eyes with wound leakage underwent primary globe repair prior to PPV or combined primary globe repair and PPV where appropriate. Eyes that showed spontaneous wound closure with no leakage were treated with PPV as the first line treatment. The Birmingham Eye Trauma Terminology was utilized in the classification and identification of the ocular trauma (5). Wound site was described according to the Ocular Trauma Classification Group. Accordingly, Zone 1 injuries involve the cornea and the limbus; Zone 2 injuries extend from the limbus up to the anterior 5 mm of sclera; and zone 3 injuries extend posterior to the anterior 5 mm of sclera (4).

All cases underwent 20-gauge (G) or 23-G PPV for the removal of the foreign body. Foreign bodies were extracted from the sclera or the limbus according to the characteristics of the eye trauma and the IOFBs. IOFBs were usually removed via the limbal route in the absence of a crystalline lens; whereas in other cases, IOFBs were removed by enlarging the sclerotomy site during PPV and using a foreign body forceps. Where necessary, silicone oil endotamponade was used as an intraocular tamponade and endolaser photocoagulation was performed.

All patients who presented in the early phase were started on systemic antibiotic therapy along with topical antibiotics. One case manifested hypopyon on initial examination and was administered intravitreal antibiotics (vancomycin and ceftazidime). In all PPV procedures, an antibiotic (moxifloxacin) was added to the infusion fluid.

## Statistical Analysis

The data were tested for normality using the Shapiro-Wilk test. Normally distributed data were presented in the form of mean±standard deviation. The distributions of non-normal data and data with limited observations were presented in the form of median, minimum, and maximum values. A dependent group's t-test was used to compare dependent groups. The Mann-Whitney U test was used in the comparison of two independent groups. The level of significance was considered as 0.05 for all analyses.

## RESULTS

This study included 16 eyes of 16 patients, of which 15 (93.7%) were male and 1 (6.3%) were female. The mean age of the patients was 32.8±13.7 (14-58) years. The left eye was impacted in 10 patients, and the right eye in 6 patients. In cases where primary globe repair was performed, this procedure was performed within 24 hours following trauma. Seven eyes underwent 20-G PPV and 9 eyes 23-G PPV. There was no special reason for choosing a 20 or 23-G PPV. The vitrectomy system available in our clinic at that time was used. Primary globe repair preceded PPV in 9 eyes, PPV was performed alone in 6 eyes due to the absence of wound leakage and combined primary globe repair and PPV were performed in one eye (Case 10). The median time between trauma and IOFB removal was determined as 3 (2-90) days. The median follow-up time of the cases was 14 (3-58) months.

Nine eyes (56.3%) presented Zone 1 injuries, 4 eyes (25%) Zone 2 injuries, and 3 eyes (18.7%) Zone 3 injuries. The foreign body was metallic in 15 eyes (93.7%) and a stone in one eye (6.3%). On initial examination, 13 eyes were detected to have cataract and 3 eyes showed transparent lenses. Iris defects were detected in 4 eyes, iridodialysis in 3 eyes, and iris prolapse in one eye. One eye showed hypopyon (case 11). Eight eyes showed retinal tears/detachment, and one eye each showed retinal dialysis, retinal hemorrhage, and retinal damage. Three eyes (cases 2, 4, 10) showed macular damage. IOFBs were localized in the retina in 8 eyes and in the vitreous in 8 eyes. Figure 1 demonstrates a foreign body localized in the vitreous as visualized on orbital CT of a case. One eye (case 6) manifested symptoms of siderosis. Nine eyes underwent combined phacoemulsification/lensectomy and intraocular lens implantation, while one eye (case 4) underwent PPV and lensectomy and was left aphakic. Three eyes underwent cataract surgery in a later session. Foreign bodies were extracted via an enlarged sclerotomy in 13 eyes and the limbal route in 3 eyes. Endolaser photocoagulation was performed as an additional surgical procedure during PPV in 13 cases. Silicone oil endotamponade was administered to 10 eyes.

Recurrent retinal detachment was detected in three eyes (cases 5, 6, 11), meanwhile, one eye that had initially shown retinal hemorrhage developed hemorrhagic choroidal detachment and RD in the course of follow-up. One eye (6.3%) showed transient high intraocular pressure that responded to medical treatment.

Four eyes (25%) demonstrated transient hypotonia in the early postoperative period. Additionally, macular scarring in two eyes and aphakia in one eye can be listed among the other complications we encountered. Demographic and clinical characteristics of the patients are presented in Table 1.

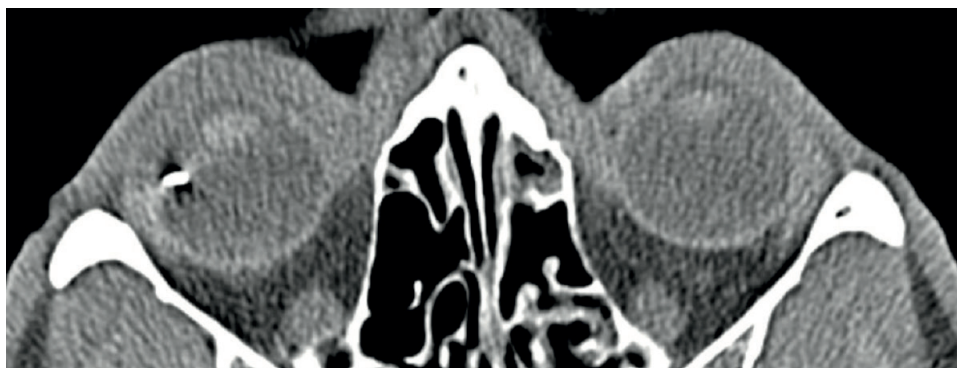
Anatomical success was achieved in 14 eyes (87.5%), while one eye (case 16) showed phthisis bulbi and another (case 6) developed chronic retinal detachment. The mean initial BCVA of the cases was  $1.54 \pm 0.57$  (0.7-2) logMAR, whereas the mean final BCVA was  $1.03 \pm 0.6$  (0-2) logMAR; and this difference was statistically significant ( $p=0.014$ ). BCVA improved in 12 eyes (75%), deteriorated in three eyes (cases 6, 11, 16) (18.7%), and remained unchanged in one eye (case 14) (6.3%). The case who showed unchanged eyesight manifested retinal detachment and haemorrhagic choroidal detachment in the second postoperative month. The first case who showed poorer visual acuity (case 6) demonstrated a recurrent retinal detachment. The second case had initially presented symptoms of endophthalmitis

and later showed a recurrent retinal detachment. The last case who showed poorer visual acuity had light perception but retinal damage as severe as loss of retinal tissue was detected during surgery; this eye manifested phthisis bulbi and visual acuity deteriorated to no light perception. The mean initial BCVA was determined to be significantly poorer in eyes detected to have iris damage, vitreous bleeding, or hyphema (respectively,  $p=0.007$ ,  $p=0.002$ ,  $p=0.002$ ), and even though the mean final BCVA of these eyes showed a decrease, there was no statistically significant difference (respectively,  $p=0.161$ ,  $p=0.091$ ,  $p=0.210$ ). The mean initial and final BCVA values were lower in eyes with retinal damage; however, there was no statistically significant difference (respectively,  $p=0.316$ ,  $p=0.078$ ). The mean initial BCVA was poorer in cases with IOFBs localized in the vitreous, whereas the mean final BCVA was poorer in cases with IOFBs localized in the retina; however, there was no statistically significant difference between two groups (respectively,  $p=0.505$ ,  $p=0.422$ ). Table 2 shows the relationship between initial and final visual acuity of the cases with respect to prognostic factors.

**Table 1. Demographic and clinical characteristics of the patients**

Case no	Gender (F/M)	Age (year)	Initial BCVA	Final BCVA	IOFB type	Zone 1,2,3	VH / Hyphema	Lens	Iris injury	Retinal injury	Complications	Removal time (days)	Follow-up time (months)
1	M	27	1.92	0.22	Stone	2	Both	Cataract	Iris defect	None	None	8	5
2	M	31	1.92	0.7	Metal	1	Both	Cataract	Iridodialysis	Macular injury	None	2	32
3	M	31	1.4	1.3	Metal	1	None	Cataract	Iris defect	Retinal injury	None	4	51
4	M	15	2	1.52	Metal	1	Both	Cataract	Iridodialysis	RD, retinal tear, macular injury	Aphakia, Macular scar formation	3	7
5	M	45	1.92	1.52	Metal	2	VH	Cataract	None	RD, retinal tear	Relapse RD	2	58
6	M	37	0.7	1.7	Metal	1	None	Cataract	None	RD, retinal tear	Relapse RD	90	29
7	M	45	1.3	0.3	Metal	1	None	Cataract	None	None	None	17	3
8	M	17	1.92	1.1	Metal	2	Hyphema	Phakic	Iris defect	Retinal tear	None	2	34
9	M	22	0.22	0.1	Metal	3	None	Phakic	None	Retinal tear	None	2	6
10	F	31	2	1.52	Metal	2	Both	Phakic	Iridodialysis	Retinal tear, macular injury	Macular scar formation	2	3
11	M	17	1	1.3	Metal	3	None	Cataract	None	RD	Relapse RD, Endophthalmitis	6	30
12	M	14	1.92	0	Metal	1	None	Cataract	None	Retinal dialysis	None	3	7
13	M	37	0.8	0.3	Metal	1	None	Cataract	None	None	None	45	7
14	M	58	1.92	1.92	Metal	1	Both	Cataract	Iris prolapse	Retinal hemorrhage	Hemorrhagic choroidal detachment, RD	2	30
15	M	48	1.7	1	Metal	1	None	Cataract	None	None	None	4	3
16	M	50	2	2	Metal	3	Both	Cataract	Iris defect	RD, retinal defect	Phthisis bulbi	2	21

BCVA: Best Corrected Visual Acuity, F: Female, IOFB: Intraocular foreign body, M: Male, RD: Retinal Detachment, VH: Vitreous hemorrhage



**Figure 1.** Foreign body as visualised on orbital computed tomography of a case

**Table 2.** The relationship between initial and final visual acuity of the cases with respect to prognostic factors

		Initial BCVA Median (Min.- Max.)	P	Final BCVA Median (Min.- Max.)	P
Retinal injury	Present (n=12)	1.92 (0.22- 2)	0.316	1.41 (0- 2)	0.078
	None (n=4)	1.5 (0.8- 1.92)		0.3 (0.22- 1)	
Iris injury	Present (n=8)	1.92 (1.4- 2)	0.007	1.41 (0.22- 2)	0.161
	None (n=8)	1.15 (0.22- 1.92)		0.65 (0- 1.7)	
Vitreous hemorrhage	Present (n=7)	1.92 (1.92- 2)	0.002	1.52 (0.22- 2)	0.091
	None (n=9)	1.3 (0.22- 1.92)		1 (0- 1.7)	
HypHEMA	Present (n=7)	1.92 (1.92- 2)	0.002	1.52 (0.22- 2)	0.210
	None (n=9)	1.3 (0.22- 1.92)		1 (0- 1.70)	
Localization of IOFB	Retina (n=8)	1.66 (0.7- 2)	0.505	1.3 (0.3- 1.7)	0.442
	Vitreous (n=8)	1.92 (0.22- 2)		0.65 (0- 0.22)	

**BCVA:** Best corrected visual acuity, **IOFB:** Intraocular foreign body, **Min.:** Minimum, **Max.:** Maximum

## DISCUSSION

Eye injuries that involve foreign bodies are usually encountered between the ages 21 and 40 and constitute a notable cause of vision loss in young adults (3). The IOFBs can be of a metallic, glass, stone, plastic, or organic nature. Metallic foreign bodies comprise the majority of IOFBs as they are of adequate hardness to reach the posterior segment and can reach a certain speed (1,16,17). In the present study, the IOFBs were metallic in 93.7% of the cases. In these cases, apart from repairing the trauma-induced damage caused by the IOFB, the treatment aims to prevent the infection, inflammation, and toxicity associated with the foreign body. The foreign body can be removed during the primary repair of the globe or in an early or late phase after the primary repair procedure. The potential advantages of early IOFB removal include a potential decrease in the risk of endophthalmitis, a decrease in the rate of proliferative vitreoretinopathy (PVR), and having the patients undergo a single surgical procedure (3,18,19). Meanwhile, early surgical intervention excludes the opportunity of a well-controlled surgery in patients with corneal edema and severe inflammation who do not have posterior vitreous detachment (20,21). On the other hand, delaying the removal of the IOFB can allow better control of the inflammation caused by the open

globe injury, better evaluation of the intraocular structures, and posterior vitreous detachment, which would facilitate the surgery (3). Rates of endophthalmitis reported after IOFB injuries are relatively low and vary between 0% and 10% (7,18,19,22). However, the IOFB must be surgically removed as soon as possible in eyes suspected of having endophthalmitis (8). In the absence of endophthalmitis, and particularly, when endoscopic surgery is not possible, surgery can be delayed until corneal edema recovers or intraocular inflammation is managed to allow better visualization during vitrectomy. This period usually lasts between 3 and 14 days (23). In the present study, the IOFBs were removed within 10 days following trauma in all cases except for three who presented to our clinic at later time. Of the patients with wound leakage, all underwent primary globe repair first and IOFB removal was performed at a second session, except for one case who underwent combined primary globe repair and PPV.

The site and method of foreign body removal must be decided by the surgeon based on their personal experience, in consideration of whether certain eye structures such as the cornea, lens and retina are damaged, and the characteristics of the foreign body. The removal of IOFBs without vitrectomy is usually not recommended as it exposes intraocular structures to an unnecessary

risk of traction (23). Advances in vitreoretinal surgery tools and surgical techniques have improved treatment success in open globe injuries involving posterior segment IOFBs. The removal of the posterior segment IOFB by PPV is associated with a lower risk of retinal detachment because of the removal of the vitreous and less collateral damage because of direct visualization and well-controlled surgery, reducing the risk of potential endophthalmitis (7,24). In addition, retinchooroidectomy can be required in the presence of intraretinal foreign body and this procedure can be performed during PPV. The use of perfluorocarbon liquids prior to moving the IOFBs during PPV helps avoid macular damage in the case that the foreign body is dropped (25). IOFBs can be removed by enlarging the sclerotomy site during vitrectomy or via the limbus. IOFBs of greater thickness are extracted via the anterior chamber instead of the sclera. Usually, a limbal approach is adopted in the absence of a crystalline lens and enlarged sclerotomy is preferred otherwise. In a study by Yuksel et al., the enlargement of the sclerotomy site in the form of a "T" or "L" was described as an effective and safe procedure for the removal of posterior segment IOFBs in cases managed with 23-gauge PPV. The cited study reported complications such as fibrin reaction in eight (22.2%) patients and elevated intraocular pressure in 12 patients (33.3%) (26). In another study, conducted by Singh et al., 14 patients who presented with limbal or corneal foreign body penetration sites and cataract were treated with 23-gauge vitrectomy and the foreign bodies were removed via the limbus (27). In our study, foreign body removal was performed by enlarging the sclerotomy in 13 eyes and via the limbus in 3 eyes.

Various factors have been reported in relation to the final visual outcome in posterior segment IOFB injuries. A visual acuity below 20/200 was reported in 25% of patients with IOFB (3,23). A poor initial visual acuity, presence of an afferent pupillary defect, vitreous bleeding, retinal detachment or retinal damage, uveal prolapse, and a large IOFB size have been reported as unfavorable prognostic factors (2,3,7-10,14,28). The probabilities of hyphema, vitreous hemorrhage, retinal bleeding and uveal prolapse increase in parallel to the weight, width and thickness of IOFBs (21). Teke et al. determined that a large foreign body size was associated with a higher risk of PVR and poorer final visual acuity (29). A study performed in China that involved a very large series found that poorer visual outcomes were linked to poorer initial VA, a larger entry wound, posterior segment IOFBs, and preexisting endophthalmitis (2). Patients who presented with RD or retinal tears and had IOFBs were found to show poorer initial and final BCVA values than those without retinal damage and this was reasoned to be due to the frequent recurrence of RD in these patients (30). A study out of Switzerland reported less favorable visual outcomes in cases with macular involvement, severe vitreous hemorrhage, poor initial VA, large IOFBs and Zone-3 injuries (31). In the present study, initial BCVA was determined to be significantly poorer in eyes with iris damage, vitreous bleeding, or hyphema, and the

final BCVA was poorer in eyes with retinal or iris damage, vitreous bleeding, or hyphema and eyes where the foreign body was localized in the retina; however, there was no statistically significant difference. This can be due to the limited number of patients included in this study.

The most common complications encountered after the removal of posterior segment IOFBs by PPV were reported to be retinal detachment (18.9%) and glaucoma (17.2%) (21). Similar to early retinal detachment, late retinal detachment was associated with a worse final BCVA (21). In our study, four eyes (25%) were found to have RD; three of these were recurrent and one appeared during follow-up despite no RD at first presentation. All of these eyes showed limited visual acuity improvement (below 1 logMAR). Of our cases, one (6.3%) showed transient high intraocular pressure that responded to medical treatment, and four (25%) showed transient hypotonia in the early postoperative period. Other complications we encountered can be listed as macular scarring in two eyes, aphakia in one eye, hemorrhagic choroidal detachment in one eye, and phthisis bulbi in one eye.

## CONCLUSION

The limitations of our study are that it is a retrospective study and there is a limited number of cases. Patients with posterior segment IOFBs can manifest quite diverse presentations and visual prognoses. Factors that influence the final visual acuity in these patients are very variable. In our study, final VA remained low in eyes that showed macular scarring and recurrent or new RD.

*Competing Interests: The authors declare that they have no competing interest.*

*Financial Disclosure: There are no financial supports.*

*Ethical Approval: This study was approved by Inonu University Health Sciences Non-invasive Clinical Research Ethics Committee (date: 30.07.2019, approval number: 2019/286) and conducted in accordance with the Helsinki Declaration.*

## REFERENCES

1. Ehlers JP, Kunimoto DY, Ittoop S, et al. Metallic intraocular foreign bodies: characteristics, interventions, and prognostic factors for visual outcome and globe survival. *Am J Ophthalmol* 2008; 146:427-33.
2. Zhang Y, Zhang M, Jiang C, Qiu HY. Intraocular foreign bodies in china: clinical characteristics, prognostic factors, and visual outcomes in 1,421 eyes. *Am J Ophthalmol* 2011;152:66-73.
3. Yeh S, Colyer MH, Weichel ED. Current trends in the management of intraocular foreign bodies. *Curr Opin Ophthalmol* 2008;19:225-33.
4. Pieramici DJ, Sternberg P Jr, Aaberg TM Sr, et al. A system for classifying mechanical injuries of the eye (globe). The Ocular Trauma Classification Group. *Am J Ophthalmol* 1997;123:820-31.

5. Kuhn F, Morris R, Witherspoon CD, Mester V. Birmingham Eye Trauma Terminology (BETT): terminology and classification of mechanical eye injuries. *Ophthalmol Clin North Am* 2002;15:139-43.
6. Falavarjani KG, Hashemi M, Modarres M, et al. Vitrectomy for posterior segment intraocular foreign bodies, visual and anatomical outcomes. *Middle East Afr J Ophthalmol* 2013;20:244-7.
7. Wani VB, Al-Ajmi M, Thalib L, et al. Vitrectomy for posterior segment intraocular foreign bodies: visual results and prognostic factors. *Retina* 2003;23:654-60.
8. Loporchio D, Mukkamala L, Gorukanti K, et al. Intraocular foreign bodies: a review. *Surv Ophthalmol* 2016;61:582-96.
9. Park JH, Lee JH, Shin JP, et al. Intraocular foreign body removal by viscoelastic capture using discovisc during 23-gauge microincision vitrectomy surgery. *Retina* 2013;33:1070-2.
10. Szijártó Z, Gaál V, Kovács B, Kuhn F. Prognosis of penetrating eye injuries with posterior segment intraocular foreign body. *Graefes Arch Clin Exp Ophthalmol* 2008;246:161-5.
11. Chu XK, Chan CC. Sympathetic ophthalmia: to the twentyfirst century and beyond. *J Ophthalmic Inflamm Infect* 2013;3:49.
12. Parke DW 3rd, Pathengay A, Flynn HW Jr, et al. Risk factors for endophthalmitis and retinal detachment with retained intraocular foreign bodies. *J Ophthalmol* 2012;2012:758526.
13. Parke DW 3rd, Flynn HW Jr, Fisher YL. Management of intraocular foreign bodies: a clinical flight plan. *Can J Ophthalmol* 2013;48:8-12.
14. Woodcock MG, Scott RA, Huntbach J, Kirkby GR. Mass and shape as factors in intraocular foreign body injuries. *Ophthalmology* 2006;113:2262-9.
15. Ahmed Y, Schimel AM, Pathengay A, et al. Endophthalmitis following open-globe injuries. *Eye (Lond)* 2012;26:212-7.
16. Imrie FR, Cox A, Foot B, Macewen CJ. Surveillance of intraocular foreign bodies in the UK. *Eye (Lond)* 2008;22:1141-7.
17. Valmaggia C, Baty F, Lang C, Helbig H. Ocular injuries with a metallic foreign body in the posterior segment as a result of hammering: the visual outcome and prognostic factors. *Retina* 2014;34:1116-22.
18. Bhagat N, Nagori S, Zarbin M. Post-traumatic Infectious Endophthalmitis. *Surv Ophthalmol* 2011;56:214-51.
19. Chaudhry IA, Shamsi FA, Al-Harathi E, et al. Incidence and visual outcome of endophthalmitis associated with intraocular foreign bodies. *Graefes Arch Clin Exp Ophthalmol* 2008;246:181-6.
20. Falavarjani KG, Hashemi M, Modarres M, et al. Vitrectomy for posterior segment intraocular foreign bodies, visual and anatomical outcomes. *Middle East Afr J Ophthalmol* 2013;20:244-7.
21. Oztaş Z, Nalcaci S, Afrashi F, et al. Posterior segment intraocular foreign bodies: the effect of weight and size, early versus late vitrectomy and outcomes *Ulus Travma Acil Cerrahi Derg* 2015;21:496-501.
22. Chang CH, Chen CL, Ho CK, et al. Hospitalized eye injury in a large industrial city of South-Eastern Asia. *Graefes Arch Clin Exp Ophthalmol* 2008; 246:223-8.
23. Guevara-Villarreal DA, Rodríguez-Valdés PJ. Posterior Segment Intraocular Foreign Body: Extraction Surgical Techniques, Timing, and Indications for Vitrectomy *J Ophthalmol* 2016;2016:2034509.
24. Chow DR, Garretson BR, Kuczynski B, et al. External versus internal approach to the removal of metallic intraocular foreign bodies. *Retina* 2000;20:364-9.
25. Shah CM, Gentile RC, Mehta MC. Perfluorocarbon liquids' ability to protect the macula from intraocular dropping of metallic foreign bodies: a model eye study. *Retina* 2016;36:1285-91.
26. Yuksel K, Celik U, Alagoz C, et al. 23 Gauge pars plana vitrectomy for the removal of retained intraocular foreign bodies. *BMC Ophthalmol* 2015;15:75.
27. Singh R, Bhalekar S, Dogra MR, Gupta A. 23-gauge vitrectomy with intraocular foreign body removal via the limbus: an alternative approach for select cases. *Indian J Ophthalmol* 2014;62:707-10.
28. Acar U, Tok OY, Acar DE, Burcu A, Ornek F. A new ocular trauma score in pediatric penetrating eye injuries *Eye (Lond)* 2011;25:370-4.
29. Teke YM, Onal S, Taskintuna I, et al. Intraoküler yabancı cisimlerin neden olduğu oküler yaralanmalarda prognostik faktörler. *Ret-Vit* 2003;11:228-34.
30. Mukkamala LK, Soni N, Zarbin MA, et al. Posterior Segment Intraocular Foreign Bodies: A 10-Year Review *Ophthalmology Retina* 2017;1:272-7.
31. Valmaggia C, Baty F, Lang C, Helbig H. Ocular injuries with a metallic foreign body in the posterior segment as a result of hammering: the visual outcome and prognostic factors. *Retina* 2014;34:1116-22.