



## Fascioliasis: Clinical presentation and treatment of three cases

Hakan Sezgin Sayiner<sup>1</sup>, Sadik Akgun<sup>2</sup>, Selcuk Aksoz<sup>3</sup>, Seda Guvenc<sup>4</sup>

<sup>1</sup>Adiyaman University, Faculty of Medicine, Training and Research Hospital Department of Clinical Infectious Diseases and Medical Microbiology, Adiyaman, Turkey

<sup>2</sup>Adiyaman University, Faculty of Medicine, Training and Research Hospital Department of Medical Microbiology, Adiyaman, Turkey

<sup>3</sup>Adiyaman Training and Research Hospital Department of Clinical Infectious Diseases and Medical Microbiology, Adiyaman, Turkey

<sup>4</sup>Adiyaman University Infection Control Nurse, Adiyaman, Turkey

### Abstract

**Aim:** For the diagnosis of *Fasciola hepatica* disease first step is the direct microscopic examination of feces with clinical finding. In addition to the microscopic diagnosis, radiological examination, serological methods and ELISA method are used for the diagnosis of extra-intestinal helminth infections. If these investigations are not enough for diagnosis, surgical intervention and pathological examination can be required.

**Materials and Methods:** In addition to the clinic symptoms and biochemical and hematological lab tests of three women who admitted to our hospital presenting with positive *F. hepatica* Indirect Hemagglutination (IHA) in microscopic and radiological examination, findings consistent with *F. hepatica* were detected in these patients and the difference between the starting time of symptoms and starting time of treatment has been emphasized.

**Results:** There was no animal feeding history but a history of eating fresh vegetables in our case back grounds. Malignancy was suspected after the initial of symptoms in three of our cases and surgery was performed for two cases and the result of biopsy was compatible with abscess. *F. hepatica* eggs were seen in direct microscopic investigation in one case. Cyst hydatid IHA test was detected positive at high titer in two cases. Eosinophilia was found in three cases as well and radiological findings were compatible with *Fasciola* infection. In our cases where *Fasciola* IHA test was positive, the duration between beginning of symptoms and diagnosis was approximately one to three months.

**Conclusions:** Our results suggest that to confirm the diagnosis *F. hepatica*, microbiological, serological and radiological tests should be performed.

**Keywords:** Cross Reaction; *Fasciola*; Diagnosis.

## INTRODUCTION

Fascioliasis the last host in the parasite's life cycle in humans and the trematode is a zoonotic disease, which is incidentally the last host in the parasite's lifecycle. *Fasciola hepatica* can infect many mammalian host species particularly sheep, goats and cattle(1). People receive metacercariae *Fasciola* by eating uncooked fresh water vegetables (2). It is estimated that 17 million people are infected with *Fasciola* worldwide (3). Fascioliasis is very rare in our country; about 25 cases had been reported in Turkey by 1991 (4).

Received: 03.09.2016

Accepted: 08.12.2016

### Corresponding Author

Hakan Sezgin Sayiner  
Adiyaman University, Faculty of Medicine, Training and Research Hospital Department of Clinical Infectious Diseases and Medical Microbiology, Adiyaman, Turkey  
E-mail: drhssayiner@yahoo.com

There is no benefit to the early stage of the infection fascioliasis diagnosis offecal examination due to the occasional disposal of eggs from the channel (5). It is therefore necessary to examine at least two samples taken at different times in the days following the stool samples. Observing the helminth eggs is important for the diagnosis in the direct microscopic examination.

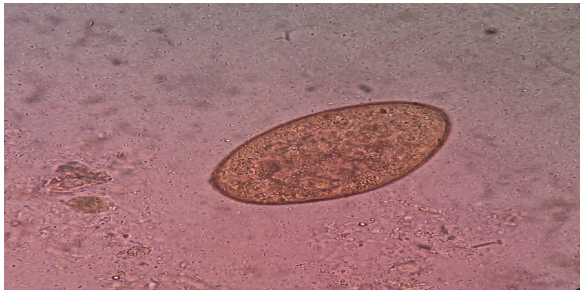
However, this is not always possible. Because the serological test for the diagnosis of fascioliasis is very sensitive, it gives cross-reaction with echinococcosis infection from other parasitic diseases (6). In addition to laboratory findings for the diagnosis of fascioliasis, radiological findings are important (7).

We aim to emphasize the difficulties encountered in reaching a diagnosis and the difference between the onset of symptoms and time of treatment for three patients admitted to our hospital whose findings were consistent with *F. hepatica* in microscopic and radiological examination in addition to *F. hepatica* indirect hemagglutination (IHA) positivity.

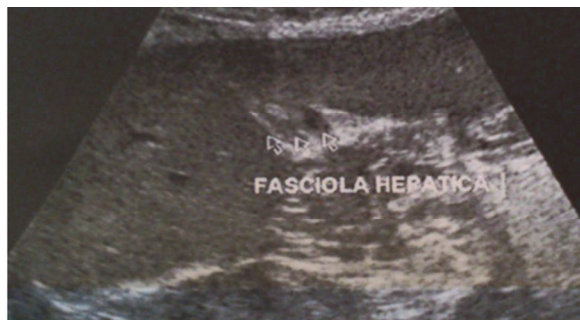## MATERIALS and METHODS

Our cases were women aged 34, 36, and 58. In our cases there was no history of animal feed but a history of eating fresh vegetables. The time between the onset of symptoms and diagnosis was about one to three months.

**Case 1:** Liver biopsy was performed with suspected malignancy after radiological examination of a 58-year-old female patient admitted to our hospital with complaints lasting one month of ongoing abdominal pain, nausea and vomiting. Pathological examination revealed an abscess formation. Multifocal hypodense areas were observed containing curvilinear forms in both lobes of the lung in contrast enhanced CT examination and the image was reported as associated with infection. Eosinophilia, mild anemia and slight increase in C-reactive protein (CRP) levels were found. Alkaline phosphatase (ALP) and gamma glutamyl transferase (GGT) levels were found high in the laboratory tests. *F. hepatica* eggs were found in microscopic examination of the stool (Figure 1). Titer in the *F. hepatica* (IHA) test was 1/320. Abdominal ultrasound (USG) was performed again because fascioliasis preliminary diagnosis of suspected hyperechoic live parasites was detected to contain hypoechogenity of internal gallbladder lumen (Figure 2). The patients' Fasciola should be diagnosed a month after symptom onset and treatment started. We started to give triclabendazol 10-12 mg / kg / day to the patient for two consecutive days. At the end of the month control Fasciola IHA was seen as 1/160. The clinical and laboratory findings of the patient were fixed.



**Figure 1.** *Fasciola hepatica* eggs image with 400X magnification of microscopic at the second time of unpainted stool specimens.



**Figure 2.** (live parasites) hypoechogenity of internal in Gallbladder lumen

**Case 2:** USG was performed because of clinical signs in the 34-year-old female patient admitted to the hospital with complaints lasting one month of on going abdominal pain, nausea and vomiting. Antibiotic therapy was started with suspected liver abscess in abdomen USG. Clinical and radiographic improvement was not observed in the patient inspite of antibiotic treatment. Liver biopsy of the patient was performed for the diagnosis of malignancy. Pathological examination was reported as consistent with abscess formation. Eosinophilia, anemia, and slight increase in CRP levels and sedimentation were found. ALP and GGT levels were found at high levels in the laboratory tests. Titer in Hydatid IHA test was positive (titer, 1:320) and *F. hepatica* IHA test was also detected as positive (titer, 1:1280).

For the differential diagnosis, no evidence of parasites and parasite eggs was found. The right posterior lobe of the liver appeared heterogeneous according to the ultrasound examination report and the size of the biggest segment was 4 in 14 mm and in the peripheral there was a hypoechoic rim in which hypoechoic lesions were partly present in cystic appearance and post operative changes were reported as developing abscess cavities. Abdomen USG examination was repeated for the differential diagnosis of *F. hepatica* with the present findings. Triclabendazole treatment was started because abdominal USG findings consistent with *F. hepatica* were determined. Symptoms were reduced after treatment. As a result, patients with Fasciola should be diagnosed a month after symptom onset and treatment started. We started to give 10–12 mg/kg/day triclabendazole to the patients for two consecutive days. At the end of the month, control Fasciola IHA was seen as 1/160 and Hydatid IHA test was detected as 1/160. The clinical and laboratory findings of the patient were fixed.

**Case 3** Meaningful results could not be found after two-month examination and the patient, 36 years old, who applied with stomachache, nausea and vomiting complaints for approximately two months after the symptoms started, could not be diagnosed. The patient presenting with symptoms was assessed in the infectious diseases clinic. Eosinophilia, sedimentation and slight increase in CRP and GGT levels were found in the laboratory tests and titer in Hydatid IHA test was positive (titer,1:1280). In the liver hypoechoic, lobulated patchy areas were scattered in several areas and the largest segmentin 7-8 was determined as 29x29 mm according to the parenchyma in the performed USG examination. Reactive characterized lymph nodes, the largest being 14.5x7.7 mm, were detected at liver hilus. *F. hepatica* was detected positively at IHA 1/1280 titer for discriminant diagnosis. The parasite and its eggs were not seen in direct microscopic investigation of the stool. We started to give 10–12 mg/kg/day triclabendazole to the patient for two consecutive days. At the end of the month, control Fasciola IHA was seen as 1/160 and Hydatid IHA test was detected as 1/160. The clinical and laboratory findings of the patient were fixed.

## RESULTS

In patients with a combination of the triad abdominal pain, eosinophilia and suspected lesion at the liver in radiological examination, *F. hepatica* infection should be suspected. Incorrect positive results can be seen because of cross reactions for some diseases when using serological diagnostic methods. This situation can become problematic for diagnosis. Tests including microbiological, serological and radiological should be performed on the patients to detect the diagnosis.

## DISCUSSION

Different clinical, laboratory and radiological findings can confront us with respect to a patient's immune response and infection phases in fasciola infections. Although most common eosinophilia was detected in this patient group, in Kaya and friends' (8) study, leukocytosis was mostly detected in laboratory investigations. If there is propagation in the biliary tract, increment of ALP and GGT enzyme was often detected. Between 2008 and 2010 in the Tas Cengiz et al. Study (9), in 93.3% of the 89 patients with *F. hepatica*, abdominal pain was detected by ELISA, and in 89% of the patients eosinophilia was detected.

In the Kecik Bosnak et al. study (10) between 2009 and 2014, 22 patients in whom fascioliasis was detected with IHA were examined and in all of the patients with fascioliasis in hepatitis phase fascioliasis (19 patients) eosinophilia was detected but it was detected in only two of them in the biliary phase.

There were also similar laboratory findings in our study. In the diagnosis of *F. hepatica*, when there are parasite eggs in the stool microscopic examination it has a diagnostic feature. However, monitoring these eggs in direct microscopy is hard with respect to often intermittent excretion. Therefore, serologic tests have an important role as helper diagnosis method for these patients. Parasite infection was investigated using the ELISA method in a study by Sakru and his team (11) who had 226 cases with pre-diagnosis of hydatidosis. While seropositivity was found in 96 cases (42.4 %) for *Echinococcus granulosus*, in five cases (2.2 %) seropositivity was found for *F. hepatica*. Radiological examination was performed for these five cases and compatible findings in three cases with fascioliasis were detected. Stool microscopic examination was performed in these five cases and *F. hepatica* eggs were shown in two cases.

In the Tas Cengiz and et al. study, 89 patients in whom *F. hepatica* was detected with ELISA were examined. *F. hepatica* eggs were seen in 29 patients on stool examination (9). In our study, in two of three cases diagnosed as fascioliasis at radiologic investigation with USG, an image compatible with fascioliasis was detected with the IHA method. However, *F. hepatica* eggs were shown with direct microscopic investigation of the stool in only one case. For that reason, diagnosis was reached with diagnostic tools that are serologic, microscopic and radiologic methods, all of which confirmed our cases.

Serologic tests are used as the most common diagnostic tool for fascioliasis diagnosis. Although these tests are sensitive, they can often give cross reactions with other parasitic infections due to the tests of high level sensitiveness (6). Antigens, which are in cyst hydatid, were detected with similarly acquire dantigens from Fasciola infected cattle in this study (12). It was thought that this antigenic similarity can be caused by cross reactions. It is questionable that in the early stages of fascioliasis infection, depending on interval excretion of eggs from the channel, the benefit of the stool examination in the diagnosis alone is controversial (5). However, in a study made by Sakru et al. (13), sighting of eggs in the stool and / or duodenal tubing material and the sighting of *F. hepatica* adult form in pathological biopsy specimens were observed and it was diagnosed using the ELISA method in addition to the specific findings belonging to the fascioliasis in the radiological diagnosis. In patients of the control group known to have had a previous parasitic infection, with an ELISA test, cross-reactivity was detected in three patients. There was a cyst in one of these patients and in two of them it was found that the cross-reaction developed due to Toxocariasis. In accordance with these results, the ELISA test is considered to be an applicable and easy serological method. It was thought that this method is not enough alone at discrimination of the disease according to micro ELISA test results that were scanned with micro ELISA test from patients diagnosed with *F. hepatica* and *Echinococcus granulosus* in a study by Kaya and friends (14). However, ELISA results could not be assessed for our patients because ELISA tests could not be made at our hospital. High titer positivity was detected serologically both in *F. hepatica* IHA test and in echinococcosis IHA test in a study of Ozel and his team (15). Hightiter positivity in the echinococcosis IHA test was diagnosed in fasciola in our cases. There were a few cases that belonged to *F. hepatica* until the 1990s, but there has since been an increase in the number of cases. These patients had serologic tests and additionally analytical tests processes were applied in some cases during diagnosis. 52 *F. hepatica* patients were monitored between 1995 and 2000 at Akdeniz University and post-operative patients' gallbladder samples were investigated. After investigation, *F. hepatica* diagnosis was finalized for 40 patients (4). Although *F. hepatica* diagnosis was thought initially at imaging techniques, malignancy was excluded by making invasive processes on patients with malignancy suspicion (16).

In the study of Kecik Bosnak et al. (10), 22 patients in whom fascioliasis was diagnosed with IHA were examined, and live parasites in the biliary phase were removed through endoscopic retrograde cholangiopancreatography.

Since malignancy and abscess discrimination could not be diagnosed with radiological findings during diagnosis in two of our cases, liver biopsy was performed on patients as an invasive diagnosis method. Malignancy was excluded after biopsy. *F. hepatica* diagnosis was clarified with iterative radiologic investigation and serological diagnosis method in our patients.

## CONCLUSION

Because physicians in areas where the infection is not endemic do not have enough clinical and laboratory experience it can be said that the number of cases is higher than that reflected in the data. Abdominal pain, eosinophilia and radiological examinations in patients detected with suspicious lesions with a combination of the triad in the liver should be astimulus for the diagnosis of infection. It is recommended that microbiological, serological and radiological tests be used to confirm the diagnosis in these patients.

## REFERENCES

1. Mas-Coma MS, Esteban JG, Bargues MD. Epidemiology of human fascioliasis: a review and proposed new classification. *Bull World Health Organ* 1999;77(4):340-6.
2. Sithithaworn P, Sripa B, Kaewkes S, Haswell-Elkins M, Food-borne trematodes. In Cook G.C and Zumla A.I, eds. *Manson's tropical diseases*, 22nd edition Saunders, London, United Kingdom 1998. p. 1461-76.
3. Mas-Coma S, Valero MA, Bargues MD. Chapter 2. Fasciola, lymnaeids and human fascioliasis, with a global overview on disease transmission, epidemiology, evolutionary genetics, molecular epidemiology and control. *Adv Parasitol* 2009;69:41-146.
4. Çubuk M, Kabaalioglu A, Çeken K, Çevikol C, Arslan G, Lüleci E, Hepatik fascioliasis: BT bulguları ve uzun dönem izlem sonuçları. *Tanısal ve Girişimsel Radyoloji Dergisi* 2001;7:529-34.
5. O'neill SM, Parkinson M, Strauss W, Angles R, Dalton JP. Immunodiagnosis of Fasciola hepatica infection (fascioliasis) in a human population in the bolivian altiplano using purified cathepsin I cysteine proteinase. *Am. J. Trop. Med. Hyg* 1998;58(4): pp. 417-23.
6. Hassan MM, Farghaly AM, el-Gamal RL, el-Ridi AM. Cross-reactions in immunodiagnosis of patients infected with Schistosoma, Fasciola and Heterophyes using ELISA. *J Egypt Soc Parasitol* 1989;19(2 Suppl):845-51.
7. Kabaalioglu A, Cubuk M, Senol U, Cevikol C, Karaali K, Apaydin A, et al, Fascioliasis: US, CT, and MRI findings with new observations. *Abdom Imaging* 2000;25:400-4.
8. Kaya M, Bestas R, Cetin S. Clinical presentation and management of Fasciola hepatica infection: single-center experience. *World J Gastroenterol* 2011;17(44):4899-904.
9. Taş Cengiz Z, Yılmaz H, Dülger A.C, Akdeniz H, Karahocagil MK, Çiçek M. Seroprevalence of human fascioliasis in Van province, Turkey. *Turk J Gastroenterol* 2015; 26(3):259-62.
10. Boşnak VK, Karaoğlan I, Sahin HH, Namiduru M, Pehlivan M, Okan V, et al. Evaluation of patients diagnosed with fascioliasis: A six-year experience at a university hospital in Turkey *J Infect Dev Ctries* 2016;10(4):389-94.
11. Şakru N, Korkmaz M, Demirci M, Kuman A, Ok UZ. Fasciolosis in Echinococcosis Suspected Cases *Türkiye Parazitoloj Derg* 2011;35(2):77-80.
12. Yokananth S<sup>1</sup>, Ghosh S, Gupta SC, Suresh MG, Saravanan D. Characterization of specific and cross-reacting antigens of Fasciola gigantica by immunoblotting *parasitol Res* 2005;97(1): 41-8.
13. Şakru N, Korkmaz M, Aydinten Kuman HA, Comparison of two different enzyme immunoassay in the diagnosis of fasciola hepatica infections. *Microbiol Bul* 2004;38(1-2):129-35.
14. Kaya M, Beştaş R, Çiçek M, Önder A, Kaplan MA, The value of micro-ELISA test in the diagnosis of Fasciola hepatica infection. *Türkiye Parazitoloj Derg* 2013;37(1):23-7.
15. Ozel BD. Yagbasan A, Karaman A. An uncommon liver mass and hypereosinophilia: acute fascioliasis. *J Med Cases* 2013;4(12):785-8.
16. Baş B, Ünlü M, Dinç B, Oymacı E, Çoker A. A case of "Fasciola hepatica" diagnosed by surgery. *Akademik Gastroenteroloji Dergisi* 2015;14(2):75-8.