

## Endodontic Treatment of Three-Rooted Maxillary First Premolar: A Case Report

*Üç Köklü Maksiller Birinci Premoların Endodontik Tedavisi: Bir Olgu Sunumu*

Mevlüt Sinan OCAK, Fuat AHMETO LU

Inönü Üniversitesi Diş Hekimliği Fakültesi Endodonti AD, Malatya

### Abstract

The root canal morphology of maxillary first premolar teeth is highly variable, but it is rare to find tree roots. This case describes the presence of tree roots in maxillary first premolar and the successful clinical management of this tooth. The tooth was anesthetized and isolated with a rubber-dam, and access to the pulp chamber was achieved using a round diamond bur. The working lengths of each canal were estimated with an apex locator. The canals were instrumented with Profile (Tulsa Dental Products, Tulsa, OK) under irrigation with 5.25% sodium hypochlorite (NaOCl) then dried with sterile paper points. The root canals were filled with AH Plus and gutta-percha points using the lateral condensation technique.

**Key Words:** Maxilla, bicuspid, root canal therapy, root canal obturation

### Özet

Maksiller birinci premolar dişlerin kök kanal morfolojileri oldukça değişken fakat üç kök bulunması nadirdir. Bu vaka raporu, maksiller birinci premolar dişte üç kök bulunmasını ve bu dişin başarılı klinik tedavisini anlatmaktadır. Diş anestezisi yapıldı ve bir rubber-dam ile izole edildi ve elmas bir rond frez ile pulpa odasına giriş sağlandı. Her kanal için çalışma uzunluğu bir apeks bulucu ile ölçüldü. Profile (Tulsa Dental Products, Tulsa, OK) kullanılarak kanallar %5.25 sodyum hipoklorit (NaOCl) irrigasyonu altında prepare edildi sonrasında steril kağıt konilerle kurulandı. Kök kanalları AH Plus ve gutta-perka konlarıyla lateral kondensasyon tekniği kullanılarak dolduruldu.

**Anahtar Kelimeler:** Maksilla, biküspit, kök kanal tedavisi, kök kanalını tıkama

### Introduction

Anatomic variations present a challenge for clinicians trying to completely clean and shape root canal. The primary cause of periradicular pathosis is pathogens residing in incompletely-treated or non-treated root canals (1), and possessing the knowledge of possible variations in the internal anatomy of human teeth is important to achieving successful endodontic treatment (2). Hence, clinicians must be cognizant of extra roots and canals when formulating a root canal treatment. Undetected extra roots and canals will lower the success rates of endodontic treatments. Before endodontic treatment, careful radiographic and clinical examinations should be performed to gain knowledge about localization of undetected roots or canals.

Maxillary premolars were investigated for anatomical variations in several studies (3-6). The root canal morphology of maxillary first premolars is highly variable, but it is rare to find three roots. The incidence of maxillary premolars with three root canals varies from 0.5% to 6% (7-9) and the three roots generally have separated canals (10). A recent study of 150 extracted maxillary first premolars revealed 60 teeth with one root (40.0%), 85 teeth with two roots (56.7%), and five teeth with three roots (3.3%) (11). Three-rooted maxillary premolars are similar to maxillary molars, and are sometimes called "small molars" or "radiculous" (12, 13).

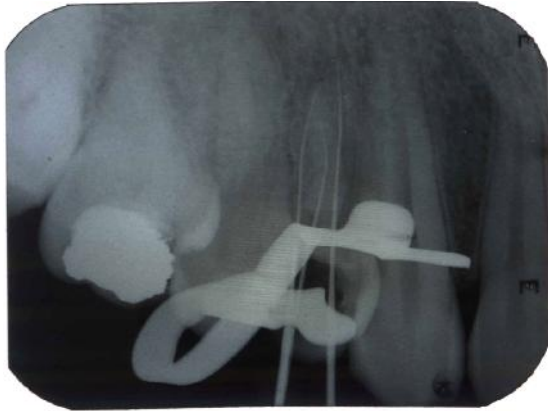The purpose of this clinical report is to describe the treatment of a rare case of a maxillary first premolar with three roots that was detected during a routine root canal treatment.

### Case Report

A healthy 28-year-old male patient was referred to the Department of Endodontics, Inonu University Faculty of Dentistry, having spontaneous pain in tooth 14. Clinically, there was a deep carious lesion at the distal surface of the tooth. The tooth was sensitive to cold and electronic pulp testing, with responses indicating irreversible pulp damage. A preoperative periapical radiograph confirmed the presence of a carious lesion on the distal surface of the maxillary first premolar.

The patient was given a local anesthetic by periapical infiltration and the tooth was isolated with rubber dam. All caries were removed and an access cavity was completed. After removing the coronal pulp, all three canals were explored with 10 K file. The working length was measured with an apex locator and confirmed with a radiograph (Figure 1). The root canals were prepared manually by a 20 K file. The remaining preparation was completed with Profile (Tulsa Dental Products, Tulsa, OK) with copious irrigation using 5.25% NaOCl.

The root canals were dried with sterile paper points and obturated by laterally condensed gutta-percha (Roeko, Germany) and AH Plus (Dentsply Maillefer,



**Figure 1.** Determination the working length

### Discussion

Because the primary causes of periradicular pathosis is pathogens residing in the incompletely treated or untreated root canals (1) achieving an acceptable hermetic root filling requires properly cleaned and shaped canals. Variation in root canal morphology may lead to some difficulties including undetermined roots or canals during root canal treatment (14). To complete the cleaning and shaping of the canals, clinicians should have knowledge of the anatomy of the teeth and their possible configurations (15).

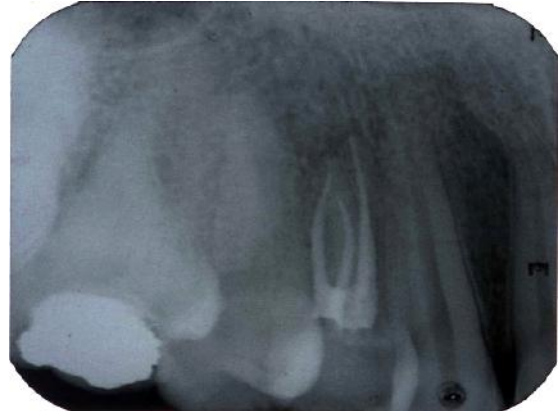
The diagnosis of additional roots or canals in maxillary premolars can often be difficult using routine preoperative radiographs; therefore, the preoperative radiographs should be carefully examined to facilitate successful endodontic treatment (16). While periapical radiographs show two-dimensional images of three-dimensional root canal systems, the careful interpretation of a radiograph may reveal anatomical details of a root canal system. In line with this suggestion, if a radiograph shows a sudden narrowing or even a disappearing pulp space, the canal diverges at that point into two parts that may either remain separate or merge before reaching the apex (17). If the pulp chamber appears to deviate from normal configurations and seems to be either triangular in shape or too large on a mesio-distal plane, more than one root canal should be suspected (18).

Enhanced illumination and magnification may help dentist to visualize the treatment site and aid to locate root canal orifices (19). The higher magnification and illumination can be useful for access cavity preparation, instrumentation and obturation (20).

### Conclusions

Successful root canal treatment can be achieved with the aid of well-cleaned and -shaped root canals. Teeth with anatomical variations present a challenge for clinicians and will risk the success of endodontic treatment due to the fact that unlocated roots or canals will compromise the treatment. A careful, detailed inspection of the pulp

Switzerland) root canal sealer (Figure 2). Endodontic treatment was completed in a single appointment.



**Figure 2.** Obturated root canals

chamber floor is a helpful procedure for locating suspected roots or canals. Another important aid in locating root canals is the routine use of loops and dental operating microscopes to enhance lighting and visibility (20,21), but the most essential elements are scheduling sufficient time for treatment and simply being patient.

### References

1. Lin LM, Rosenberg PA, Lin J. Do procedural errors cause endodontic treatment failure? *J Am Dent Assoc.* 2005; 136(2):187-93;
2. Erdemir A, Erdemir EO. Maxillary First Molar with Unusual Root Canal System: A Case Report. *Turkiye Klinikleri J Dental Sci* 2005; 11(1):24-28
3. Vier-Pelisser FV, Dummer PM, Bryant S, Marca C, Só MV, Figueiredo JA. The anatomy of the root canal system of three-rooted maxillary premolars analyzed using high-resolution computed tomography. *Int Endod J.* 2010; 43(12):1122-31.
4. Awawdeh L, Abdullah H, Al-Qudah A. Root form and canal morphology of Jordanian maxillary first premolars. *J Endod.* 2008; 34(8):9569-61.
5. Sert S, Bayirli GS. Evaluation of the root canal configurations of the mandibular and maxillary permanent teeth by gender in the Turkish population. *J Endod.* 2004; 30(6):391-398.
6. Atieh MA. Root and canal morphology of maxillary first premolars in a Saudi population. *J Contemp Dent Pract.* 200; 9(1):46-53.
7. Bellizzi R, Hartwell G. Radiographic evaluation of root canal anatomy of in vivo endodontically treated maxillary premolars. *J Endod.* 1985; 11(1):37-9.
8. Carns EJ, Skidmore AE. Configurations and deviations of root canals of maxillary first premolars. *Oral Surg Oral Med Oral Pathol.* 1973; 36(6):880-886.
9. Pineda F, Kuttler Y. Mesiodistal and bucco lingual roentgenographic investigation of 7,275 root canals. *Oral Surg Oral Med Oral Pathol.* 1972; 33(1):101-110.
10. Vertucci FJ, Gegauff A. Root canal morphology of the maxillary first premolar. *J Am Dent Assoc.* 1979; 99(2):194-198.

11. Chaparro AJ, Segura JJ, Guerrero E, Jiménez-Rubio A, Murillo C, Feito JJ. Number of roots and canals in maxillary first premolars: study of an Andalusian population. *Endod Dent Traumatol.* 1999; 15(2):65-7.
12. Maibaum WW. Endodontic treatment of a "radiculous" maxillary premolar: a case report. *Gen Dent.* 1989; 37(4): 340-341.
13. Goon WW. The "radiculous" maxillary premolar: recognition, diagnosis, and case report of surgical intervention. *Northwest Dent.* 1993; 72(2): 31-33.
14. Soares JA, Leonardo RT. Root canal treatment of three rooted maxillary first and second premolars-a case report. *Int Endod J.* 2003; 36(10): 705-10.
15. Maden M, Orhan EO. Root canal treatment of mandibular central and lateral incisors with two root canals: case report. *SDÜ Tıp Fak Derg* 2009; 16(4):27-31.
16. Javidi M, Zarei M, Vatanpour M. Endodontic treatment of a radiculous maxillary premolar: a case report. *J Oral Sci.* 2008; 50(1):99-102.
17. Vertucci FJ. Root morphology of mandibular premolars. *J Am Dent Assoc*1978; 97(1):47-50.
18. Al-Fouzan KS. The microscopic diagnosis and treatment of a mandibular second premolar with four canals. *Int Endod J.* 2001; 34(5):406-410.
19. Coutinho Filho T, La Cerda RS, Gurgel Filho ED, de Deus GA, Magalhães KM. The influence of the surgical operating microscope in locating the mesiolingual canal orifice: a laboratory analysis. *Braz Oral Res.* 2006; 20(1):59-63.
20. Arisu HD, Alacam T. Diagnosis and treatment of three-rooted maxillary premolars. *Eur J Dent.* 2009; 3(1):62-6
21. Al-Abdulwahhab B, Al-Harhi M, Al-Fayez S, Al-Shanti F, Attar R. Maxillary first premolar with three canals: case report. *Smile Dental Journal* 2010; 5(3):34-6.

**letî im**  
Mevlüt Sinan OCAK  
nönü Üniversitesi Di Hekimli i Fakültesi  
Endodonti AD, Malatya  
sinanocak@yahoo.com