

# Atypical leiomyoma of the falciforme ligament of the liver

Nidal Iflazoglu<sup>1</sup>, Vahide Baz<sup>2</sup>, Goksel Tuzcu<sup>3</sup>

<sup>1</sup>Malatya Education and Research Hospital, Clinic of, Surgical Oncology, Malatya, Turkey

<sup>2</sup>Malatya Education and Research Hospital, Clinic of, Pathology, Malatya, Turkey

<sup>3</sup>Malatya Education and Research Hospital, Clinic of, Radiology, Malatya, Turkey

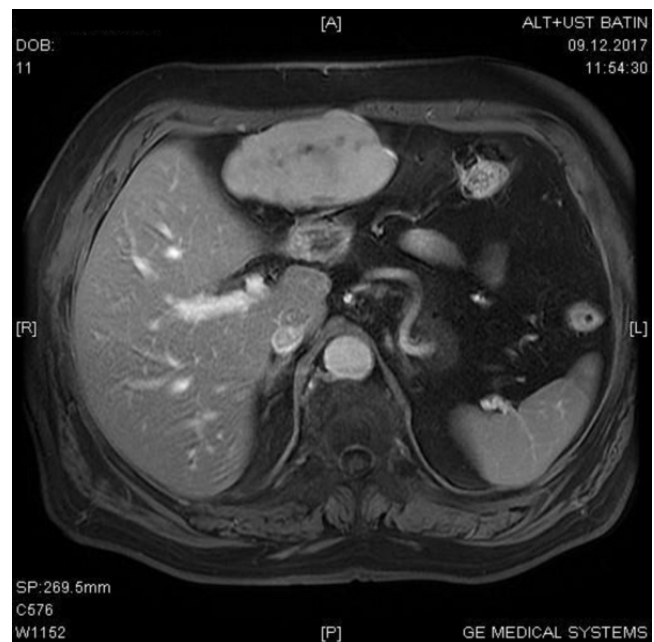
Copyright © 2018 by authors and Annals of Medical Research Publishing Inc.

## Dear Editor,

Falciform ligament tumors are quite rare. Most of these tumors, which present with atypical symptoms, are benign and they are rarely malignant, and may be cystic or solid (1-4). In this article, we presented a case of atypical leiomyoma of the falciform ligament, which was diagnosed while investigating the cause of non-specific complaints. A 64-year-old male patient was admitted to the emergency room due to the complaint of stomach ache. He has been taking oral anti-diabetic drugs for 15 years due to diabetes mellitus. He had undergone a surgical operation for a right femur head fracture 1 year ago. There was no other remarkable feature in the patient's or his family's past medical history. Complete blood count and biochemical parameters including tumor markers (CEA and CA19-9) were within normal limits. Abdominal ultrasonography revealed a hypoechoic uniform mass lesion in the midline of the abdominal anterior wall, which was 10 cm in diameter. Upper abdominal magnetic resonance imaging revealed a mass with a uniform and lobulated contour, of 107 mm in diameter, with a clear contrast enhancement, adjacent to the left lobe of the liver, abdominal wall and the transverse colon, in the anterior part of the stomach antrum and in the vicinity of the omentummajus region (Figure 1 and 2).

On the upper gastrointestinal endoscopy of the patient, severe antral gastritis was detected together with helicobacter pylori infection. Colonoscopy examination was normal. Thorax and upper and lower abdominal computed tomography revealed no foci other than the mass described on the magnetic resonance imaging. A tumor originating from the falciform ligament was detected during laparotomy. The mass was resected together with the falciform ligament according to the principles of tumor surgery (Figure 3). After the operation material was kept in 10% formaldehyde, the macroscopic examination reported

a light yellow colored operation material with partial fatty tissue on the mass, which had a semi-firm consistency and was partially fibrous and partially nodular in structure.



**Figure 1.** In the transvers plane, solid mass adjacent to the anterior abdominal wall and liver (magnetic resonance)

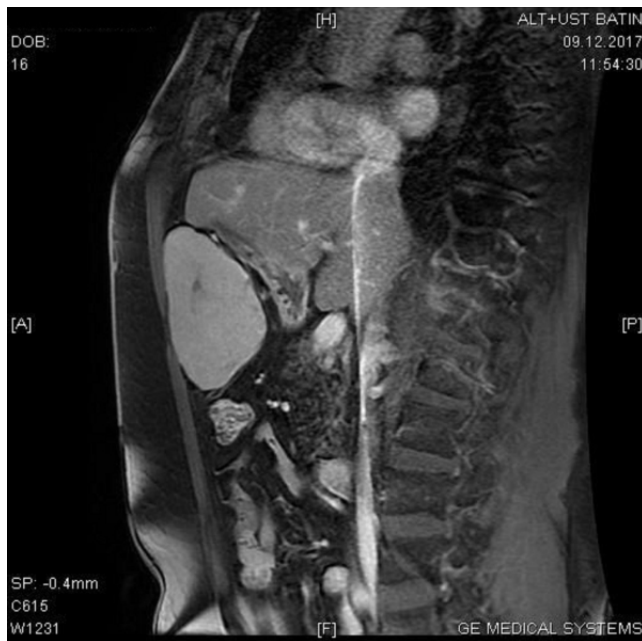
On the microscopic examination, the operation material was positive for vimentin, sma, and desminkaldesmon, whereas it was negative in terms of DOG-1, CD-99, S100, CD-117 and B catenin. The Ki-67 proliferation index was 5-11%. Histopathological diagnosis of atypical leiomyoma was established according to these findings (Figure 4). There was no major complication in the postoperative period and the patient was discharged on the fifth postoperative day. All clinical, laboratory and radiological findings were normal at the first year follow-up visit and the patient's informed consent was obtained. Tumors of

Received: 29.09.2018 Accepted: 08.10.2018 Available online: 11.10.2018

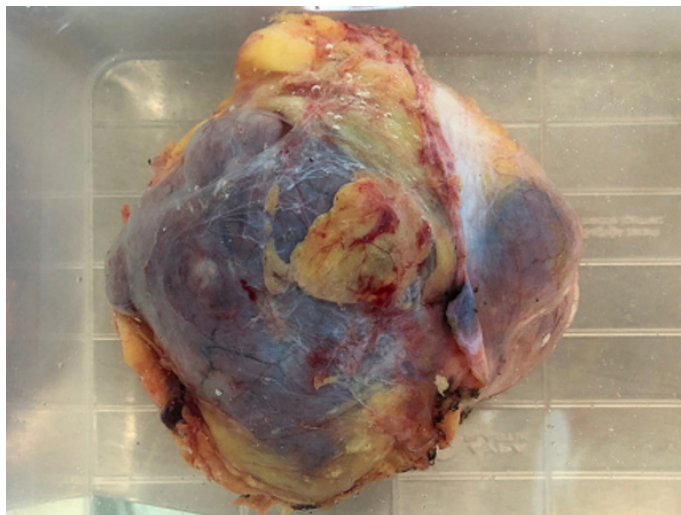
Corresponding Author: Nidal Iflazoglu, Malatya Education and Research Hospital, Clinic of, Surgical Oncology, Malatya, Turkey

E-mail: nidal1933@yahoo.com

the falciform ligament may present with pain in the upper abdominal region, as well as non-specific symptoms such as indigestion, back pain, or may be asymptomatic (5-6). Radiological examinations reveal the location and predict the origin of the disease.



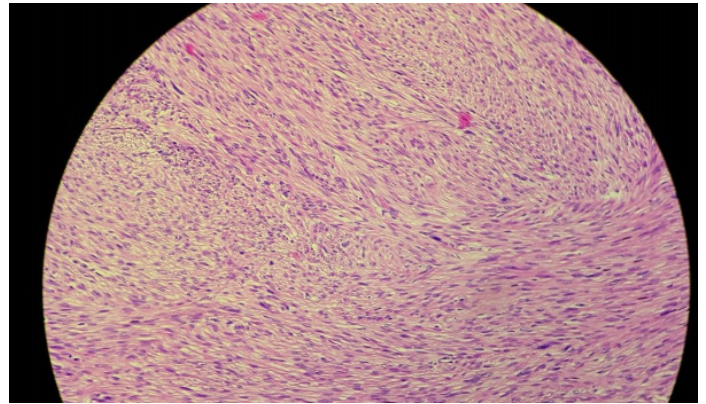
**Figure 2.** In the sagittal plane, solid mass adjacent to the anterior abdominal wall and liver (magnetic resonance)



**Figure 3.** Materials of surgical resection

Apart from cross-sectional studies such as magnetic resonance imaging and computed tomography scans, differential diagnostic tests such as endoscopy, colonoscopy, and laboratory tests may also be required (2-4). The finalization of the malignancy decision of the lesion usually follows the surgical excision.

The aim of the surgical operation is to establish the definitive histopathologic diagnosis, to relieve symptoms related to the disease and to prevent future complications (compression symptoms, secondary infection, intratumoral hemorrhage, metastasis, etc.) and recurrence (1-6). We have managed our patient in the manner described above. In conclusion, it should be considered that upper abdominal tumors may also originate from the falciform ligament.



**Figure 4.** Tumor consisting of smooth muscle fibers with blunt tip, occasionally has large hyperchromatic atypical nucleus (H&E, 200X)

*Competing interests:* The authors declare that they have no competing interest.

*Financial Disclosure:* There are no financial supports

*Ethical approval:* The research made in accordance with 'World Medical Association Declaration of Helsinki'- "Ethical Principles for Medical Research Involving Human Subjects".

## REFERENCES

1. Okajima K, Kobayashi M, Mannami T, et al. Primary leiomyosarcoma of the peritoneum--report of a rare case arising in the falciforme ligament of the liver. *Gan No Rinsho* 1968;14:500-7.
2. Yamaguchi J, Azuma T, Fujioka H, et al. Leiomyosarcoma occurring in the ligamentum teres of the liver: a case report and a review of seven reported cases. *Hepato-gastroenterology* 1996;43:1051-6.
3. Matito-Diaz MJ, Blanco-Fernandez G, Fernandez-Perez J, et al. Leiomyoma of the round ligament of the liver: report of one case. *Rev Esp Enferm Dig* 2015;107:644-6.
4. Navarro C, Hamidian Jahromi A, Donato M, et al. Primary Leiomyoma of the Liver: Case Report and Review of the Literature. *J La State Med Soc* 2015;167:129-33.
5. Feo CF, Ginesu GC, Cherchi G, et al. Mesothelial cyst in the liver round ligament: A case report and review of the literature. *Int J Surg Case Rep* 2017;37:33-5.
6. Lagoudianakis EE, Michalopoulos N, Markogiannakis H, et al. A symptomatic cyst of the ligamentum teres of the liver: a case report. *World J Gastroenterol* 2008;14:3266-8.