

# Radiological determination of safe and adequate corpectomy limits in the cervical region

Salim Senturk

Koc University Hospital Department of Neurosurgery, Istanbul, Turkey

Copyright © 2019 by authors and Annals of Medical Research Publishing Inc.

## Abstract

**Aim:** This manuscript aims to display the relationship between the vertebral artery and its surrounding structures to maintain safe and effective corpectomy during anterior C4, C5, and C6 decompressive surgery.

**Material and Methods:** Fifty patients who applied to the emergency department and received a cervical computed tomography (CT) scan were included, and their C4, C5, and C6 vertebrae margins were measured. The following distances were measured: the distance between the medial wall of the vertebral foramen and lateral border of the anterior arch of the vertebral corpus, the distance between the junction of the corpus-the pedicle and inferior border of the vertebral foramen, the distance between the medial border of the vertebral foramen and longus colli muscles, the distance between each vertebral foramen, and the bipedicular distance.

**Results:** Fifty patients (22 females and 28 males) were assessed in this study. The female and male populations had mean ages of 52.4 and 53.9 years, respectively. All measurements were higher in the lower vertebrae than those in the upper vertebrae. Also all these measurements were found higher in males than females. The following results were reported: a value: C4, 4.1/4.3 (F/M); C5, 4.6/4.9; and C6, 5/5.2 mm; b value: C4, 4.5/4.7; C5, 4.8/5.1; and C6, 5.1/5.5 mm; c value: C4, 8.6/9; C5, 9/9.6; and C6, 9.3/10.1 mm; d value: C4, 23.1/24; C5, 23.9/25.2; and C6, 24.5/25.5 mm; e value: C4, 19.3/20.4; C5, 20/21; and C6, 20.5/21.7 mm.

**Conclusion:** The Distances between the vertebral artery and the surrounding structures and muscles will provide the surgeon a safer working during anterior corpectomy surgery. These parameters should be taken into consideration during anterior corpectomy to obtain more secure and effective decompression.

**Keywords:** Vertebral Artery Injury; Cervical Corpectomy; Vertebral foramen.

## INTRODUCTION

The anterior cervical discectomy and fusion approach was described by Smith and Cloward (1,2). Today, although many modified techniques have been added, mainly anterior corpectomy and fusion, anterior cervical discectomy and fusion, multilevel oblique corpectomy without fusion, cervical arthroplasty techniques are used as an anterior approach to the cervical region. The anterior approach techniques are used in patients requiring anterior decompression of the spinal cord, such as cervical disc herniation, ossification of the posterior longitudinal ligament (PLL), cervical spondylotic myelopathy (CSM), spinal tumors and cervical dislocations. Using these techniques, cervical alignment can be restored along with the decompression of spinal cord and spinal nerve (3,4). However, in some cases, complications such as dysphagia, recurrent laryngeal nerve damage, dura mater injury, root injury, wound infection, graft dislocation and

vertebral artery injury may occur. These conditions may cause neurological deficits, prolonged hospital stay, increased cost and deaths (5,6,7). One of the important causes of mortality is the vertebral artery injury. Although the incidence of vertebral artery injury is not exactly known, the reported rates range between 0.07% and 1.4% (8,9,10,11). Vertebral artery injury may sometimes be asymptomatic, while pseudo-aneurysms can cause neurological deficit, late-onset bleeding, infarction and death (12). In some cases, decompression can be done inadequately with the concern of arterial injury. In this study, we performed some measurements that would allow safe and sufficient decompression at C4, C5, C6 levels by precisely determining the localization of the vertebral artery during an anterior approach.

## MATERIAL and METHODS

Cervical CT images of consecutive patients who

**Received:** 19.01.2019 **Accepted:** 28.02.2019 **Available online:** 14.03.2019

**Corresponding Author:** Salim Senturk, Koc University Hospital Department of Neurosurgery, Istanbul, Turkey

**E-mail:** senturksalim@gmail.com

presented to the Koc University Hospital emergency clinic were examined. Computed tomography scans (Siemens, Munich, Germany) were all acquired in an axial plane using a standardized protocol, with post-acquisition reconstructed coronal and sagittal planes. All images were reviewed on a PACS workstation (General Electric Healthcare, Little Chalfont, United Kingdom).

For each of the C4, C5 and C6 vertebrae of the patients, 5 different measurements were made and the averages were obtained. The measurements were conducted on axial cervical CT images of the patients. Patients over the age of 18 years with no history of cervical surgery or a history of an infection, fracture or tumor in the cervical vertebrae were included in the study.

In tomography images, the following measurements were made for each vertebra and the average values were obtained;

a: The distance between the medial wall of the vertebral foramen and the lateral border of the anterior arch of the vertebral corpus (Figure 1. Red line),

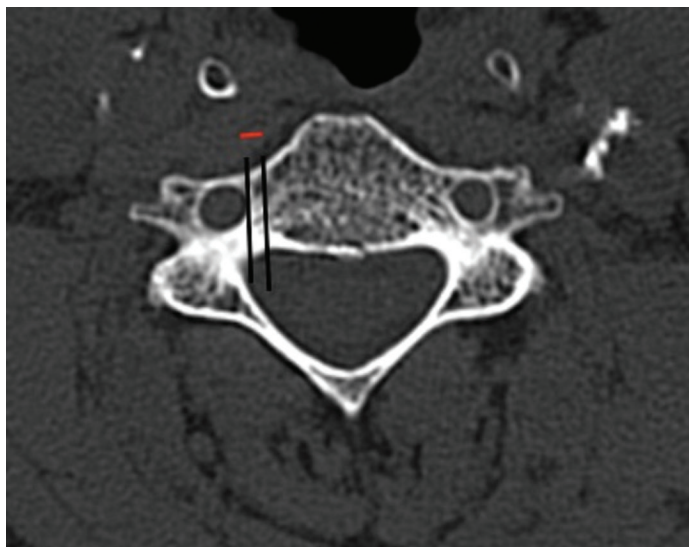
b: The distance between junction of the corpus-the pedicle and the inferior wall of the vertebral foramen (Figure 2. Red line)

c: The distance between the medial wall of foramen and the longus colli muscle (Figure 3. Red line). Soft tissue density was also examined since muscle tissue was evaluated.

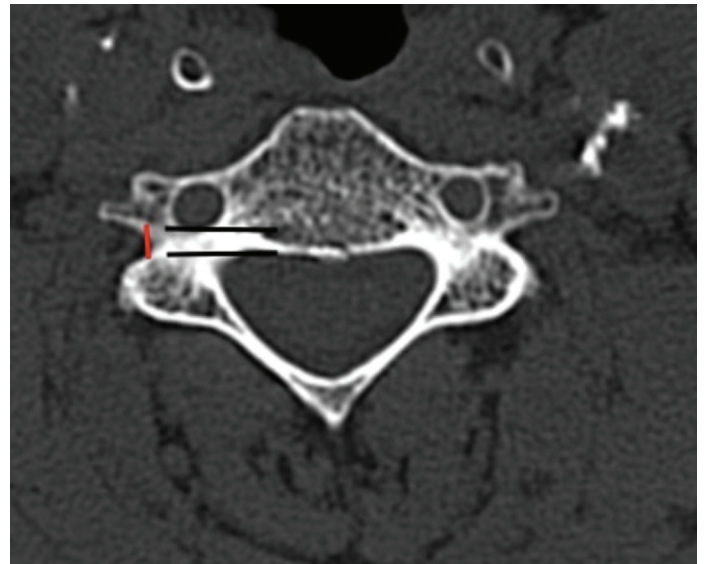
d: The distance between the two vertebral foramina (Figure 4. Red line)

e: The bipedicular distance (Figure 4. Green line)

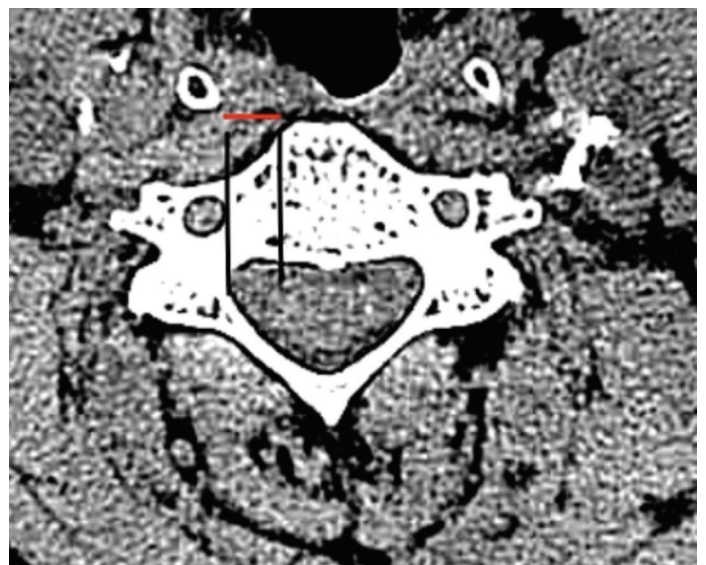
This research is a cross-sectional study. Descriptive statistical methods were used in data analysis. SPSS 16.0 program was used in the analyzes.



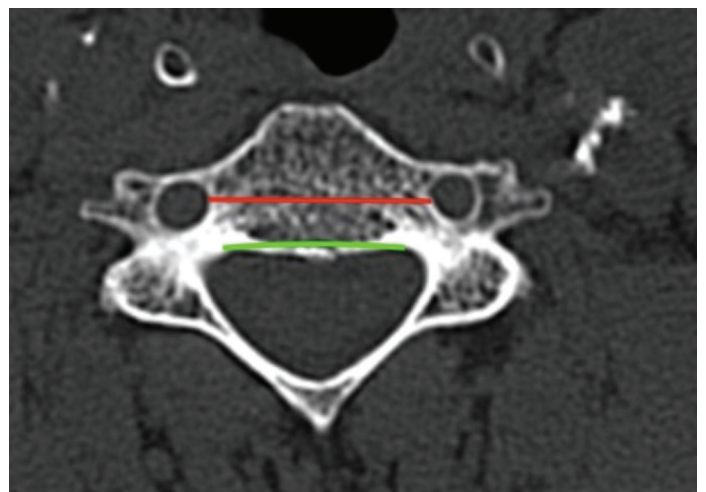
**Figure 1.** The distance between the medial wall of the vertebral foramen and the lateral border of the anterior arch (Red line on the picture)



**Figure 2.** The distance between junction of the corpus-the pedicle and the inferior wall of the vertebral foramen (Red line on the picture)



**Figure 3.** The distance between the medial wall of foramen and the longus colli (Red line on the picture)



**Figure 4.** The distance between the two vertebral foramina (Red line on the picture) e: The bipedicular distance (Green line on the picture)

## RESULTS

A total of 50 patients (22 female and 28 male) were studied. The mean age was 52.4 years in females with an age range of 21-80 years and the mean age of males was 53.9 years with an age range of 40-73 years (Table 1).

All values were higher in males than in females and in the lower vertebral bodies than in the upper vertebral bodies (Table 2, 3, 4).

The A value was measured as 4.1/4.3mm (F/M) for C4, 4.6/4.9mm for C5 and 5.1/5.2mm for C6 (Table 2, 3, 4).

The B value was measured as 4.5/4.7mm for C4, 4.8/5.1mm for C5 and 5.1/5.5mm for C6 (Table 2, 3, 4).

The C value was measured as 8.6/9mm for C4, 9/9.6mm for C5, and 9.3/10.1mm for C6 (Table 2, 3, 4).

The D value was measured as 23.1/24mm for C4, 23.9/25.2mm for C5 and 24.5/25.5mm for C6 (Table 2, 3, 4).

The E value was measured as 19.3/20.4mm for C4, 20/21mm for C5 and 20.5/21.7mm for C6 (Table 2, 3, 4).

**Table 1. Man and woman age distribution**

Woman					
	N	Minimum	Maximum	Mean	Std. Deviation
Age	28	21.00	80.00	52.4286	13.31785
Man					
	N	Minimum	Maximum	Mean	Std. Deviation
Age	22	40.00	73.00	53.9091	9.94705

**Table 2. Values for C4 vertebrae**

C4 Woman					
	N	Minimum	Maximum	Mean	Std. Deviation
a	28	3.30	5.80	4.1379	63075
b	28	2.90	6.30	4.5089	74673
c	28	7.10	9.90	8.6557	82090
d	28	17.20	27.00	23.1821	2.12795
e	28	13.90	23.20	19.3536	2.22735
C4 Man					
	N	Minimum	Maximum	Mean	Std. Deviation
a	22	3.40	5.90	4.3909	75824
b	22	3.40	6.10	4.7959	81272
c	22	6.90	11.30	9.0500	1.26406
d	22	18.10	29.60	24.4409	2.78596
e	22	15.70	24.80	20.4909	2.22430

**Table 3. Values for C5 vertebrae**

C5 Woman					
	N	Minimum	Maximum	Mean	Std. Deviation
a	28	3.40	6.10	4.6107	67404
b	28	3.80	6.70	4.8929	70510
c	28	7.30	10.80	9.0143	92124
d	28	17.80	27.50	23.9036	2.12507
e	28	14.10	22.90	20.0321	2.13785
C5 Man					
	N	Minimum	Maximum	Mean	Std. Deviation
a	22	3.70	6.70	4.9209	87530
b	22	3.10	6.90	5.1459	88991
c	22	7.30	12.10	9.6182	1.11211
d	22	18.70	31.30	25.2318	3.04590
e	22	16.10	24.00	21.0091	2.05772

**Table 4. Values for C6 vertebrae**

C6 Woman					
	N	Minimum	Maximum	Mean	Std. Deviation
a	28	3.60	6.30	5.0086	74226
b	28	4.00	7.30	5.1929	76928
c	28	7.90	11.80	9.3964	98073
d	28	18.10	30.00	24.5429	2.39605
e	28	14.30	23.20	20.5857	2.31416
C6 Man					
	N	Minimum	Maximum	Mean	Std. Deviation
a	22	4.10	6.90	5.2368	90312
b	22	3.90	6.70	5.5327	78676
c	22	8.10	12.40	10.1227	1.13218
d	22	19.10	32.00	25.5773	3.00538
e	22	16.40	24.50	21.7682	2.03736

## DISCUSSION

There are many anatomical and radiological studies about cervical vertebrae in the literature. In these studies, changes in vertebrae according to gender, age and ethnic origin were revealed (13,14).

A study examining the vertebral corpus and foramen identified remarkable differences between males and females (15).

The present study aimed to determine mean values in the Turkish population. We evaluated mean values separately for males and females; because of this difference between males and females has been clearly revealed in literature (13,15).

Although some differences have been found between right and left side measurements in a study examining the vertebral corpus and the uncinated process, it was found

that this was not a statistically significant difference (16). In our study, all measurements were made on the right side without any discrimination for the left and right sides (for a, b, c values). In the study, the measurements were made on the vertebral bodies that are frequently removed through corpectomy procedure, while no measurement was made for C7 since vertebral artery enters the transverse foramen mostly at the level of C6 (17).

Measurements have been made to understand the relationship of the vertebral artery with the vertebral corpus and to perform a safe corpectomy. For this purpose, the A value gives some idea about that what extent the decompression from medial to lateral can safely be extended.

It shows, on the axial plane, the distance between the anterior lateral arch of the corpus anterior and the line passing along the medial wall of the vertebral foramen (Figure 1). The longus colli muscle is stripped and the lateral border of the vertebral corpus can be easily exposed with a dissector. The vertebral foramen was detected from this point in the 4.1/4.3mm (F/M) lateral of C4, 4.6/4.9 of C5, and 5/5.2mm of C6. Therefore, when it is proceeded in the lateral of the vertebral corpus detected with the dissector, the vertebral foramen still remains distant. When a limited corpectomy is performed between the anterior arches of both vertebral bodies, the corpectomy can be performed without the possibility of interfering with vertebral artery. However, it should be kept in mind that there might be anatomical variations. For each patient, the relationship between the vertebral artery and the corpus should be reviewed.

The B value was measured as 4.5/4.7mm for C4, 4.8/5.1mm for C5 and 5.1/5.5mm for C6. The B value indicates the distance between the pedicle and the vertebral foramen (Figure 2). During the microdiscectomy, the pedicle is detected via a dura hook, and the distance from the vertebral foramen is determined. The measurement of this distance allows us to remain at a safe distance from the vertebral artery during discectomy and corpectomy.

The C value was measured as 8.6/9mm for C4, 9/9.6mm for C5 and 9.3/10.1mm for C6. This value indicates the distance between the medial wall of the foramen and medial border of the longus colli the longus colli muscle (Figure 3). The longus colli muscle is visualized radiologically but it is also inspected macroscopically. In this measurement, safe distance to the lateral is determined by taking this muscle as the landmark.

In a study in which vertebral arteries and transverse foramina were measured, the mean diameter of the vertebral artery was measured as 13.63mm and the diameter of transverse foramen was 28.49mm (18).

In a study examining the course of the vertebral artery, it was determined that the vertebral artery proceeded at the anterior of the foramen and was adjacent to the lateral tubercle of the transverse process at the level of C6, while ascending to the C3 level, it proceeds at the posterior of

the foramen in the transverse foramen (17,19).

Preoperative localization of the vertebral artery at the target corpectomy level will avoid possible injury to the vertebral artery.

The D value was measured as 23.1/24mm for C4, 23.9/25.2mm for C5 and 24.5/25.5mm for C6. This value indicates the distance between the vertebral foramina. In this way, we learn our safe width during corpectomy.

The E value was measured as 19.3/20.4mm for C4, 20/21mm for C5 and 20.5/21.7mm for C6. This value shows the distance between the pedicles in the corpus base (Figure 4). It also indicates the potential width at the base if maximum decompression was performed, although this is also dependent on the pathology.

Vertebral artery injury may develop during foraminotomy or uncovertebral joint resection. Especially when working in this region, the use of a high-speed drill for lateral decompression, aggressive discectomy or aggressive bone decompression, misapplications during decompression of the spinal canal that lateral aspect of which is invaded by a tumor or infection can lead to vertebral artery injury (20,21).

The reoperation rate was reported to be 0.1% due to insufficient decompression and inability of placing the graft properly. Good planning of the distance for corpectomy will allow adequate decompression and a proper decompression area to allow the graft to be placed properly (22). This will further reduce graft-related reoperation rates.

There is a lack of consensus in literature regarding the width of corpectomy, and it has been reported that 14-16 mm central decompression is sufficient in a series of surgical patients with degenerative cervical pathology (23).

There are authors suggesting that the corpectomy width above 15 mm increases the likelihood of vertebral artery injury, and likewise, a width of less than 15 mm reduces the possibility of C5 paralysis (24).

Knowing the bipedicular distance and knowing the distance between the transverse foramina will reduce the likelihood of reoperation due to insufficient decompression. Considering that the recommended decompression width in the literature is 15 mm, a value of 15 mm remains within the safe limits in cases provided that adequate decompression is achieved.

These values are different for each patient; therefore, it is important to calculate these values for each patient in order to perform corpectomy safely.

In addition to these values, the distance between the anterior surface of the corpus and the spinal cord should also be calculated. This value gives us an idea of the depth which we should be more meticulous. The measurements provide the surgeon with convenience for maximum and safe decompression.

## CONCLUSION

We performed some measurements to reduce the possibility of a vertebral artery injury during cervical corpectomy and to avoid insufficient decompression. These values are different for each patient; therefore, it is important to calculate these values for each patient to be operated rather than using these averages in order to perform corpectomy safely. It should be noted that there will be anatomical variations. We believe that a good planning and radiological evaluation performed before every operation will reduce the complication rates.

*Competing interests: The authors declare that they have no competing interest.*

*Financial Disclosure: There are no financial supports*

*Ethical approval: Retrospective Study*

*Salim Senturk ORCID: 0000-0003-0524-9537*

## REFERENCES

- Smith GW, Robinson RA. The treatment of certain cervical-spine disorders by anterior removal of the intervertebral disc and interbody fusion. *J. Bone Joint Surg Am* 1958;40:607-24.
- Cloward RB. The anterior approach for removal of ruptured cervical disks. *J. Neurosurg* 1958;15:602-17.
- Steinmetz MP, Stewart TJ, Kager CD, et al. Cervical deformity correction. *Neurosurgery* 2007;60:90-7.
- Tan LA, Riew KD, Traynelis VC. Cervical spine deformity-Part 2: Management algorithm and anterior techniques. *Neurosurgery* 2017;81:561-7.
- Miller JA, Lubelski D, Alvin MD, et al. C5 palsy after posterior cervical decompression and fusion: cost and quality-of-life implications. *Spine J* 2014;14:2854-60.
- Minhas SV, Chow I, Jenkins TJ, et al. Preoperative predictors of increased hospital costs in elective anterior cervical fusions: a single-institution analysis of 1,082 patients. *Spine J* 2015;15:841-8.
- Nandyala SV, Elboghady IM, Marquez-Lara A, et al. Cost analysis of incidental durotomy in spine surgery. *Spine (Phila Pa 1976)* 2014;39:E1042-E51.
- Lunardini DJ, Eskander MS, Even JL, et al. Vertebral artery injuries in cervical spine surgery. *Spine J* 2014;14:1520-5.
- Rampersaud YR, Moro ER, Neary MA, et al. Intraoperative adverse events and related postoperative complications in spine surgery: implications for enhancing patient safety founded on evidence-based protocols. *Spine (Phila Pa 1976)* 2006;31:1503-10.
- Daentzer D, Deinsberger W, Boker DK. Vertebral artery complications in anterior approaches to the cervical spine: report of two cases and review of literature. *Surg Neurol* 2003;59:300-9.
- Burke JP, Gerszten PC, Welch WC. Iatrogenic vertebral artery injury during anterior cervical spine surgery. *Spine J* 2005;5:508-14.
- Fassett DR, Dailey AT, Vaccaro AR. Vertebral artery injuries associated with cervical spine injuries: a review of the literature. *J Spinal Disord Tech* 2008;21:252-8.
- Stemper BD, Yoganandan N, Pintar FA, et al. Anatomical gender differences in cervical vertebrae of size-matched volunteers. *Spine* 2008;33:E44-9.
- David E, Youssef M, Khalil S, et al. Demographical aspects in cervical vertebral bodies' size and shape (c3-c7): a skeletal study. *Spine J* 2017;17:135-142.
- Herzo RG, Wiens JJ, Dillingham MF, et al. Normal cervical spine morphometry and cervical spinal stenosis in asymptomatic professional football players. Plain film radiography, multiplanar computed tomography, and magnetic resonance imaging. *Spine* 1991;16:S178-86.
- Güvençer M, Naderi S, Men S, et al. Morphometric evaluation of the uncinat process and its importance in surgical approaches to the cervical spine: a cadaveric study. *Singapore Med J* 2016;57:570-7.
- Peng CW, Chou BT, Bendo JA, et al. Vertebral artery injury in cervical spine surgery: anatomical considerations, management, and preventive measures. *Spine J* 2009;9:70-6.
- Sanchis-Gimeno JA, Blanco-Perez E, Llido S, et al. Can the transverse foramen/vertebral artery ratio of double transverse foramen subjects be a risk for vertebrobasilar transient ischemic attacks? *J Anat* 2018;7.
- Nourbakhsh A, Yang J, McMahan H, et al. Transverse process anatomy as a guide to vertebral artery exposure during anterior cervical spine approach: a cadaveric study. *Clin Anat* 2017;30:492-7.
- Smith MD, Emery SE, Dudley A, et al. Vertebral artery injury during anterior decompression of the cervical spine. A retrospective review of ten patients. *J Bone Joint Surg Br* 1993;75:410-5.
- Eskander MS, Drew JM, Aubin ME, et al. Vertebral artery anatomy: a review of two hundred fifty magnetic resonance imaging scans. *Spine (Phila Pa 1976)* 2010;35:2035-20-40.
- Sarkar S, Nair BR, Rajshekhkar V. Complications following central corpectomy in 468 consecutive patients with degenerative cervical spine disease. *Neurosurg Focus* 2016;40:E10.
- Nooti Venkata Srinivasa Rao, Vedantam Rajshekhkar, Distal-type cervical spondylotic amyotrophy: incidence and outcome after central corpectomy *J Neurosurg Spine* 2009;10:374-9.
- Odate S, Shikata J, Yamamura S, et al. Extremely wide and asymmetric anterior decompression causes postoperative C5 palsy: an analysis of 32 patients with postoperative C5 palsy after anterior cervical decompression and fusion. *Spine (Phila Pa 1976)* 2013;38:2184-9.