

The aging kidney: A 10-year renal biopsy study of geriatric population

Yasin Sahinturk¹, Metin Sarikaya², Suleyman Dolu¹, Mehmet Kok¹, Ayca Inci², Ali Riza Caliskan³

¹University of Health Sciences Antalya Training and Research Hospital, Department of Internal Medicine, Antalya, Turkey

²University of Health Sciences Antalya Training and Research Hospital, Department of Nephrology, Antalya, Turkey

³Inonu University, Faculty of Medicine, Department of Gastroenterology, Malatya, Turkey

Van Yuzuncu Yil University, Faculty of Medicine, Department of Anesthesiology and Reanimation, Van, Turkey

Copyright © 2019 by authors and Annals of Medical Research Publishing Inc.

Abstract

Aim: To report our experience with the renal biopsy/complications and histopathologic patterns of renal diseases according to their clinical presentation and to make the best disease management in the elderly patients.

Material and Methods: Totally 136 patients were analyzed according to their renal biopsy histopathology, clinical diagnosis and biopsy related complications between 2006 and 2016.

Results: Nephrotic syndrome (NS) and acute kidney injury (AKI) were the leading indications for renal biopsy. Totally 65 patients (47%) were diagnosed as NS and 60 patients (44%) were AKI. The most frequent histopathologic diagnosis was amyloidosis (30%). Membranous nephropathy (22%) was the second frequent histopathologic diagnosis. Amyloidosis (18.3%) was the leading cause of nephrotic syndrome and membranous nephropathy (17.6%) was the second most seen cause. Amyloidosis (11%) was the mostly seen histopathologic diagnosis of AKI. Back pain longer than 12 hours (10%) was the most common complication.

Conclusion: According to our findings, renal disease of elderly differs from other age groups according to histopathologic distribution, early renal function loss and rapid progression to end stage renal disease. For an accurate early diagnosis and initiating specific treatment, renal biopsy should be performed on an individual basis without an increased risk for renal biopsy related complications.

Keywords: Acute kidney injury; nephrotic syndrome; renal biopsy; elderly; renal histopathology.

INTRODUCTION

Histological examination of kidney biopsies remain gold standard for the diagnosis of renal diseases. Increased life expectancy means that there is an increased risk for chronic diseases and acute events that may be more severe than younger patients. In addition, nephrotoxic effects of medical treatments, hypertension, diabetes mellitus, cardiovascular or other systemic diseases and surgical treatments may contribute to renal diseases or progressive decline in GFR (glomerular filtration rate) in geriatric population (1).

Besides the changing concept of old age, scientific literature establish 65 years as a cut-off (1-3). In recent years, renal diseases of elderly patients are analyzed

in several studies with reference to this cut-off (3-5). According to these studies, renal biopsy provides best information for the diagnosis and disease progression. There is minimally increased risk for complications and advanced age is no longer considered a contraindication for renal biopsy (3-6).

Clinical profile of elderly patients might be worsened easier than younger patients. Therefore, rapid diagnosis and treatment become the most important part of the disease management. Among the elderly, clinical presentation of diseases not exactly match with the histopathologic diagnosis. If we know distribution of the histopathologic diagnosis of elderly patients according to their clinical presentation, we may estimate the true diagnosis and treatment easily.

Received: 30.04.2019 **Accepted:** 08.07.2019 **Available online:** 28.08.2019

Corresponding Author: Yasin Sahinturk, University of Health Sciences Antalya Training and Research Hospital, Department of Internal Medicine, Antalya, Turkey **E-mail:** drsahinturk@yahoo.com

In our study, we report our experience with the renal biopsy/complications and histopathologic patterns of renal diseases according to their clinical presentation and we aimed to make the best disease management in the elderly patients.

MATERIAL and METHODS

We searched retrospectively for all biopsies taken from patients aged over 65 years old between 2006-2016 for 10 years period in Antalya Training and Research Hospital. The same pathologist did mainly light microscope and direct immunofluorescence analysis for each sample. Electron microscopy was not available for use in this study. Patient's epidemiological and clinical data were recorded.

Study population was grouped according to these five definitions: (1) acute kidney injury (AKI): rapid deterioration of glomerular filtration rate (GFR), with or without oligo anuria or rapidly progressive renal failure, including worsening of chronic kidney disease; (2) nephrotic syndrome: proteinuria > 3.5 g/day/1.73 m² and serum albumin < 2.5 g/dl; (3) acute nephritic syndrome (ANS), oliguria AKI with edema, hematuria and hypertension; (4) chronic kidney disease (CKD): persistent serum creatinine > 1.5 mg/dl.; (5) asymptomatic urinary abnormalities (AUA).

The questionnaire was applied to obtain the following information: patient number, date of birth, gender, presence of hypertension and/or antihypertensive treatment, serum creatinine (mg/dl), creatinine clearance (ml/min), proteinuria (g/day). We noted the main renal syndrome, the histological methods used with the sample, and the number of glomerulus obtained. We also searched for biopsy complications: pain, gross hematuria and hematuria requiring blood transfusions, infection and death.

Primary glomerulonephritis (GN) was classified into nine groups: minimal change disease (MCD); focal segmental glomerulosclerosis (FSGS); crescentic GN (presence of crescents in 50% of glomeruli) type 1 (accompanied by anti-glomerular basal membrane antibodies), type 2 (presence of immune complexes), and type 3 [necrotizing GN with or without anti-neutrophil cytoplasmic antibodies (ANCA) or systemic vasculitis symptoms]; membranoproliferative GN type 1; dense deposit disease (also called membranoproliferative GN type 2); membranous nephropathy; IgA nephropathy, and non-IgA mesangioproliferative GN. Secondary GN were also classified into eight groups: fibrillary GN, lupus nephritis, connective tissue diseases (scleroderma and other diseases not included in other diagnosis), vasculitis (including crescentic GN type 3 or pauci-immune), Good pasture syndrome, cryoglobulinemic GN, amyloidosis, and light-chain nephropathy. Tubulointerstitial nephritis was defined as acute or chronic. Finally, non-inflammatory renal diseases were classified as diabetic nephropathy, nephrosclerosis, acute tubular necrosis, myeloma kidney

(or light-chain cast nephropathy) disease and thrombotic microangiopathy.

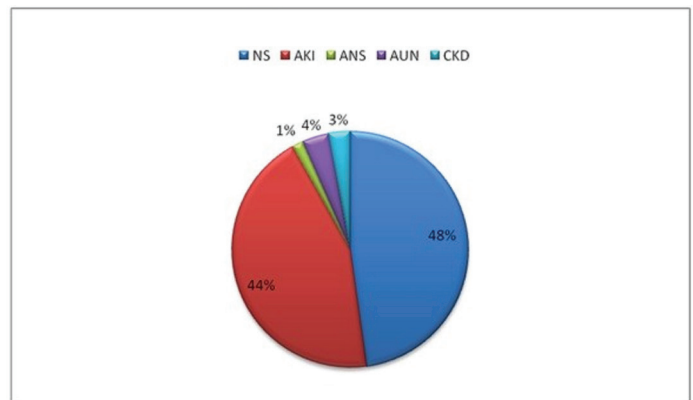
Statistical Analysis

Statistical analysis was performed using SPSS for Windows Version 16.0 (SPSS, Chicago, Ill., USA). The normal distribution of the samples was determined using the Kolmogorov-Smirnov test. Values were expressed as medians (interquartile range) when the parameters did not follow a normal distribution. Qualitative variables were compared using the two test and Fisher's exact test. P value < 0.05 was considered significant.

RESULTS

Between 2006 and 2016 for 10 years period, totally 136 renal biopsies that were taken from patients aged over 65 years old were evaluated according to clinical presentation of patients, histopathologic diagnosis and biopsy related complications. In 2006, only eight biopsies were performed and in 2015 26 biopsies were performed in this age group. 80 (58.8%) were man and 56 (41.2%) were woman, median age was 69 and the oldest patient was 89 years old. Median creatinine level was 2.56 mg/dl and glomerular filtration rate was 26 ml/min. High glomeruli number (n:15) was enough for the true histopathologic diagnosis. High proteinuria level showed that most of the patients were in the nephrotic range (Table 1).

NS and AKI were the leading indications for renal biopsy followed by CKD, ANS, AUA. Totally 65 patients (47%) were diagnosed as NS and 60 patients (%44) were AKI (Figure 1).



NS: Nephrotic syndrome, AKI: acute kidney injury, ANS: Acute nephritic syndrome, AUN: Asymptomatic urinary abnormalities, CKD: Chronic kidney disease

Figure 1. Indications for renal biopsy

Complications occurred in 17 patients (12.5%). Back pain longer than 12 hours was the most common complication in 14 (10%) patients. Other complications were gross hematuria lasting more than 12 hours in 3 (2.2%) patients, hematuria requiring blood transfusion in 1 patient. Infection or death were not occurred as a complication of renal biopsy.

The most frequent histopathologic diagnosis was amyloidosis (30%) (primary or secondary). Membranous nephropathy (22%) was the second frequent histopathologic diagnosis in all glomerulonephritis and

the most seen primary glomerulonephritis (Table 2).

According to the clinical presentation, amyloidosis (18.3%) was the leading cause of nephrotic syndrome and membranous nephropathy (17.6%) was the second most seen cause. Also MCD was the third cause of nephrotic syndrome. Amyloidosis (11%) was the mostly seen histopathologic diagnosis of AKI. Crescentic GN type 1-2 (7.3%) and AIN (6.6%) was the other frequent causes of AKI. Chronic interstitial nephritis was the most frequent cause of chronic kidney disease when we match clinical presentation with histopathologic diagnosis (Table 3).

Table 1 Patient characteristics

Patient number	136
Female, n (%)	56 (41.2)
Age, years	69 ¹
Serum creatinine (mg/dl)	2.56 ¹
Glomeruli, n	15 ¹
Proteinuria (g/day)	3.1 ¹

Table 2 Histopathological diagnosis of patients

	Histopathological diagnosis	n	%
Primary glomerulonephritis	Membranous nephropathy	30	22
	Crescentic GN types 1 and 2	10	7.3
	IgA nephropathy	6	4.4
	Minimal change disease	4	2.9
	Focal segmental sclerosis	3	2.2
	Membranoproliferative GN	3	2.2
	Total	56	41.1
Secondary glomerulonephritis	Amyloidosis	41	30
	Crescentic GN type 3	7	5.1
	Light chain nephropathy	2	1.4
	Goodpasture syndrome	1	0.7
	Total	51	37.5
Interstitial nephritis	Acute	9	6.6
	Chronic	3	2.2
	Total	12	8.8
Non-inflammatory renal disease	Acute tubular necrosis	6	4.4
	Diabetic glomerulopathy	4	2.9
	Myeloma kidney	1	0.7
	Unclassifiable	6	4.4
	Total	17	12.5

Table 3. Relation between clinical presentation and histopathological diagnosis

Clinical presentation	Histopathological diagnosis	n	%
Nephrotic syndrome	Amyloidosis	25	18.3
	Membranous nephropathy	24	17.6
	Minimal change disease	4	2.9
	IgA nephropathy	3	2.2
	Focal segmental sclerosis	3	2.2
	Diabetic glomerulopathy	3	2.2
	Membranoproliferative GN	2	1.4
	Light chain nephropathy	1	0.7
	Total	65	47
Acute kidney injury	Amyloidosis	15	11
	Crescentic GN type 1 and 2	10	7.3
	Acute interstitial nephritis	9	6.6
	Crescentic GN type 3	6	4.4
	Acute tubular necrosis	6	4.4
	Membranous nephropathy	6	4.4
	Chronic interstitial nephritis	3	2.2
	IgA nephropathy	2	1.4
	Light chain nephropathy	2	1.4
	Goodpasture syndrome	1	0.7
	Total	60	44
	Nephritic syndrome	Crescentic type 3	1
Membranoproliferative GN		1	0.7
Total		2	1.4
Asymptomatic urinary abnormalities	Diabetic glomerulopathy	4	2.9
	Myeloma kidney	1	0.7
	Total	5	3.6
Chronic kidney disease	Chronic interstitial nephritis	2	1.4
	IgA nephropathy	1	0.7
	Amyloidosis	1	0.7
	Total	4	2.9

DISCUSSION

The population of elderly people is increasing (7). Doubling of the number of individuals that are older than 65 is expected in the next 50 years. The population rate of elderly in Turkey was 7.7% in 2013 and is estimated to increase to 10.2% in 2023 and 20.8% in 2050 (8). The pathological aging of kidney continues simultaneously with the progression of patients' age. This causes easier

contribution of nephrotoxic effects of medical treatments, hypertension, diabetes mellitus, cardiovascular or other systemic diseases and surgical treatments to renal diseases (1). As elderly people easily become decompensated according to the renal physiology, histopathologic examination of kidney become the gold standard for the early and true diagnosis and treatment.

Studies in the recent years were generally focused

on increasing number of renal biopsies in the elderly. Consistent with the literature, we showed that the number of renal biopsies performed in the elderly increased but to our knowledge, this increment is lower than the growth of the population of elderly people (9,10). Age traditionally accepted as a risk factor for renal biopsy complications. There are studies showing higher rate of bleeding because of the smaller kidney size and hemostasis problems (11). In contrast, in recent publications involving approximately 15000 biopsies, death occurred only in one patient, major bleeding problems requiring blood transfusion or surgical interpretation for %1 and there was no significant difference between younger and elderly patients according to the renal biopsy procedure related complications (12-14). Back pain longer than 12 hours or requiring analgesic treatment was the leading complication of our study and only 10% of our population complained back pain. Consistent with the literature only 2% of our patients had hematuria lasting more than 12 hours or requiring blood transfusion. Any of our patients required surgical intervention or died because of renal biopsy related complications.

Tubulointerstitial nephritis or immunoallergic nephritis is generally related to multiple drugs and elderly population require several treatments. Early treatment with corticosteroids is the most important part of immunoallergic nephritis and improve prognosis (15). In patients with AKI, early differential diagnosis of immunoallergic nephritis from ATN by renal biopsy enable early treatment with corticosteroids and better treatment outcomes (16,17). Dhaun, Neeraj, et al. searched for renal biopsy results and treatment outcomes and showed a change in diagnosis in 60% and an alteration in treatment approach in 35% of cases (18). In our study, 6.6% of AKI cases were diagnosed as immunoallergic nephritis and this was similar to 9% by Haas et al. (19).

GN can also benefit from early diagnosis and treatment after a renal histopathological examination. Polito M.G. et al. showed rapid diagnosis, early treatment and few complications with renal biopsy and better prognosis for patients with the clinical diagnosis of NS (20). In a review by Hoy, Wendy E., et al. about histopathologic management of primary glomerular pathologies showed the misdiagnosed elderly patients without histopathologic examination and showed the need to increase the number of renal biopsies in the elderly population (21).

AKI (39%) and NS (42%) were the leading causes of renal biopsy in our study. In all age group studies which analysis the different indications for renal biopsy revealed that NS is the leading cause for renal biopsy (65%,68%,72%) and AKI has a very low rate of indication (12%,15%,15%) (22-24). In contrast, studies focusing on the renal biopsy indications of the elderly population showed equal indication rates for NS and AKI which was similar to our study results (2,3,6,9,14,17).

In our study population, amyloidosis was the most frequent histopathologic cause of AKI. In addition,

amyloidosis was the leading cause of nephrotic syndrome and membranous nephropathy was the second most seen cause. There are several studies that ranking amyloidosis as the first or second cause of nephrotic syndrome together with the membranous nephropathy (25-27). All patients diagnosed with amyloidosis were in the late stage and nephrotic range proteinuria with decreased creatinine clearance were detected which suggests poor prognosis. This condition is the most important result of our study and for an early diagnosis, clinicians should be more watchful to perform renal biopsy.

Pauci-immune GN related vasculitis is the most important cause of AKI in the elderly. Most of the cases are diagnosed with ANCA testing and there is no need to perform a renal biopsy (13,15) Histopathologic diagnosis rate of this entity reflect only a small number of cases because ANCA test positivity without biopsy is enough for treatment decision. Therefore, our histopathologic results does not reflect the real condition about the ANCA positive vasculitis.

Dhaun, Naaraj et al. reported that treatment choice differs in 40% of patients who underwent renal biopsy. AKI, NS, hematuria and the absence of chronic kidney disease were the most clinical presentations that treatment choice is modified after renal biopsy (15). On the other hand, immunosuppressive treatment may cause dangerous complications that should be reduced with a disease specific treatment by the help of renal histopathological diagnose. Clinicians should easily modify management decisions according to the biopsy results. In addition, renal biopsy gives prognostic information about the disease. In addition there is no increased risk for complications in elderly patients for performing renal biopsy (9,11,12). As a result, we believe that when the appropriate indications are met, renal biopsy gives potential benefit in this age group.

Our study has some limitations. First, no data were collected for laboratory analysis such as autoimmunity and ANCAs. Second, clinical questionnaire did not include treatment outcome. In addition, our study population was not big enough to provide a clear information about risk benefit ratio of renal biopsy.

CONCLUSION

In conclusion, renal biopsy procedure for elderly patients has no increased risk about biopsy related complications. Histopathologic examination of kidney provides us important information about the disease, early diagnosis and treatment options. Acute kidney injury and nephrotic syndrome were the leading clinical presentations of renal biopsy and amyloidosis was the firstly ranked histological diagnosis of both conditions. Finally, renal disease of elderly differs from other age groups according to histopathologic distribution, early renal function loss and rapid progression to end stage renal disease. Therefore, for an accurate early diagnosis and initiating specific treatment renal biopsy should be performed on an individual basis.

Competing interests: The authors declare that they have no competing interest.

Financial Disclosure: There are no financial supports

Ethical approval: The study was approved by local ethics committee of the university.

Yasin Sahinturk ORCID: 0000-0003-4907-0766

Metin Sarikaya ORCID: 0000-0002-4939-6486

Suleyman Dolu ORCID: 0000-0002-7496-9493

Mehmet Kok ORCID: 0000-0002-5285-4513

Ayca Inci ORCID: 0000-0002-7894-8913

Ali Riza Caliskan ORCID: 0000-0003-3187-8548

REFERENCES

1. Knoll, Greg A. Kidney transplantation in the older adult. *Am J Kidney Dis* 2013;61:790-7.
2. Jin B, Zeng C, Ge Y, et al. The spectrum of biopsy-proven kidney diseases in elderly Chinese patients. *Nephrology Dialysis Transplantation*. 2014;29:2251-9.
3. Korbet SM, Volpini KC, Whittier WL. Percutaneous renal biopsy of native kidneys: a single-center experience of 1,055 biopsies. *Am J Nephrol* 2014;39:153-62.
4. Hajivandi, Abdollah, and Massoud Amiri. World kidney day 2014: Kidney disease and elderly. *J Parathyroid Dis* 2014;2:3-4.
5. Brown CM, Scheven L, O'Kelly P, et al. Renal histology in the elderly: indications and outcomes. *J Nephrol* 2012;25:240.
6. Shin JH, Pyo HJ, Kwon YJ, et al. Renal biopsy in elderly patients: clinicopathological correlation in 117 Korean patients. *Clin Nephrol* 2001;56:19-26.
7. Bowling CB, Muntner P. Epidemiology of chronic kidney disease among older adults: a focus on the oldest old. *J Gerontol A Biol Sci Med Sci* 2012;67:1379-86.
8. Older people in Statistics. Not for Service: Turkish Statistical Institution. Available from: www.who.int/ageing/about/facts/en/index.html/Tuik News Bulletin Report. 2014
9. Moutzouris DA, Herlitz L, Appel GB, et al. Renal biopsy in the very elderly. *Clin J Am Soc Nephrol* 2009;4:1073-82.
10. Covic A, Schiller A, Volovat C, et al. Epidemiology of renal disease in Romania: a 10 year review of two regional renal biopsy databases. *Nephrol Dial Transplant* 2005;21:419-24.
11. Stratta P, Canavese C, Marengo M, et al. Risk management of renal biopsy: 1387 cases over 30 years in a single centre. *Eur J Clin Invest* 2007;37:954-63.
12. Tøndel C, Vikse BE, Bostad L, et al. Safety and complications of percutaneous kidney biopsies in 715 children and 8573 adults in Norway 1988–2010. *Clin J Am Society Nephrol* 2012;7:1591-7.
13. Xu DM, Chen M, Zhao MH. Risk factors for severe bleeding complications in percutaneous renal biopsy. *Am J Med Sci* 2017;353:230-5.
14. Pan X, Xu J, Ren H, et al. Changing spectrum of biopsy-proven primary glomerular diseases over the past 15 years: a single-center study in China. In *New Insights into Glomerulonephritis 2013*;181:22-30. Karger Publishers.
15. Levison, Sandra P. Renal disease in the elderly: the role of the renal biopsy. *Am J Kidney Dis* 1990;16:300-6.
16. Muriithi AK, Leung N, Valeri AM, et al. Biopsy-proven acute interstitial nephritis, 1993-2011: a case series. *Am J Kidney Dis* 2014;64:558-66.
17. González E, Gutiérrez E, Galeano C, et al. Early steroid treatment improves the recovery of renal function in patients with drug-induced acute interstitial nephritis. *Kidney Intern* 2008;73:940-6.
18. Dhaun N, Bellamy CO, Cattran DC, et al. Utility of renal biopsy in the clinical management of renal disease. *Kidney Int* 2014;85:1039-48.
19. Haas M, Spargo BH, Wit EJC, et al. Etiologies and outcome of acute renal insufficiency in older adults: a renal biopsy study of 259 cases. *Am J Kidney Dis* 2000;35:433-47.
20. Polito MG, de Moura LA, Kirsztajn GM. An overview on frequency of renal biopsy diagnosis in Brazil: clinical and pathological patterns based on 9617 native kidney biopsies. *Nephrol Dial Transplant*. 2010;25:490-6.
21. Hoy WE, Samuel T, Mott SA, et al. Renal biopsy findings among Indigenous Australians: a nationwide review. *Kidney Int* 2012;82:1321-31.
22. Paripović D, Kostić M, Kruščić D, et al. Indications and results of renal biopsy in children: a 10-year review from a single center in Serbia. *J Nephrol* 2012;25:9.
23. Prasad N, Kumar S, Manjunath R, et al. Real-time ultrasound-guided percutaneous renal biopsy with needle guide by nephrologists decreases post-biopsy complications. *Clin Kidney J* 2015;8:151-6.
24. Corapi KM, Chen JL, Balk EM, et al. Bleeding complications of native kidney biopsy: a systematic review and meta-analysis. *Am J Kidney Dis* 2012;60:62-73.
25. Cameron J. Stewart. Nephrotic syndrome in the elderly. *Semin Nephrol* 1996;16:319-29.
26. Fawcett IW, Hilton PJ, Jones NF, et al. Nephrotic syndrome in the elderly. *Br Med J* 1971;2:387-8.
27. Zech P, Colon S, Pointet PH, et al. The nephrotic syndrome in adults aged over 60: etiology, evolution and treatment of 76 cases. *Clin Nephrol* 1982;17:232-6.