

The comparison of vacuum assisted closure (VAC) and conventional treatment methods in postpneumonectomy empyema cases

Omer Cenap Gulyuz¹, Ozgur Omer Yildiz², Goktan Temiz³, Ilknur Aytekin Celik², Nurettin Karaoglanoglu²

¹Adiyaman University Education and Research Hospital, Department of Thoracic Surgery, Adiyaman, Turkey

²Yildirim Beyazıt University, Faculty of Medicine, Bilkent City Hospital, Department of Thoracic Surgery, Ankara, Turkey

³Adana City Hospital, Department of Thoracic Surgery, Adana, Turkey

Copyright © 2019 by authors and Annals of Medical Research Publishing Inc.

Abstract

Aim: Postpneumonectomy empyema is one of the most difficult clinical conditions in thoracic surgery. There is a wide range of conventional treatment options ranging from tube thoracostomy, antibiotic irrigation to open-window thoracostomy. Vacuum-Assisted Closure (VAC) therapy is also among the treatment options. In our study we aimed to compare the outcomes and efficiency of conventional treatment procedures and VAC.

Material and Methods: Eighteen male patients (average age 54.8± 18.68), who were diagnosed with postpneumonectomy empyema between July 2012 and November 2014, were divided into two groups. Nine patients (Group I) have been treated with conventional procedures, while the other nine patients (Group II) have been treated with VAC.

Results: Five patients in the Group I were cured in an average of 9.6 months. Four patients underwent additional surgical intervention and they remained in the empyema clinic for 12 months in the follow-up period. Seven patients in the Group II were cured during the follow up period of an average of 14.8 months. Two patients who developed bronchopleural fistula remained in the empyema clinic. Average length of hospital stay is 109.3 days for the Group I and 63 days for the Group II. The treatment of the Group II has been found more successful than the Group I in terms of pain status assessment, patient's comfort and postoperative cosmetic appearance.

Conclusions: VAC group success rate has been found higher in terms patient's comfort, the length of hospital stay and duration of empyema. Further studies are required to establish the success of this procedure.

Keywords: Postpneumonectomy empyema; Vacuum-Assisted Closure (VAC); Thoracostomy.

INTRODUCTION

One of the major reasons of morbidity and mortality in postpneumonectomy cases is the empyema developing during the postoperative period. The conventional treatment method for empyema has been antibiotic irrigation until the cavity is sterilized, in other words, modified Clagett method, during the early period and the window thoracostomy during the late period. The modified Clagett method has been successful in the early period of the treatment of empyema and has been the preferred method for the weak patients. However, the length of hospital stay ranging between 2-425 days and

high rates of complications (55%) encouraged the search for alternative treatment procedures (1). For that reason, vacuum assisted drainage and wound closure system were first applied intrathoracically by Ditterich et al. (2). Our purpose in this study is to discuss the results of the conventional treatment methods (tube thoracostomy, antibioteraphy, Clagett Method, thoracomyoplasty and open window thoracostomy etc.) and the Vacuum Assisted Closure (VAC) and to compare them in terms of their efficiencies for the treatment of the patients developing post pneumonectomy empyema or joint bronchopleural fistula.

Received: 10.06.2019 **Accepted:** 28.08.2019 **Available online:** 21.10.2019

Corresponding Author: Omer Cenap Gulyuz, Adiyaman University Education and Research Hospital, Department of Thoracic Surgery, Adiyaman, Turkey, **E-mail:** dr.ooyildiz@gmail.com

MATERIAL and METHODS

Eighteen cases, who developed postpneumonectomy empyema with or without bronchopleural fistula, were retrospectively examined in the department of Thoracic Surgery in Atatürk Chest Disease and Chest Surgery Training and Research Hospital between July 2012 and November 2014. The study was approved by the Institutional Ethics Committee and conducted in accordance with the ethical guidelines of the Helsinki Declaration.

Between 2012 and 2014, resection was performed for a total of 603 cases, 506 of which was for lung cancer and 97 for other illnesses. The pneumonectomy was performed for 103 cases, 65 of them being left pneumonectomy and 38 right pneumonectomy. Post-pneumonectomy empyema was recorded in 6 of these cases, 4 of which had no fistula. The cases were divided into two groups as the ones who were treated with conventional treatment methods such as tube thoracostomy, antibiotherapy, Clagett Method, thoracomyoplasty and open window thoracostomy and the ones who were treated with VAC. For nine cases, conventional treatment methods were applied and for the remaining nine cases VAC treatment was applied. Those who did not accept VAC treatment were included in group 1 who underwent conservative treatment. When empyema was identified among the patients who received conventional treatment methods, first drainage with tube thoracostomy, empiric antibiotherapy and irrigation were performed. Only povidone iodine and rifampicin wash were used for the patients. Local effect of antibiotics has not been utilized. However the patients were given certain dose of antibiotics treatment as prescribed by the infectious diseases specialist according to the wound location and the results of blood cultures in the first sessions after the empirical systemic antibiotics treatment. According to the presence and size of fistula, primary closure, extrathoracic muscle transpositions (myoplasty), bronchoscopic tissue adhesives were utilized. The patients in group 1 did not have thoracomyoplasty because of refusing second operation.

In the first session, open thoracic window process under general anesthesia and wound site debridement with VAC were performed for the patients who were treated with VAC. During the next sessions, sponge change was performed applying medical dressing with conscious sedation.

V.A.C. APPLICATION TECHNIQUE: The patients were intubated using endobronchial single-lumen tube in the lateral decubitus position. With an approximate 5- cm cut, an appropriate window was opened through a partial rib resection with the help of thoracoscopy from the remaining place of the previously located chest drain. The thorax cavity was debrided through the curettes and culture specimens were taken from wound sites. The inner thorax was mechanically cleaned with Povidone iodine or Rifampicin with saline solution. The vacuum pressure was arranged as 70-125 mm-Hg according to the patient. The appropriate antibiotherapy was started according to the culture results. The procedure was repeated together with

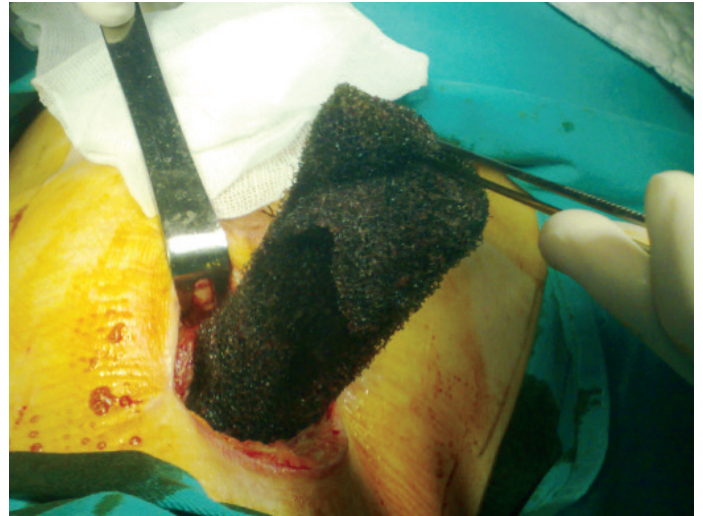


Figure 1. Placement of polyurethane sponge in VAC treatment, placement in a cavity

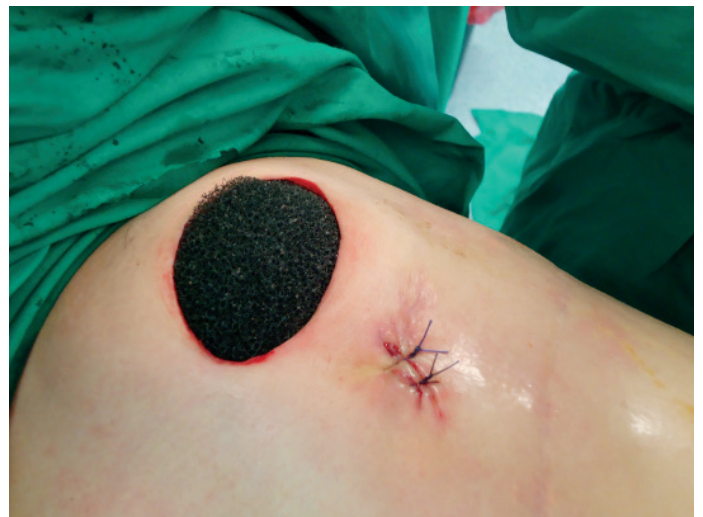

Figure 2. Placement of polyurethane sponge in VAC treatment, the end of the placement of the cavities

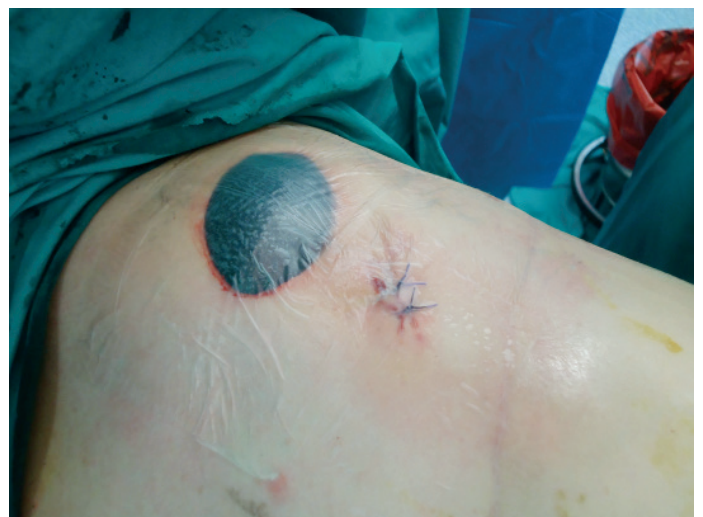

Figure 3. Placement of polyurethane sponge in VAC treatment, closing with drape for no air

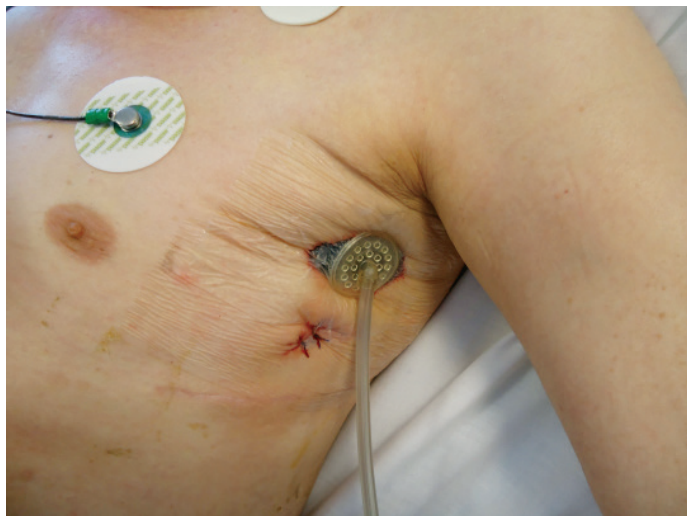


Figure 4

sedation in an average of 4-6 days. Sponge changes were performed under operating room conditions while the patient was awake with conscious sedation with epidural analgesia support. (Figure1, figure2, figure3, figure4) VAC was applied to one of the cases during re-thoracotomy and completion for the pneumonectomy. The VAC application was completed by filling the thorax cavity with saline solution containing iodine and rifampicin under general anesthesia together with blood congestion within the thorax cavity and formation of granulation tissue after the reduction of negative culture of the wound site and

the drainage.

No statistical evaluation has been done because of the low number of cases.

RESULTS

Post-pneumonectomy empyema was recorded in 6 of these cases, 4 of which had no fistula. The other 12 cases included in our study had been referred to our clinic from other clinics for further treatment. Atatürk Chest Diseases and Chest Surgery Education and Research Hospital is a leading hospital in this field and it is the biggest center for further treatment in Turkey where complicated cases are referred. Thus, we treat complications in cases whose primary surgery was not carried out in our hospital as well as major post-surgery pathologies that could arise due to different reasons.

Eighteen cases, who were suffering from empyema with bronchopleural fistula or without bronchopleural fistula after pneumonectomy were analyzed. All of the patients were male. The average age of the patients were 54.8 (min 18-max 68) years. The patients were divided into two groups:

Group I: Patients treated with conventional methods (Table 1)

Group II: Patients received VAC treatment (Table 2)

The average age was 55.2 (min 40-max 65) years in the

Table 1. The features of the Group I patients

Patient	Age	Sex	Smoking	Diabetes ellitus	COPD	CRT	MV
1	40	M	+	-	-	-	-
2	52	M	+	+	+	-	-
3	47	M	+	-	-	-	-
4	54	M	+	-	+	-	-
5	63	M	+	+	+	+	-
6	57	M	+	-	+	+	-
7	56	M	+	-	-	+	-
8	65	M	+	-	+	+	+
9	63	M	+	-	+	-	+

COPD: Chronic Obstructive Pulmonary Disease, CRT: Chemoradiotherapy, MV: Mechanic Ventilation

Table 2. The features of the patients in the Group II

Patient	Age	Sex	Smoking	Diabetes	COPD	CRT	MV
1	51	M	+	+	-	+	-
2	59	M	+	-	-	+	-
3	56	M	+	-	+	+	-
4	68	M	+	-	+	+	-
5	48	M	+	-	-	-	+
6	18	M	-	-	-	-	-
7	50	M	+	-	-	-	-
8	60	M	+	-	+	+	-
9	68	M	+	-	-	+	-

COPD: Chronic Obstructive Pulmonary Disease, CRT: Chemoradiotherapy, MV: Mechanic Ventilation

Group I. Pneumonectomy was applied to all of the cases because of non-small cell lung cancer. Five squamous cell carcinoma were reported in the pathological examination. One of them was in stage Ib and the rest were in stage IIIa. They included one carcinoid tumor, two synchronous tumors (squamous and adenocarcinoma) and one adenocarcinoma (stage IIb). Adjuvant chemotherapy was applied on four cases and postoperative radiotherapy was applied on three cases. Patients in Group I did not receive neo-adjuvant chemotherapy. Mechanical Ventilation was required for two postoperative patients. (Table 3)

The average age was 53.1 (min 18-max 68) years in the Group II. Two of the patients had tuberculosis history. Pneumonectomy was performed for seven of the cases because of non-small cell lung cancer. The pneumonectomy was performed for the 18 year old patient with post tuberculosis lung destruction. The first operation was done in another clinic and referred to us. Post-lobectomy remained parenchyma was destroyed so we perform pneumonectomy.

Four of them were in stage IIIa, one of them was in stage IIb and one of them was in stage IIIb. One of the cases

had tuberculosis-aspergillum, therefore upper lobectomy and myoplasty were performed because of the traumatic bronchus rupture. The case then underwent rethoracotomy, completion pneumonectomy and myoplasty. Six cases who were treated with VAC received chemotherapy and/or radiotherapy. Mechanical ventilation history was present in one preoperative case. (Table 4)

We performed primary suturing for early fistula cases and our general clinical approach is primary suturing and myoplasty. Because stapling is used for bronchial closure in recent years, we have not seen fistula case due to surgical technique.

In our study, VAC therapy was considered successful in comparison with the conventional treatment methods in terms of complication, the length of the hospital stay, follow-up without empyema and satisfaction of the patients. (Table 5) Patient satisfaction was assessed depending on the wound closure and negative results of cultures.

DISCUSSION

Postpneumonectomy empyema is a life threatening condition. It mostly occurs together with bronchopleural

Table 3. The surgical procedures applied previously to the Group I patients

Patient	First Operation	Complication	2 nd or 3 rd Operation/Treatment	Post treatment Status	Empyema Duration	Result
1	Right	PPA+Fistula	Irrigation+ 3 times of fibrin glue application+ Myoplasty	Absent	15 months	Accomplished
2	Right	PPA+Fistula	2 times Myoplasty	Fistula+, Empyema	25 months	Failure
3	Upper right lobectomy + chest wall resection	Perfusion and expansion defect in residual lung+ Empyema	Re- thoracotomy +Completing to pneumonectomy and opening thoracostomy	Empyema	7 months	Failure
4	Right	Empyema+ Fistula	Clagett Method+ Endobronchial stent application	Absent	6 months	Accomplished
5	Right	Empyema+ Fistula	Clagett Method+ Myoplasty	Recurrent tumor (superior vena cava syndrome)+ Fistula	15 months	Failure
6	Right	Post chemotherapy+ empyema	Clagett Method+ Myoplasty	Absent	4 months	Accomplished
7	Right	Eusophageal Fistula	Clagett Method+ Myoplasty+ Eusophageal Stent	Absent	13 months	Accomplished
8	Right	Fistula	Myoplasty	Empyema+ Mechanic Ventilation	1 months	Failure
9	Right Sleeve	Fistula+ Empyema	Myoplasty	Absent	10 months	Accomplished

PPA: Postpneumonectomy Empyema

Table 4. Previously applied procedures in the Group II

Patient	First Operation	Complication	Second Operation/ Treatment	Post Treatment Status	Empyema Duration
1	Left	PPA (without fistula)	Clagett Method	Empyema	18 months
2	Right	PPA (without fistula)+Chest wall necrosis in related to RT	Chest wall Resection+ Myoplasty	Empyema+ Without Fistula	3 months
3	Left	PPA (without fistula)	Clagett Method	Empyema	13 months
4	Right	PPA+ BPF	Closure of fistula+ Myolasty	Empyema+ Without Fistula	12 months
5	Right	PPA+ BPF	Closure of fistula+ Myolasty	Micro Fistula+ Empyema	10 months
6	Upper right lobectomy+ myoplasty	BPF+ Empyema	Completed Pneumonectomy + Myoplasty	Empyema+ Without Fistula	4 months
7	Right	Closure of fistula+ Myoplasty	Closure of fistula+ Myoplasty	Micro Fistula+ Empyema	9 months
8	Right	PPA (without fistula)	Clagett Method	Empyema	7 months
9	Right	PPA+ BPF	Closure of fistula+ Myoplasty	Fistula+ Empyema	2.5 months

BPF: Bronchopleural Fistula

Table 5. Comparison of the groups

Groups (n9)	Length of Hospital Stay (Day)	Postoperative Follow-up Period (month)	Complication (pain) (n)	Follow-up without empyema (n)	Patient's satisfaction
Group 1	109.2	9.5	8	5	Bad
Group 2	63	14.8	2	7	Good

fistula making its treatment difficult. Among all surgical resections, the rate of BPF development varies between 0.3-11% and is most commonly seen after right pneumonectomy. The incidence of fistula increases in surgical procedures performed in infectious diseases such as tuberculosis. The specified mortality rates are 30-70%, and early diagnosis and appropriate surgery are essential (3). Clagett method is a successful method in treating early period empyema. However the variation in average length of hospital stay between 2-425 days and high levels of complication rates (55%) has encouraged the search for alternative procedures (1). Similarly, although open window thoracostomy seems to be an appropriate treatment option for the chronic empyema cases and for the patients who are not appropriate for further surgical procedures, it has got major disadvantages including the long treatment durations such as 2-7 months and its being an uncomfortable method because of the requirement for daily povidone iodine (4). In our study, most of the patient's primer pathology is non-small lung cancer and it is still frequent in males in our country. The average length of hospital stay was 109.3 (12-204) days in the Group I and the surgical procedures that were performed were more than one. In five patients, the empyema could be cured at the end of 9.6 months in average (4-15). Empyema continued during the mentioned period in four patients. Permanent vacuum proves to be more effective for wound site cleaning in comparison to the conventional methods.

VAC therapy has proven more influential compared to the conventional treatment methods in postoperative empyema (5). In a study with 19 cases of empyema series by Palmen, eight cases received daily medical dressing for open window thoracostomy, 11 cases were treated with VAC following open window thoracostomy and these cases were cured in 39 ± 17 and 31 ± 19 days, respectively. The average length of hospital stay for VAC applied patients was found as 55 days, and for the ones VAC was not applied was 101 days. All of the patients were followed up for 46 ± 19 months in average (6). Al Muffarej et al searched six cases of empyema series (two of them were PPA and four had other empyema) through the VAC method (8). In the mentioned series, one of the cases of PPA was identified with pseudomonas reproduction, but the other case was not identified with any microorganism. In the cases, sterilization in thorax was provided at the end of 53 days in average (40 and 63). Matzi et al reported pseudomonas reproduction in culture of a 20 year-old case with PPA and who was cured through VAC, and sterilization in thorax was fulfilled after 46 days (5). In our study, five of the cases in Group II were pseudomonas, there was polymicrobial reproduction in two cases, MRSA in one case and pleural fluid microorganism in one case. The tissue cultures did not contain microorganisms. The thorax sterilization of the patients in this group took 63 days in average (25-148). The mean sponge change per capita was found as 5.4 times while Aru et al found

11.4 times (7). Al Mufarej et al found it as 5.2 (8). Saadi et al reported that culture results are not important whether they are negative or positive only after the healthy granulation tissue develops (9). Closure of the residue space with Clagett method is sufficient after the cavity heals with sufficient granulation tissue, before the thoracostomy closure. Yet, in terms of cosmetics and its being less invasive, it seems to be a better option in comparison with the other cavity filling methods. For this reason, we preferred closure by modified Clagett method in the cases for who VAC was applied.

CONCLUSIONS

VAC treatment method has been found visible and reasonably better compared to classical treatment methods in the cases of postpneumonectomic empyema cases, which are among the difficult clinical entities in terms of treatment and follow up in the thoracic surgery clinics.

As all thoracic surgeons agree, treatment process in postpneumonectomic empyema cases is long and difficult for the patient. In our study, we found that the length of hospital stay for the patients in the VAC group has shortened, empyema duration decreased and life quality of the patients proportionally increased. VAC treatment which is not difficult in terms of application and follow-up can be successfully applied in appropriate patients.

Competing interests: The authors declare that they have no competing interest.

Financial Disclosur: There are no financial supports

Ethical approval Ethics committee approval was received from Karatay University Faculty of Medicine. 2019/0036

Omer Cenap Gulyuz ORCID:0000-0001-8528-5567

Ozgur Omer Yildiz ORCID:0000-0001-7314-3131

Goktan Temiz ORCID:0000-0002-8025-5315

Ilknur Aytakin Celik ORCID:0000-0003-0754-680X

Nurettin Karaoglanoglu ORCID:0000-0003-2827-6044

REFERENCES

1. Zaheer S, Allen MS, Cassivi SD, et al. Postneumonectomy empyema: results after the Clagett procedure. *Ann Thorac Surg* 2006;82:279-86.
2. Ditterich D, Rexer M, Rupprecht H. Vacuum assisted closure in the treatment of pleural empyema first experiences with intrathoracal application. *Zentralbl Chir* 2006;131:133-8.
3. Kim EA, Lee KS, Shim YM, et al. Radiographic and CT Findings in Complications Following Pulmonary Resection. *Radiographics* 2002;22:67-86.
4. Garcia-Yuste M, Ramos G, Duque JL, et al. Open-window thoracostomy and thoracomyoplasty to manage chronic pleural empyema. *Ann Thorac Surg* 1998;65:818-22.
5. Matzi V, Lindenmann J, Porubsky C, et al. Intrathoracic insertion of the VAC device in a case of pleural empyema after pneumonectomy. *Ann Thorac Surg* 2007;84:1762-4.
6. Palmen M, van Breugel HN, Geskes GG, et al. Open window thoracostomy treatment of empyema is accelerated by vacuum-assisted closure. *Ann Thorac Surg*. 2009;88:1131-6.
7. Aru GM, Jew NB, Tribble CG, et al. Intrathoracic vacuum-assisted management of persistent and infected pleural spaces. *Ann Thorac Surg* 2010;90:266-70
8. Al-Mufarrej F, Margolis M, Tempesta B, Strother E, Gharagozloo F. Outpatient management of post-pneumonectomy and post-lobectomy empyema using the vacuum-assisted closure system. *Surg Today* 2010;40:711-8.
9. Saadi A, Perentes JY, Gonzalez M, et al. Vacuum-assisted closure device; a useful tool in the management of severe intrathoracic infections. *Ann Thorac Surg* 2011;91:1582-9.