

Morphological evaluation of maxillary and mandibular canines using cone-beam computed tomography in Turkish population

Emrah Karataslioglu¹, Fahrettin Kalabalik²

¹Izmir Katip Celebi University, Faculty of Dentistry, Department of Endodontics, Izmir, Turkey

²Izmir Katip Celebi University, Faculty of Dentistry, Department of Oral and Maxillofacial Radiology, Izmir, Turkey

Copyright © 2019 by authors and Annals of Medical Research Publishing Inc.

Abstract

Aim: The aim of the present study was to evaluate the root canal morphology of the maxillary and mandibular canines using cone-beam computed tomography (CBCT) in a Turkish population.

Material and Methods: CBCT images of 377 maxillary and 419 mandibular canines were examined. The number of roots and their morphology, number of canals per root and canal configurations according to the Vertucci's classification were recorded. Canal configurations and presence or absence of lateral canals were examined regarding gender, age groups, and tooth side. Anatomic symmetry in canal morphology of bilateral canines was also recorded. The data were evaluated by Pearson Chi-square test ($p < .05$).

Results: The prevalence of type I canal configuration in maxillary and mandibular canines was 96.3% and 87.8%, respectively. Twenty-one percent of the maxillary canines and 14.8% of the mandibular canines had accessory canals. In maxillary canines, no significant difference was observed in the prevalence of accessory canals between males and females and between age groups. In mandibular canines, lateral canals and complex canal morphology were detected significantly more often in females. Prevalence of complex root canal increased with age in both maxillary and mandibular canines and great anatomic symmetry was observed in canal morphology of bilaterally present teeth in the same patient.

Conclusion: CBCT is a useful tool for evaluation of root and canal morphology. Our results can provide valuable aids for clinicians during root canal treatment of canines.

Keywords: Canines; cone-beam computed tomography; configuration; root canal morphology; Turkish population.

INTRODUCTION

A comprehensive knowledge of tooth morphology and its possible variations plays an important role in the success of root canal treatment. Clinicians should be aware of the variety of canal configurations, additional roots and canals, presence or absence of accessory canals for achieving adequate root canal cleaning and shaping as well as three-dimensional hermetic canal filling (1,2). Therefore, it is necessary to investigate tooth and canal morphology and their variations.

The morphological investigation of root canals have been performed through different methods including; clearing and staining (3-6), serial cross-sectioning (7),

conventional periapical radiographic examination (8,9), scanning electron microscope (10), clinical operating microscope (11) and micro-computed tomography (12,13). In recent years cone-beam computed tomography (CBCT) has become increasingly popular in endodontic practice and has been also used to investigate root canal morphology in different studies since 1990 (14-19). The main advantages of this technique are being accurate, non-invasive, applicable and cost-effective to use. Moreover, it provides high resolution three-dimensional images in lower radiation doses and it is the only method that allows clinical use (14,19,20).

Several studies investigated maxillary and mandibular

Received: 05.09.2019 Accepted: 22.09.2019 Available online:

Corresponding Author: Fahrettin Kalabalik

E-mail: kalabalikfahrettin@hotmail.com

canines' root canal morphology using the aforementioned evaluation methods in diverse populations. Vertucci (4) investigated maxillary and mandibular canines in the Caucasian population and classified different types of pulp space configuration. He reported a single canal with 1 foramen (Vertucci type I) in 100% of maxillary canines and 78% of mandibular canines. Çalışkan et al. (5) examined the root canal configuration of 100 maxillary and 100 mandibular canines in a Turkish population. They reported 93.48% of maxillary and 80.39% of mandibular canines had Vertucci type I canal configuration. The other study in Turkish population was investigated by Sert and Bayirli (6). They reported that the prevalence of Vertucci type I canal configuration in the maxillary canines was 91% and 96%; in the mandibular canines 90% and 62% for males and females, respectively. In Iranian population Soleymani et al. (19) examined root canal morphology of mandibular canines and found that 89.7% of 269 examined teeth had the most common configuration; Vertucci type I. Amardeep et al. (16) investigated root canal anatomy of single-rooted canines in an Indian population and reported that the majority of the teeth had Vertucci type I canal configuration in both maxillary canines (81.6%) and mandibular canines (79.6%).

Although the morphologies and root canal configurations of canines have been extensively investigated in diverse populations, there have been a limited number of studies that researched the relationship between demographic factors (age and gender) and morphological variations in canine teeth (6,17,18,21).

Anatomical symmetry of contralateral teeth (left and right side) has a great importance when treating two opposite teeth in the same patient from the clinical point of view (15). Although its high clinical relevance, limited data are available in the literature about anatomical symmetry of canine teeth (17,18).

Therefore, the aims of this study were;

1. to investigate the root and root canal morphology and morphological diversity of the maxillary and mandibular canines in a Turkish population using CBCT imaging and to investigate any associations between the morphological diversity and demographic factors (age and gender).
2. to determine the symmetry in the root canal morphologies between contralateral sides in the same patient.
3. to investigate the prevalence and location of accessory canals in canines and analyse the prevalence of accessory canal in patients belonging to various age groups, gender and quadrant.

MATERIAL and METHODS

The present study was approved by the Ethical Committee of Izmir Katip Celebi University Non-Interventional Clinical Studies Institutional Review Board (PRO2018-300). A total of 454 Turkish patients' dental CBCT images which had already been archived in the radiology clinic

of Izmir Katip Celebi University Dentistry Faculty from 2016 to 2018, were selected and examined. All the CBCT images were obtained from patients that were referred to the clinic and required a CBCT scanning as part of their dental examination, diagnosis or treatment. Images were obtained by using a NewTom 5G CBCT machine (QR Srl, Verona, Italy) at 110 kVp, 20 mA and 12×8 FOV. The voxel size of the images was 0.15 mm and the slice thickness was 1.0 mm.

Only high-quality and free of artifact CBCT images that showed at least 1 maxillary or mandibular canines with completely formed apices were included in the study to perform an accurate and correct image analysis. Exclusion criteria for canines were; presence of previously root canal treatments, intracanal posts, internal/external root resorptions, canal obliterations and coronal restorations.

Following the determination of the inclusion/exclusion criteria, images of 377 maxillary and 419 mandibular canine teeth obtained from 220 patients' CBCT scans that fulfill the criteria were displayed by NNT version 8.0 3D software using a Dell Precision T5400 workstation (Dell, Round Rock, TX, USA). Each image was evaluated in three planes (axial, sagittal and coronal) in a darkroom by two calibrated examiners [one endodontist (E.K.) and a radiologist (F.K)]. The images were evaluated twice, with a 4-week interval between the assessments. The reliability data were analyzed using the kappa test. After intraexaminer calibration, the 2 examiners separately evaluated the all images. If a disagreement in the explication of an image was found, a second radiologist and an endodontist were assisted to perform a definitive evaluation and then, in reaching a decision.

The following information was recorded

1. The age and gender of the patients: Age group was separated into 3 groups (15-30, 31-45 and 46-60 years old) for analysis.
2. The numbers of roots of canine teeth.
3. The presence or absence of accessory canals for each canine [if the present location was also recorded (apical, middle or coronal third)].
4. The anatomic symmetry for the root canal configuration (if canine teeth were contralaterally present in the mouth).
5. The root canal configuration for each root. The root canal configuration was classified using Vertucci's classification method (4).
 - Type I: Single canal leaves the pulp chamber and ends as single apical foramen (1-1).
 - Type II: Two distinct canals leave the pulp chamber and end as single apical foramen (2-1).
 - Type III: Single canal leaves the pulp chamber, divides into two separate canals within the root and end as single foramen (1-2-1).
 - Type IV: Two distinct canals are present from the pulp chamber to the apex and end as two separate apical foramen (2-2).
 - Type V: Single canal leaves the pulp chamber but divides into two separate canals within the root and

end as two foramen (1-2).

- Type VI: Two separate canals leave the pulp chamber, merge at the midpoint of the root, and then divide again into 2 with 2 separate apical foramen (2-1-2).
- Type VII: Single canal leaves the pulp chamber, divides, and then rejoins within the root, and finally redivides into 2 separate canals with 2 separate apical foramen (1-2-1-2).
- Type VIII: Three root canals appears from the pulp chamber to the apex (3-3)

Additional type: In our study in addition to the Vertucci's classification additional type of root canals were determined according to the Sert and Bayirli's [6] and Ng et al.'s [22] criteria; two separate root canals leave the pulp chamber, merge at the midpoint of root, and then divide again into 2 separate canal and end as one apical foramen (2-1-2-1).

In the present study, to avoid confusing definitions of root canal complexity, 2 distinct categories were used, namely, non-complex and complex. Vertucci type I was defined as non-complex and all other types were defined as complex root canals.

The descriptive analyses of the data and other statistical analyses were performed using the Statistical Package for the Social Sciences software version 21.0 (SPSS Inc., Chicago, IL, USA). Pearson Chi-square test was used to evaluate associations among variables of root canal morphology, gender, age and tooth side. The level of statistical significance was set at 0.05.

RESULTS

A total of 220 patients, 121 female and 99 male individuals were included in this study. They were aged between 15 years and 60 years (average age: 32 years).

A total of 377 maxillary canines, (including 190 right and 187 left) and 419 mandibular canines (including 209 right and 210 left) were evaluated by the examiners.

The intraexaminer reliability was 0.83, and the interexaminer reliability was 0.79 (kappa test results).

Maxillary Canines

All the maxillary canines evaluated in this study had one root. The majority of canal configuration was type I (96.3%; n= 363), followed by type III (3.2%; n= 12) based on Vertucci's classification. In addition, two of the maxillary canines (0.5%) had additional type canal configuration (Table 1). A hundred and seventy-nine patients had bilateral maxillary canines and 173 of them showed anatomic symmetry in root canal configurations (96.6%) and 6 patients who had bilateral maxillary canines had asymmetrical root canal configuration (3.4%) (Figure 1).

The prevalence of accessory canals in maxillary canines was 21% (n=79). All the accessory canals evaluated in this study were localized in the apical one-third region of the apex. No significant difference was observed in the prevalence of accessory canals between males and

females ($p > .05$). However, the prevalence of accessory canals in right maxillary canines was 2.4 times greater than left maxillary canines and this difference was statistically significant ($p < .05$). The highest prevalence of accessory canal in maxillary canines among all age groups was the 15-30 year (22.02%), whereas the lowest was the 46-60-year age group (19.19%). However, there was no significant difference between age groups (Table 2).

In maxillary canines, no significant difference was found between males and females and between left and right mandibular canines in terms of complexity of root canal configuration ($p > .05$). With regard to the age groups, although 46- to 60-year age group was showed the highest prevalence of complexity, this difference was not statistically significant ($p > .05$) (Table 3).

Mandibular Canines

The majority of mandibular canines had one root (96.6% n=405), whereas 3.4% had two separate roots (n=14). A statistically significant difference was observed for the number of roots between males and females ($p < .001$), whereas female patients had a higher percentage of two roots compared with that in males [9.1% (n=11) for females and 3% (n=3) for males]. A total of 433 mandibular canine roots (405 from one rooted canines + 28 from two rooted canines) were analysed for identification of canal morphology. In these two-rooted cases, Vertucci type I canal configuration was presented in each root, existing through a main apical foramen.

The various root canal configurations were type I (87.8%; n=380), type III (9%; n=39), type V (2%; n=9) and type VII (0.5%; n=2) based on Vertucci's classification. In addition, three of the mandibular canines (0.7%) had additional type canal configuration (Table 4) (Figure 2). Two hundred and seven patients had bilateral mandibular canines and 176 of them showed anatomic symmetry in root canal configuration (85%) and 31 patients had asymmetrical root canal configuration (15%) (Figure 3).

Overall, 14.8% (n=64) of the mandibular canines had accessory canals which were localized in the apical one-third region of the apex. A significant difference was observed in the prevalence of accessory canals between males and females ($p = .003$) whereas female patients had a higher percentage of accessory canal compared with that in males [33.06% (n=40) for female and %24.24 (n=24) for male individuals]. In addition, no significant difference was observed between left and right mandibular canines in this manner ($p > .05$). In mandibular canines, the highest prevalence of the accessory canal was the 31-45 year age group (15.87%), whereas the lowest was the 46-60 year age group (13.56%). However, there was no significant difference between the age groups according to the prevalence of accessory canals in mandibular canines ($p > .05$) (Table 2).

A significant association was observed between canal complexity and gender in mandibular canines ($p < .001$). The prevalence of complex canal was higher in females (17.55%; n=33) than in males (8.16 %; n=20). No significant

difference was found between canal complexity and tooth quadrant ($p > .05$). The prevalence of complex root canal in all age groups was tabulated in Table 3. The lowest

prevalence of the complex root canal was seen in the 15-30 year age group (9%; $n=17$) and there was a significant difference between age groups in this manner ($p < .05$).

Table 1. Number and prevalence of root canal types in maxillary canines according to gender and tooth position

Details	No. of teeth	Type I n (%)	Type II n (%)	Type III n (%)	Type IV n (%)	Type V n (%)	Type VI n (%)	Type VII n (%)	Type VIII n (%)	Type Additional n (%)
Female	208	201 (96.6)	-	5 (2.4)	-	-	-	-	-	2 (1)
Male	169	162 (95.9)	-	7 (4.1)	-	-	-	-	-	-
Left	187	181 (96.8)	-	5 (2.7)	-	-	-	-	-	1 (0.5)
Right	190	182 (95.8)	-	7 (3.7)	-	-	-	-	-	1 (0.5)
Total	377	363 (96.3)	-	12 (3.2)	-	-	-	-	-	2 (0.5)

Table 2. The number and prevalence of accessory canals in the maxillary and mandibular canines by gender, tooth side and age

No. of teeth	Gender		Tooth Side		Age (years)		
	Male	Female	Right	Left	15-30	31-45	46-60
Maxillary canines(n=377)	38/169	41/208	56/190	23/187	37/168	23/110	19/99
Prevalence (%)	22.5	19.7	29.4*	12.3	22.02	20.9	19.19
Mandibular canines(n=433)	27/245	37/188	32/218	32/215	28/189	20/126	16/118
Prevalence (%)	11	19.7 ^a	14.7	14.9	14.81	15.87	13.56

* Significant difference compared with left canines ($P < .05$)

^aSignificant difference compared with male ($P = .003$)

Table 3. Number and prevalence of complex canal configuration in the maxillary and mandibular canines by age

No. of teeth	Age (years)		
	15-30	31-45	46-60
Maxillary canines (n=377)	6/168	4/110	4/99
Prevalence (%)	3.58	3.63	4.04
Mandibular Canines (n=433)	17/189	18/126	18/118
Prevalence (%)	9*	14.3	15.25

*Significant difference compared with 31-45 and 36-60 age groups.

Table 4. Number and prevalence of root canal types in mandibular canines according to gender and tooth position.

Details	No. of roots	Type I n (%)	Type II n (%)	Type III n (%)	Type IV n (%)	Type V n (%)	Type VI n (%)	Type VII n (%)	Type VIII n (%)	Type Additional n (%)
Female	188	155 (82.4)	-	21 (11.2)	-	7 (3.7)	-	2 (1.1)	-	3 (1.6)
Male	245	225 (91.8)	-	18 (7.3)	-	2 (0.8)	-	-	-	-
Left	215	187 (86.9)	-	21 (9.8)	-	5 (2.3)	-	1 (0.5)	-	1 (0.5)
Right	218	193 (88.5)	-	18 (8.3)	-	4(1.8)	-	1 (0.5)	-	2 (0.9)
Total	433	380 (87.8)	-	39(9)	-	9 (2)	-	2 (0.5)	-	3 (0.7)

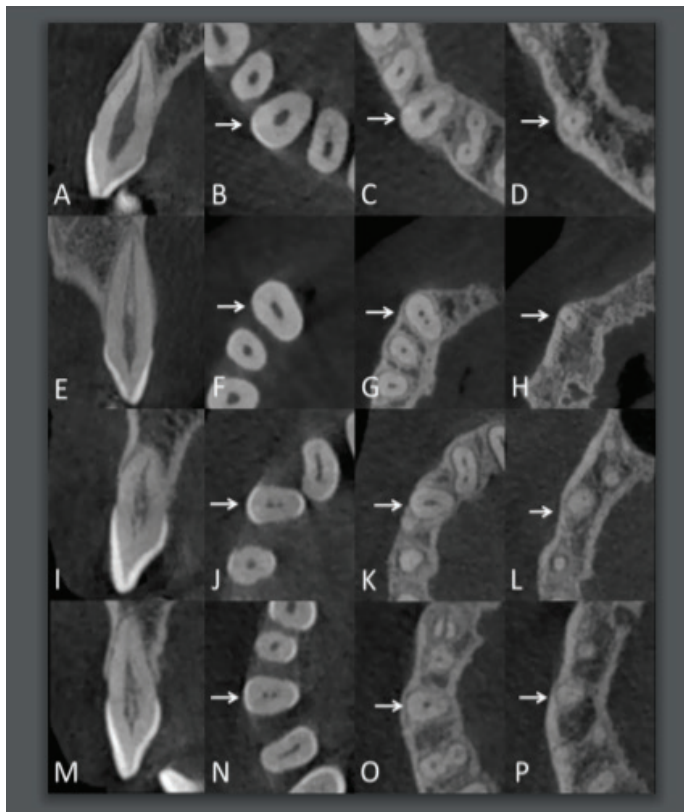


Figure 1. CBCT images of maxillary canines. (A-D) Slices of type I canal configuration. (A) Sagittal, (B, C,D) coronal, middle and apical third axial slices, respectively. (E-H) Slices of type III canal configuration. (E) Sagittal, (F, G, H) coronal, middle and apical third axial slices, respectively. (I-P) Slices of additional type canal configuration. (I,M) Sagittal, (J,N) coronal, (K,O) middle and (L,P) apical third axial slices. Arrows indicate the examined teeth.

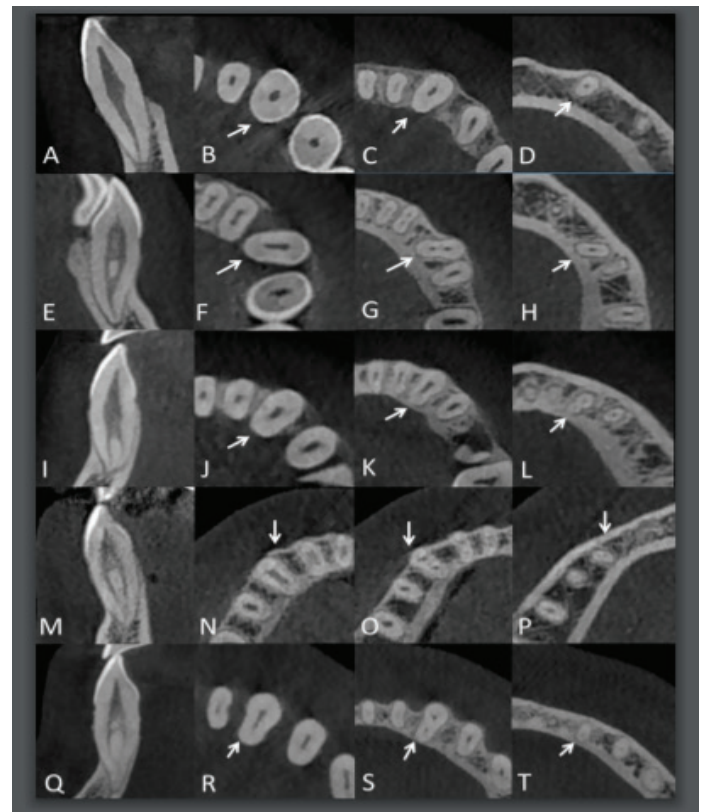


Figure 2. CBCT images of mandibular canines. (A-D) Slices of type I canal configuration. (A) Sagittal, (B, C, D) coronal, middle and apical third axial slices, respectively. (E-H) Slices of type III canal configuration. (E) Sagittal, (F, G, H) coronal, middle and apical third axial slices, respectively. (I-L) Slices of type V canal configuration. (I) Sagittal, (J, K, L) coronal, middle and apical third axial slices, respectively. (M-P) Slices of type VII canal configuration. (M) Sagittal, (N, O, P) coronal, middle and apical third axial slices, respectively. (Q-T) Slices of additional type canal configuration. (Q) Sagittal, (R,S, T) coronal, middle and apical third axial slices, respectively. Arrows indicate the examined teeth.

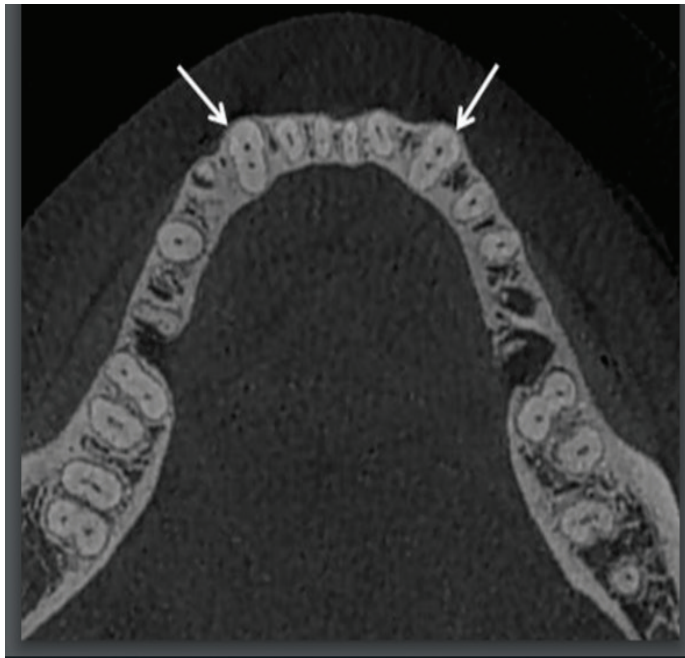


Figure 3. CBCT image of bilateral symmetric mandibular canines on axial slice (arrows)

DISCUSSION

The root canal morphology of teeth had been investigated using different methods (4-6,8,9,22). Most of these methods involve invasive procedures or two-dimensional images captured by conventional radiographs. In addition to these methods, micro-CT evaluation has gained increasing significance in the assessment of root and canal morphology because of its highest 3D imaging quality. However, excessive radiation doses and high-cost make it unsound for clinical application. Additionally, it can only be used for laboratory studies on extracted teeth. Recently, in morphological studies which investigating root and canal configuration, CBCT is widely being used (14,16,18,19). CBCT is a radiographic examination that provides 3D examination of roots and canals and also provides a non-invasive and clinically applicable and accurate examination of canal morphology and additional structures (14,20,23). Thus, in the present study we used CBCT scans to investigate the root canal morphology of canines.

Maxillary Canines

In the present study, the majority of root canal configuration for maxillary canines was Vertucci type I in 96.3% of the total maxillary canine teeth. This result is consistent with the results reported by Vertucci (100%) (4), Pineda & Kuttler (100%) (8), Çalışkan et al. (93.48%) (5), Sert and Bayırlı (91% male and 96% female) (6) and Amardeep et al. (81.6%) (16). Type III was found the second common canal configuration with a ratio of 3.2% in maxillary canines which is consistent with the results reported by Çalışkan et al. (4.35%) (5) and Sert and Bayırlı (4%) (6), who also included Turkish population. However, the presence of type III canal configuration in maxillary canines was not reported in previous studies performed by Vertucci (4) and

Pineda & Kuttler (8) who studied in American and Mexican populations, respectively. In addition, Amardeep et al. (16) reported the prevalence of type III configuration with the ratio of 11.6% in Indian population which is higher than our result. These conflicting findings among the studies may have been due to the different examined racial groups.

One of the major advantages of using CBCT in the morphological studies is allowing the clinician to investigate anatomic symmetry of the root canal configurations of the teeth that was bilaterally present in the same patient. In clinical practice, anatomic symmetry is crucial when treating 2 opposite teeth in the same patient (17). The result of the present study revealed a great rate of anatomic symmetry in maxillary canines (96.6%), only 6 of the 179 patients had asymmetric bilateral canines. These data may provide useful information to clinicians during root canal treatment of contralateral canines. To the best of our knowledge, there are no available data in the current literature on the bilateral occurrence of root canal configuration among maxillary canines. Therefore, our results could not be compared with the findings obtained by the other studies on this topic.

Adequate knowledge of the accessory canals and their locations are essential prerequisites for successful root canal treatment. They have been a direct impact on the unfavorable outcomes of canal treatment such as canal reinfections and post-treatment disease (24). Several morphological studies that also examined the accessory canal of maxillary canines in different populations have been available in endodontic literature and different results were reported by the examiners. Vertucci (4) determined the prevalence of accessory canals in maxillary canines to be 27% and reported that the accessory canals are located in the apical one-third region in most of the cases. De-Deus (3) found the percentage of accessory canals in maxillary canines to be 16.4%. Pineda & Kuttler (8) examined 260 maxillary canines using conventional radiographic method in a Mexican sub-population and reported that 29.3% of maxillary canines had accessory canal located mostly in the apical one-third of the roots. Furthermore, two other previous studies in the Turkish population that were performed by Çalışkan et al. (5) and Sert and Bayırlı (6) have found this ratio to be 45.64% and 28.5%, respectively. In the present study, the prevalence of accessory canal in maxillary canines was 21% (n=79). These different results among the studies may have been caused by several possible reasons, such as evaluation methodologies, sample size, ethnic origin and/or regional diversity of the country. However, our related findings about the location of accessory canal in maxillary canines are in accordance with the results of the aforementioned studies. All these studies results confirm the evidence that, in maxillary canines, accessory canals are the most prevalent in the apical one-third region (4). It is interesting to note that a statistically significant difference was found between left and right maxillary canines in terms of the prevalence of accessory canals and this difference was difficult to explain.

The result of the present study showed that there was no statistically significant difference between male and female patients and also between left and right maxillary canines regarding to the prevalence of complex root canal. Although no available data are present concerning the effect of tooth side (left-right) on the complexity of root canal in maxillary canines, two previous studies that were carried out in Turkish population investigated the influence of gender on the canal morphology and complexity (6,25). Both studies also reported higher prevalence of canal complexity in males than in females in maxillary canines which was consistent with our current study. However, in these 2 previous studies, statistical analysis was not performed to determine any statistical difference between males and females patients regarding to canal complexity. Hence, our results could not be compared with the findings obtained by these studies on this topic.

Mandibular Canines

Although mandibular canines usually have one root canal, the prevalence of two roots and two distinct canals have been reported to be 1.7% to 5% in several studies (12,26,27). These findings were harmonious with our result in which 3.4% of the total mandibular canines had two roots and two distinct canals.

In the present study, Vertucci type I (87.8%; n=380) was the most common root canal configuration in mandibular canines followed by type III with a prevalence of 9% (n=39) of all specimens. Several studies that were performed in different populations, showed type I as the most common root canal configuration, ranging from 78% to 92.2%, which were consistent with that observed in our study (4-6,8,26). In addition, with regard to the prevalence of type III canal configuration, similar results were also found in studies in Turkish (5) and Indian (16) populations. Other studies in American (4), Mexican (8) and Brazilian (26) populations reported that type II as the second common root canal configuration. This result was inharmonious with our finding. The differences among the results of the studies may due to the variations of examination methods, sample sizes and differences in race of the examined population. Therefore, further studies should be conducted to investigate this issue in various populations.

According to the result of the present study, 85% of the bilateral mandibular canines exhibited great anatomic symmetry in root canal configuration. This finding is very important for clinicians to predict the configuration of canine teeth when treating two opposite teeth in the same patient. Although several articles that reported on the anatomic symmetry of molars (15) and incisors (17,18,28) have been available on the literature, there has been a limited number of studies that concerning the anatomic symmetry of canine teeth. The results of these studies were harmonious with our results (17,18). Further studies should be designed to evaluate anatomic symmetry in other types of teeth and population due to its clinical relevance.

In the present study, 15% of the mandibular canines had

accessory canals which were located in the apical one-third of the root within 3 mm from the apex. Vertucci (4) examined frequency and location of accessory canals in 100 mandibular canines using clearing and staining technique and found accessory canals in 30% of the samples, located at the cervical (n=1), middle (n=5) and apical (n=24) thirds. De-Deus (3) investigated 1140 human teeth using the same technique and reported the presence of accessory canals in mandibular canines as 6.8%. Versiani et al. (13) examined 100 mandibular canines using microcomputed tomography and reported that 69% of the samples had accessory canals located at the middle (n=4) and apical (n=65) thirds. Amardeep et al. (16) found the presence of accessory canals in mandibular canines to be 12.8% which were located in the apical one-third within 2 mm from the root apex. Such differences could be explained through differences in sample origin or racial factors, as well as the evaluation methods. However, these results confirm the evidence that, in mandibular canines, accessory canals are the most prevalent in the apical third.

The result of the present study showed that complex root canals in mandibular canines are presentsignificantly more often in females compared to males. This finding was in accordance with the result of previous study performed by Sert and Bayırlı (6) but was different from that of Altunsoy et al. (25). These variations may be attributed to differences in research methods, sample size and/or regional diversity of the country. Additionally, the results of these previous studies (6,25) revealed that gender was an important demographic factor on the canal morphology and complexity of mandibular canine teeth. This finding was consistent with the result of our current study.

According to the result of the present study, presence of complex root canal in mandibular canines was not an uncommon pattern and was seen more often in older patients than younger ones. Similar to the maxillary canines, in the mandibular canines the prevalence of non-complex (Vertucci type I) canal configurations decreases as age increases and young patients tend to have large single canals. Additionally, this difference was statistically significant in mandibular canines. This issue may be explained by natural physiological aging which tends to modify root canal system morphology due to the apposition of secondary dentine over the lifetime of the tooth. Similar result from a current study that was conducted on various type of teeth at different age intervals was reported by Martins et al. (21). On contrary, two in vivo CBCT studies analysed anterior mandibular teeth (central and lateral incisors and canine) anatomy at different age intervals reported conflicting result which was a lower prevalence of multiple root canals on the older groups when compared to the younger ones. (17,18). Because three anterior tooth groups were analysed together as a major group and not individually in both studies, this may cause a contradiction on results.

CONCLUSION

Based on the results of the present study, it can be concluded that CBCT may be recommended as an effective imaging device for identifying the root and canal morphology. The root and canal morphologies of the maxillary and mandibular canines were highly variable in the Turkish population. Clinicians should be aware of these morphological diversities during endodontic treatment of canines. The findings of the present study may be useful for clinicians to increase favourable treatment outcomes.

Acknowledgements: The authors thank Dr Şükrü Enhoş for his help with the manuscript. The authors thank Dr Ferhan Elmalı for statistical analyses and his help with the manuscript.

Competing interests: The authors deny any conflicts of interest related to this study.

Financial Disclosure: This research did not receive any specific grant from funding agencies in the public, commercial, or not-for-profit sectors.

Ethical approval: The present study was approved by the Ethical Committee of Izmir Katip Celebi University Non-Interventional Clinical Studies Institutional Review Board (PRO2018-300).

*Emrah Karataslioglu ORCID:0000-0002-4721-591X
Fahrettin Kalabalik ORCID:0000-0001-7084-4995*

REFERENCES

- Krasner P, Rankow HJ. Anatomy of the pulp-chamber floor. *J Endod* 2004;30:5-16.
- Cantatore G, Berutti E, Castellucci A. Missed anatomy: frequency and clinical impact. *Endod Topics* 2006;15:3-31.
- De Deus Q, Horizonte B. Frequency, location, and direction of the lateral, secondary, and accessory canals. *J Endod* 1975;1:361-6.
- Vertucci FJ. Root canal anatomy of the human permanent teeth. *Oral Surg Oral Med Oral Pathol* 1984;58:589-99.
- Çalışkan MK, Pehlivan Y, Sepetçioğlu F, et al. Root canal morphology of human permanent teeth in a Turkish population. *J Endod* 1995;21:200-4.
- Sert S, Bayirli GS. Evaluation of the root canal configurations of the mandibular and maxillary permanent teeth by gender in the Turkish population. *J Endod* 2004;30:391-8.
- Mauger MJ, Schindler WG, Walker III WA. An evaluation of canal morphology at different levels of root resection in mandibular incisors. *J Endod* 1998;24:607-9.
- Pineda F, Kuttler Y. Mesiodistal and buccolingual roentgenographic investigation of 7,275 root canals. *Oral Surg Oral Med Oral Pathol* 1972;33:101-10.
- Hession RW. Endodontic morphology: II. A radiographic analysis. *Oral Surg Oral Med Oral Pathol Oral Radiol* 1977;44:610-20.
- Gilles J, Reader A. An SEM investigation of the mesiolingual canal in human maxillary first and second molars. *Oral Surg Oral Med Oral Pathol* 1990;70:638-43.
- Alaçam T, Tinaz AC, Genç Ö, et al. Second mesiobuccal canal detection in maxillary first molars using microscopy and ultrasonics. *Austr Endod J* 2008;34:106-9.
- Versiani M, Pécora J, Sousa S, et al. The anatomy of two-rooted mandibular canines determined using microcomputed tomography. *Int Endod J* 2011;44:682-7.
- Versiani M, Pécora J, Sousa S, et al. The anatomy of two-rooted mandibular canines determined using microcomputed tomography. *Int Endod J* 2013;46:800-7.
- Neelakantan P, Subbarao C, Ahuja R, et al. Cone-beam computed tomography study of root and canal morphology of maxillary first and second molars in an Indian population. *J Endod* 2010;36(10):1622-7.
- Plotino G, Tocci L, Grande NM, et al. Symmetry of root and root canal morphology of maxillary and mandibular molars in a white population: a cone-beam computed tomography study in vivo. *J Endod* 2013;39:1545-8.
- Somalinga Amardeep N, Raghu S, Natanasabapathy V. Root canal morphology of permanent maxillary and mandibular canines in Indian population using cone beam computed tomography. *Anat Res Int* 2014;2014:1-7.
- Kayaoglu G, Peker I, Gumusok M, et al. Root and canal symmetry in the mandibular anterior teeth of patients attending a dental clinic: CBCT study. *Braz Oral Res* 2015;29:1-7.
- Zhengyan Y, Keke L, Fei W, et al. Cone-beam computed tomography study of the root and canal morphology of mandibular permanent anterior teeth in a Chongqing population. *Ther Clin Risk Manag* 2016;12:19-25.
- Soleymani A, Namaryan N, Moudi E, et al. Root canal morphology of mandibular canine in an Iranian population: A CBCT assessment. *Iran Endod J* 2017;12:78-82.
- Patel S, Dawood A, Ford TP, et al. The potential applications of cone beam computed tomography in the management of endodontic problems. *Int Endod J* 2007;40:818-30.
- Martins J, Ordinola Zapata R, Marques D, et al. Differences in root canal system configuration in human permanent teeth within different age groups. *Int Endod J* 2018;51:931-41.
- Ng YL, Aung T, Alavi A, et al. Root and canal morphology of Burmese maxillary molars. *Int Endod J* 2001;34:620-30.
- Cotton TP, Geisler TM, Holden DT, et al. Endodontic applications of cone-beam volumetric tomography. *J Endod* 2007;33:1121-32.
- Peikoff M, Trott J. An endodontic failure caused by an unusual anatomical anomaly. *J Endod* 1977;3:356-9.
- Altunsoy M, Ok E, Nur BG, et al. A cone-beam computed tomography study of the root canal morphology of anterior teeth in a Turkish population. *Eur J Dent* 2014;8:302.
- Pécora JD, Sousa Neto M, Saquy PC. Internal anatomy, direction and number of roots and size of human mandibular canines. *Braz dent J* 1993;4:53-7.
- Ouellet R. Mandibular permanent cuspids with two roots. *J Can Dent Assoc* 1995;61:159-61.
- Lin Z, Hu Q, Wang T, et al. Use of CBCT to investigate the root canal morphology of mandibular incisors. *Surg Radiol Anat* 2014;36:877-82.