

Not your “Typical Patient”: Cryptococcal meningitis in an immunocompetent adult

Emine Arman Firat¹, Zeynep Ture², Hafize Sav³, Ihami Celik¹

¹City Hospital of Kayseri, Department of Clinical Microbiology and Infectious Diseases, Kayseri, Turkey

²Erciyes University, Faculty of Medicine, Department of Clinical Microbiology and Infectious Diseases, Kayseri, Turkey

³City Hospital of Kayseri, Division of Mycology, Kayseri, Turkey

Copyright © 2019 by authors and Annals of Medical Research Publishing Inc.

Abstract

Cryptococcal meningitis is a very rare type of infection in healthy adults. Such patients may present with the symptoms of increased intracranial pressure. Rapid diagnosis of infection, rapid intervention to reduce intracranial pressure and appropriate antifungal therapy are important to reduce mortality. In here we report a case of cryptococcal meningitis infection. An immunocompetent patient presented to our clinic with the complaints of headache and dizziness for a month. The findings of the physical examination supported with meningitis. *Cryptococcus neoformans* growth was observed on blood and cerebrospinal fluid culture. Despite the appropriate antifungal therapy, patient died because of the delaying in the diagnosis.

Keywords: *Cryptococcus neoformans*; cryptococcal meningitis; meningitis; immunocompetent adult

INTRODUCTION

Infections of central nervous system caused by fungal pathogens, have become significantly more common over the past two decades (1). Cryptococcal infection is very rare and almost always found to occur in immunocompromised individuals such as the patients with Human Immunodeficiency Virus (HIV) infection, lymphoproliferative disorders, corticosteroid therapy, diabetes mellitus and organ transplantation (2). More than 100,000 people die because of the cryptococcal meningitis (CM) per year, mostly in sub-Saharan Africa, with a high prevalence of HIV infection (3). But there are few reported cases in which it has been found to cause CM even in immunocompetent individuals (4,5). In here we report a similar case of cryptococcal meningitis infection in an immunocompetent adult.

CASE REPORT

A 33-year-old male patient was admitted to the emergency department with the complains of headache and dizziness for the last 3 days. A month ago he was admitted to another hospital with the present complaints and a lumbar puncture had performed him because of the narrowing of

the visual field. It was learned that cerebrospinal fluid (CSF) opening pressure was 40 cm H₂O. CSF cell count and biochemistry results were compatible with meningitis. CSF glucose level was 62 mg/dl, protein level was 55 mg/dl and white blood cell (WBC) level was 15 / mm³. It was learned that an emergency ventriculoperitoneal shunt (VPS) was inserted, but further examination could not be performed because the patients refusing. The patient's complaints regressed after VPS operation.

On the second evaluation, he was generally asleep; bilateral pupillary dilated, nuchal rigidity, Kerning and Brudzinski tests were positive on the physical examination. Laboratory examination revealed leukocytosis. However other laboratory parameters were normal (Table 1) .

Lumbar puncture was performed because of the unsuccessful CSF sampling from the VPS. CSF opening pressure was measured as 50 cm H₂O. CSF WBC was 130/mm³. There was 80% of lymphocyte predominance. Tuberculous meningitis was considered primarily with these findings.

However; Polymorphic leukocytes and yeast cells were seen in CSF samples by gram stain (Figure 1). Liposomal

Received: 18.09.2019 Accepted: 20.11.2019 Available online: 10.01.2020

Corresponding Author: Zeynep Ture, Erciyes University, Faculty of Medicine, Department of Clinical Microbiology and Infectious Disease, Kayseri, Turkey E-mail: dr.zeynepture@gmail.com

amphotericin B and fluconazole treatments were started with the suspicion of CM.

Table 1. Laboratory results of the patient on admission and follow-up

	1.Day	3.Day	6.Day	8.Day	9.Day
WBC /mm ³	16.62	16.4	21.9	9.9	
AST/ALT (U/L)	26/22	15/38	15/62	24/17	21/15
Creatinine (mg/dl)	0,96	0,95	1.64	3.98	4.29
CRP	9.7	64.6	321	438	
CSF Biochemistry					
CSF protein mg /dl	41.65				
CSF glucose 5mg/dl	5				
CSF sodium	141				

WBC; White blood cell, AST; aspartate aminotransferase; ALT; Alanine Aminotransferase, CRP; C reactive protein; CSF; Cerebrospinal fluid

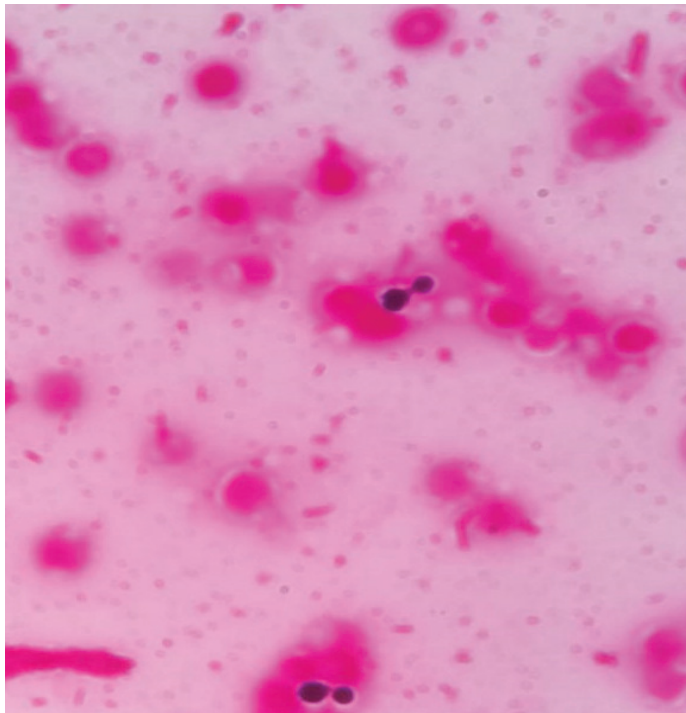


Figure 1. Polymorphonuclear leukocytes and Gram-positive stained yeast cells seen in Gram staining

The CSF samples also inoculated into Sheep-Blood, chocolate and Sabouraud dextrose agar. Weak growth was detected, and urea test was done. Normal yellow color of Christensen's urea agar turned to pink color (Figure 2). Direct examination by microscope was done with saline from the colony, and budding yeast cells were seen. Capsules of yeast cells were seen to be stained by Indian ink from the colony grew from CSF (Figure 3). Commercial definition was done with VITEK2 YST cards (bioMérieux,

France) and it was detected as *Cryptococcus neoformans* by the rate of 95%. Antifungal susceptibility was performed by E-test method. The minimum inhibitory concentration (MIC) values for amphotericin b, voriconazole, fluconazole amphotericin B were detected as 0.064 µg/ml, 3 µg/ml, 2 µg/ml, respectively.



Figure 2. Yellow color turned to pink color of Christensen's urea agar

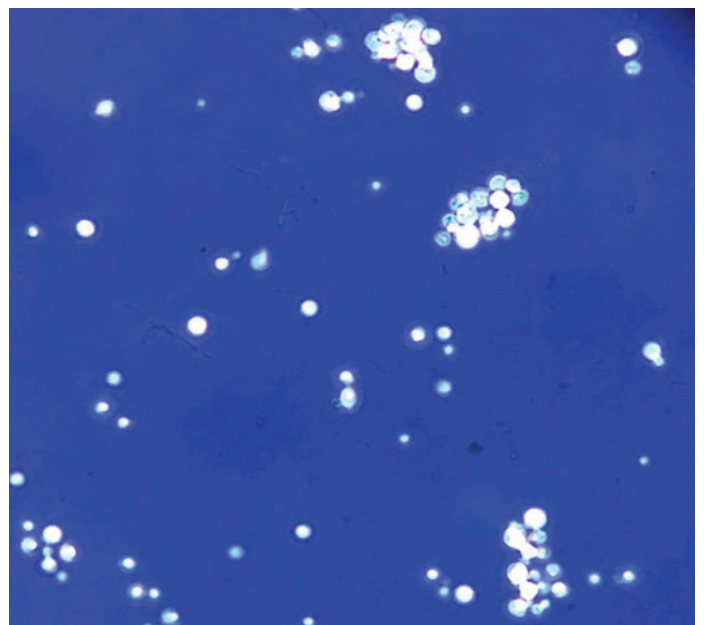


Figure 3. Capsules of yeast cells stained by Indian ink

The patient had no history of systemic disease, immunosuppressive drug using, hunting or pigeon feeding. The anti-HIV test that performed after admission was negative. On the second day of treatment, the patient had a seizure and Glasgow Coma Score was 10. VPS revision was performed due to brain edema findings after the control cranial tomography. There was a need for a post-op mechanical ventilator. *C. neoformans* growth was observed on the blood culture taken at the beginning of the treatment. The patient who needed mechanical ventilation and developed acute renal failure. Although the patient had elevated CRP within days, no signs of ventilator-associated pneumonia, bloodstream infection or shunt infection were observed. Current high CRP levels was evaluated as postoperative elevation. However; patient died due to multiorgan failure on the 7th day of antifungal therapy.

DISCUSSION

Elevated intracranial pressure (ICP) is one of the most common complications of CM. CSF pressure above 25 cm / H₂O is considered as elevated ICP. The mechanism of elevated ICP is primarily due to the physical obstruction by cryptococcal polysaccharide capsule and due to a failure of CSF resorption via the arachnoid villa (6). Increased ICP leads to increased mortality in patients with CM. Rolfes et al. (7) reported an increased survival by 69% with serial lumbar puncture in the cases of HIV-associated cryptococcal meningitis. VPS can be applied to prevent increasing of ICP. Baddley et al. (8) reported to low mortality rate with applying VPS to CM patients. In another study evaluating 23 non-HIV patients with CM, it was reported decreasing the ICP after VPS operation and faster improving the symptoms (9). In this case, VPS was implanted earlier. However, the patient died because of no further investigation for diagnosis and treatment.

The recommended treatment of CM for the induction therapy is high-dose amphotericin B and flucytosine. High-dose amphotericin B plus high-dose fluconazole is an alternative treatment protocol (10). We preferred to second protocol because of the absence of flucytosine in our country. High-dose fluconazole treatment was found to be successful in either single or combined use in the study which evaluated 44 non-HIV-infected patients (11). In the same study; one-year total mortality rate was found to be 14% in all treatment groups. In a study of 154 non-HIV-infected patients reported 30% one-year mortality (12). In our case, the time between the onset of symptoms to diagnosis and initiation of treatment was very long. During this period, the patient died because of the elevated ICP and its complications.

CONCLUSION

As a conclusion, CM is a very rare type of infection in healthy adults. Such patients may present with increased ICP symptoms. Rapid diagnosis of infection, rapid intervention to reduce intracranial pressure and appropriate antifungal therapy are important to reduce mortality.

Competing interests: The authors declare that they have no competing interest.

Financial Disclosure: There are no financial supports.

Ethical approval: This study was approved by the Institutional Ethics Committee and conducted in compliance with the ethical principles according to the Declaration of Helsinki.

Emine Arman Firat ORCID: 0000-0002-7950-9509

Zeynep Ture ORCID: 0000-0001-6895-0318

Hafize Sav ORCID: 0000-0001-8435-396X

Ilhami Celik ORCID: 0000-0002-2604-3776

REFERENCES

- Góral ska K, Blaszkowska J, Dzikowiec M. Neuroinfections caused by fungi. *Infection* 2018;46:443-59.
- Perfect J.R. Cryptococcosis (*Cryptococcus neoformans* and *Cryptococcus gattii*). In: Bennett JE, Dolin R, Blaser MJ, eds. *Mandell, Douglas, And Bennett's Principles And Practice Of Infectious Diseases*, Eighth Edition. Philadelphia 2015;2934-248.
- Rajasingham R, Smith RM, Park BJ, et al. Global burden of disease of HIV-associated cryptococcal meningitis: an updated analysis. *Lancet Infect Dis* 2017;17:873-81.
- Hamdan N, Billon Grand R, Moreau J. Cryptococcal meningitis in an immunocompetent patient with obstructive hydrocephalus: A case report. *Neurochirurgie* 2018;64:324-6.
- Barreiros C, Meireles-Brandão L, Silva D, et al. Cryptococcal Meningitis in a HIV-Negative Patient. *Eur J Case Rep Intern Med* 2018;5:000778.
- Ming DK, Harrison TS. Cryptococcal meningitis. *Br J Hosp Med (Lond)* 2017;78:125-7.
- Rolfes MA, Hullsiek KH, Rhein J, et al. The effect of therapeutic lumbar punctures on acute mortality from cryptococcal meningitis. *Clin Infect Dis* 2014; 59:1607-14.
- Baddley JW, Thompson GR, Riley KO, et al. Factors Associated With Ventriculoperitoneal Shunt Placement in Patients With Cryptococcal Meningitis. *Open Forum Infect Dis* 2019;6:241.
- Liu J, Chen ZL, Li M, et al. Ventriculoperitoneal shunts in non-HIV cryptococcal meningitis. *BMC Neurol* 2018;18:58.
- Abassi M, Boulware DR, Rhein J. Cryptococcal Meningitis: Diagnosis and Management Update. *Curr Trop Med Rep* 2015;2:90-9.
- Zhao HZ, Wang RY, Wang X, Jet al. High dose fluconazole in salvage therapy for HIV-uninfected cryptococcal meningitis. *BMC Infect Dis* 2018;18:643.
- Zhu LP, Wu JQ, Xu B, et al. Cryptococcal meningitis in non-HIV-infected patients in a Chinese tertiary care hospital, 1997–2007. *Med Mycol* 2010;48:570-9.