

# Hemisection: A modern endodontic approach as an alternative treatment for the extraction of molar teeth-case series

Oguz Tavsan, Hasan Ozturk, Neslihan Simsek

Inonu University, Faculty of Dentistry, Department of Endodontics, Malatya, Turkey

Copyright © 2020 by authors and Annals of Medical Research Publishing Inc.

## Abstract

Hemisection is the separation of the whole tooth from the mesial to distal in the upper molars and premolars and from the buccal to lingual in the lower molars, and removal of the pathological root together with the crown. Hemisection is an appropriate treatment option when caries, resorption, iatrogenic complication or periodontal damage is limited to one root and the other root is relatively healthy. Hemisection of the affected tooth helps to preserve alveolar bone which surrounding the tooth structure and supports fixed dentures. Therefore, when a molar tooth should be extracted only because of damage at one root, hemisection or root amputation treatment alternatives should be kept in mind. This case series describes hemisection as a successful treatment method to recover teeth with iatrogenic complications and irretrievable root caries were limited to single root.

**Keywords:** Hemisection; perforation; iatrogenic complication; endodontics

## INTRODUCTION

Modern advances in dentistry have enabled patients to maintain functional dentition for a lifetime. Therapeutic measures to ensure that teeth are retained in the mouth vary. The treatments applied may involve total or partial retention of the teeth as a result of endodontics, prosthetic dental treatment and periodontology cooperation (1). Treatment options for a molar tooth with an extremely irretrievable caries, resorption or iatrogenic complication are limited. The most common treatment for these types of teeth is the treatment of removable partial dentures, fixed dentures or implants. However, in selecting appropriate cases, hemisection can be a relatively simple, conservative and inexpensive treatment with good chance of success (2).

Hemisection and root resection have been identified as successful treatment methods today. Yuh et al. (3) stated that the mean survival rate of the molars with root resection was 91.1%. Carnevale et al. (4) reported a 93% survival rate in 10-year follow-up in patients received

hemisection for the treatment of molars with furcation problems. The success of hemisection depends largely on case selection and adherence to specific endodontic, surgical and restorative guidelines. It has been suggested that hemisection should be considered before the extraction of each molar because it shows long-term successful results (5).

## CASE REPORT

### Case 1

A 50-year-old male patient was admitted to Inonu University Faculty of Dentistry Department of Endodontics because of pain in his right lower region. In radiographic (Figure 1a) and clinical examination, tooth 46 was diagnosed with acute apical periodontitis. The patient did not have any systemic disease.

When the endodontic cavity of the tooth was opened, a filling material was observed on and around the mesial canals. When this filling material was removed, a large perforated area was detected in the intercanal region including mesial canal orifices. After determining the

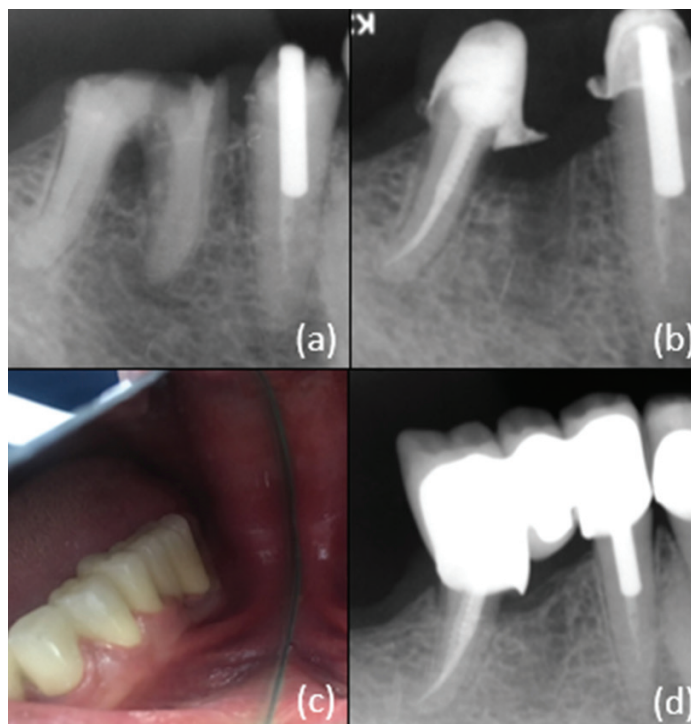
**Received:** 21.11.2019 **Accepted:** 11.12.2019 **Available online:** 18.02.2020

**Corresponding Author:** Oguz Tavsan, Inonu University, Faculty of Dentistry, Department of Endodontics, Malatya, Turkey

**E-mail:** tavsan.oguz@gmail.com

working length of the canals in the distal root, root canal shaping was completed with the ProTaper Universal (Dentsply Maillefer, Ballaigues, Switzerland) rotary file system. Irrigation was performed with 2 ml/min 3% NaOCl after the use of each file. The final irrigation before root canal filling was performed by applying 2 ml/min 3% NaOCl, 2 ml/min 17% EDTA and 2 ml/min 3% NaOCl and root canals were dried by using paper cones. Root canals were filled with cold lateral compaction method by using resin sealer (Dia-ProSeal, Diadent, Seoul, South Korea) and gutta percha. Then the prefabricated metal post was applied to the distal root. After the tooth was restored with a direct composite resin, the roots were separated from each other with a diamond flame shaped bur and the mesial root was extracted (Figure 1b). Following the complete recovery of the soft and hard tissue after the operation, the remaining distal part of the mandibular right first molar and the second premolar were prepared and restored with a metal supported fixed prosthesis (Figure 1c). No endodontic treatment was applied to tooth 45 depending on the patient's request.

After 18 months follow-up; it was observed that the tooth was clinically asymptomatic and that the extraction cavity of the root was completely healed (Figure 1d).



**Figure 1.** Case 1 (a) Diagnostic radiography of tooth 46 (b) Post-treatment radiography of tooth 46 (c) Metal supported fixed denture applied to tooth 46 (d) Figure 1d. 18 months follow-up radiograph of tooth 46

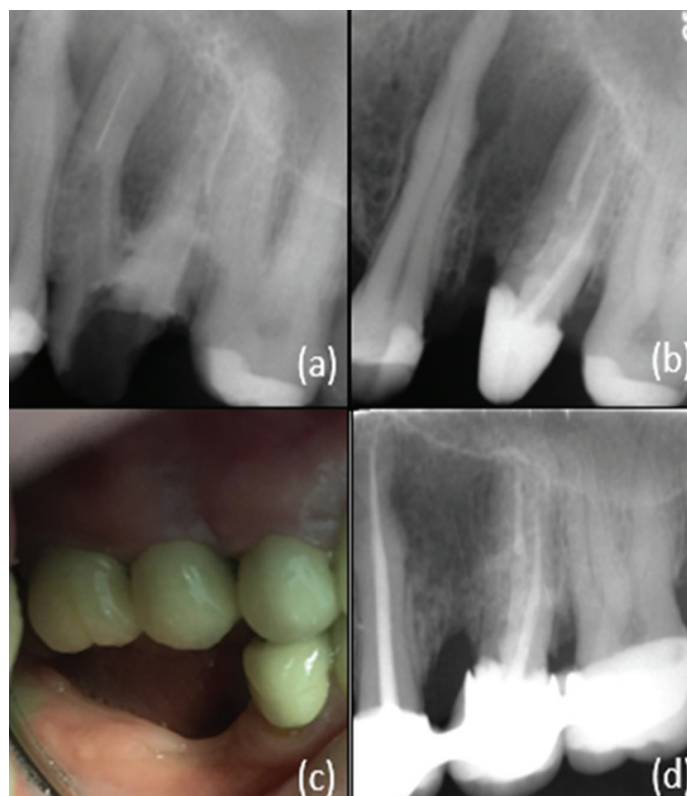
### Case 2

A 43-year-old male patient was admitted to our clinic with swelling and pain in his left upper region. Radiographic and clinical examination revealed swelling at the vestibular mucosa of tooth 26, pain at the percussion of the tooth, instrument fracture from the previous treatment in the

mesial root and a large lesion. The tooth was diagnosed with phoenix abscess. The patient did not have any systemic disease. The instrument on the mesial root could not be removed as a result of the techniques used (Figure 2a).

The mesial root was separated from the other roots with a diamond flame shaped bur and its extraction was performed. After determining the working length of the palatinal and distal root canals of the tooth, root canal shaping was completed with the ProTaper Universal (Dentsply Maillefer, Ballaigues, Switzerland) rotary file system. Irrigation was performed with 2 ml/min 3% NaOCl after the use of each file. The final irrigation before root canal filling was performed by applying 2 ml/min 3% NaOCl, 2 ml/min 17% EDTA and 2 ml/min 3% NaOCl and root canals were dried by using paper cones. Root canals were filled with cold lateral compaction method by using resin sealer (Dia-ProSeal, Diadent, Seoul, South Korea) and gutta percha. Fiber post (FGM, FGM Products Odontologicos Ltda, Joinville, Brazil) was placed in the palatinal root (Figure 2b). Following complete recovery of the soft and hard tissue after the operation, the left maxillary first premolar, second premolar, the remaining palatinal and distal portion of the first molar and the second molar were prepared and restored with a metal supported fixed prosthesis (Figure 2c).

After 12 months follow-up; it was observed that the tooth was clinically asymptomatic and that the extraction cavity of the root was completely healed (Figure 2d).



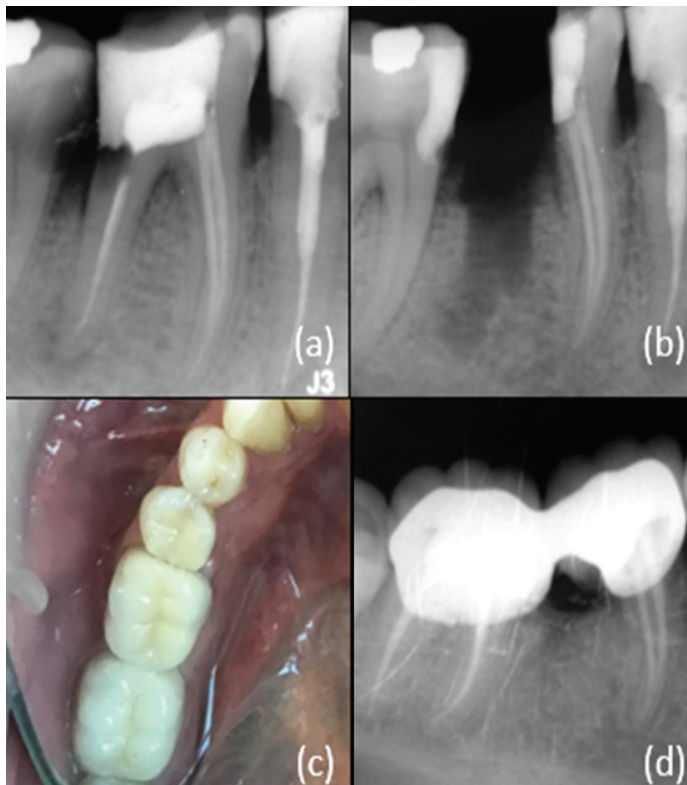
**Figure 2.** Case 2 (a) Diagnostic radiography of tooth 26 (b) Post-treatment radiography of tooth 26 (c) Metal supported fixed denture applied to tooth 26 (d) 12 months follow-up radiograph of tooth 26

### Case 3

A 45-year-old male patient was admitted to our clinic with complaint of food impaction in the mandibular right first molar. In the clinical examination, caries was found in the subgingival region at a depth of 4 mm. Radiographic examination revealed a large lesion in the apical of the distal root (Figure 3a). The tooth was diagnosed with chronic apical periodontitis. The patient did not have any systemic disease.

The tooth was cut with a diamond flame shaped bur in the buccal-lingual direction and the roots were divided into two parts, mesial and distal. After removal of the distal root (Figure 3b), the lesion was cured. Following the complete recovery of the soft and hard tissue after the operation, the remaining mesial part of the mandibular right first molar and the second molar were prepared and restored with a metal supported fixed prosthesis (Figure 3c).

After 12 months follow-up; it was observed that the tooth was clinically asymptomatic and that the extraction cavity of the root was completely healed (Figure 2d).



**Figure 3.** Case 3 (a) Diagnostic radiography of tooth 46 (b) Post-treatment radiography of tooth 46 (c) Metal supported fixed denture applied to tooth 46 (d) 12 months follow-up radiograph of tooth 46

## DISCUSSION

The loss of posterior teeth may cause some undesirable conditions, such as mesial drift, loss of arc length, and loss of chewing function. The clinician should decide on a treatment option based on the patient's age, medical history and ability to provide adequate oral hygiene (2).

In all cases presented, iatrogenic failures in previous treatments and irretrievable root caries were limited to single roots of the teeth, so patients were told about all treatment options including hemisection. The patients were also reluctant to lose their teeth.

Hemisection is a successful treatment method for multi-rooted teeth in order to protect the remaining healthy tooth tissue when there is a problem only in one root. There are various resection procedures such as root amputation, hemisection, radisection and bisection/bicuspidization (6).

The long-term success of hemisected molar teeth depends on several interrelated factors. Among these are: periodontal condition of the tooth, root anatomy, adequate oral hygiene, endodontic and restorative treatment and surgical procedures (2). Success is highly dependent on appropriate case selection. Before deciding to perform any resection procedure, it is important to consider the following factors (7);

- Hemisection treatment can be performed on multi-rooted teeth with severe bone loss around one root while there is an acceptable level of bone support around the remaining roots.
- Angle and position of the tooth in the arch; Hemisection cannot be performed on the buccal, lingual, mesial or distal angled molar teeth.
- Intertadicular distance; Hemisection of teeth with separated roots are easier. Hemisection is not preferred for teeth with very close or fused roots.
- Length and curvature of roots; Long and straight roots are more suitable for hemisection than short conical roots.
- There should be no contraindications for the endodontic and restorative treatment of the remaining roots or roots.

Hemisection was used as a treatment method in all three patients. Roots with iatrogenic complications of previous treatments and irretrievable root caries were resected.

Implant treatment is a predictable option with good function (8). However, patients preferred hemisection due to financial reasons and desire to keep their teeth in the mouth. Hemisection allows physiological tooth mobility of the remaining root. This is a more suitable abutment for fixed partial dentures than an osseointegrated implants (9). At the same time, most endodontic procedures result in minimal patient discomfort compared to implants and are performed with fewer complications. It has been observed that stereognostic ability is lower in implant treated patients than in patients with natural dentition (10). The smaller size of the occlusal tables, under-contouring of the embrasure spaces and ensuring that the crown margin encompasses the furcation are all factors in the high success rates observed with hemisection treatment (11).

The current follow-up period of the presented cases varies between 12-18 months. Unfortunately, the literature does not reveal consistent data on the long-term prognosis of root resection or hemisection. Basten et al. (12) reported



that 92% of all resected molars had an average survival of 12 years, and failure was due to recurrent caries or endodontic and strategic reasons. Likewise, high survival rates of resected molars have been reported by Hamp et al. (13). However, Erpenstein reported the negative results of molars treated with hemisection treatment with a general failure rate of 20.6% due to pathological apical factors (14).

## CONCLUSION

Hemisection success is similar to routine endodontic treatments provided that case selection has been made correctly, endodontic treatment has been performed appropriately, and restoration has been designed to be acceptable to the patient's occlusal and periodontal needs. Therefore, hemisection treatment can be offered as a suitable alternative to tooth extraction and implant treatment when evaluating treatment options with patients.

*Competing interests: The authors declare that they have no competing interest.*

*Financial Disclosure: There are no financial supports.*

*Oguz Tavsan ORCID: 0000-0001-8030-436X*

*Hasan Ozturk ORCID: 0000-0002-1891-0817*

*Neslihan Simsek ORCID: 0000-0003-1142-9016*

## REFERENCES

1. Basaraba N. Root amputation and tooth hemisection. *Dent Clin North Am* 1969;13:121-32.
2. Sharma S, Tewari RK, Mishra SK, et al. Conservative management of grossly carious mandibular first molar with a hemisection approach: A case report. *General Dentistry* 2015;63:19-21.
3. Yuh DY, Cheng GL, Chien WC, et al. Factors affecting treatment decisions and outcomes of root-resected molars: a nationwide study. *J Periodontol* 2013;84:1528-35.
4. Carnevale G, Di Febo G, Tonelli MP, et al. A retrospective analysis of the periodontal-prosthetic treatment of molars with interradicular lesions. *Int J Periodontics Restorative Dent* 1991;11:189-205.
5. DeSanctis M, Murphy KG. The role of resective periodontal surgery in the treatment of furcation defects. *Periodontology* 2000;22:154-68.
6. Weine FS. *Endodontic Therapy*. 5th ed 1996;154-68.
7. Behl AB. Hemisection of a Multirrooted Tooth-A Case Report. 2012;1:336.
8. Bashutski JD, Wang HL. Common implant esthetic complications. *Implant Dentistry* 2007;16:340-8.
9. Kost WJ, Stakiw JE. Root amputation and hemisection. *Journal* 1991;57:42-5.
10. Jacobs R, Bou Serhal C, van Steenberghe D. The stereognostic ability of natural dentitions versus implant-supported fixed prostheses or overdentures. *Clin Oral Investig* 1997;1:89-94.
11. Rapoport RH, Deep P. Traumatic hemisection and restoration of a maxillary first premolar: a case report. *General Dentistry* 2003;51:340-2.
12. Basten CH, Ammons WF, Jr Persson R. Long-term evaluation of root-resected molars: a retrospective study. *J Esthet Restor Dent* 1996;16:206-19.
13. Hamp SE, Nyman S, Lindhe J. Periodontal treatment of multirrooted teeth. Results after 5 years. *J Clin Periodontol* 1975;2:126-35.
14. Erpenstein H. A 3-year study of hemisectioned molars. *J Clin Periodontol* 1983;10:1-10.