

# Safe, easily applicable mini-laparotomic surgical steps in cornual ectopic pregnancy: Case report and demonstration of surgical technique

 Erhan Okuyan<sup>1</sup>,  Caglar Altundal<sup>1</sup>,  Zeynep Bayramoglu<sup>2</sup>

<sup>1</sup>Batman Maternity and Child's Health Hospital, Clinic of Gynecology and Obstetrics, Batman, Turkey

<sup>2</sup>Konya Education and Research Hospital, Clinic of Pathology, Konya, Turkey

Copyright © 2020 by authors and Annals of Medical Research Publishing Inc.

## Abstract

In the management of rare cornual ectopic pregnancy, there is no consensus on surgical treatment modalities in obstetric practice. In this article, we aimed to describe the safe and easily applicable minilaparotomic surgical steps with black pencil drawings. A 5-centimeter-size of Pfannenstiel incision was made to enter the abdomen with sterile covering under operating room conditions. After evaluating the topographic anatomy of the uterus and adnexa, a window was opened just below the ligamentum ovarii proprium and skeletonization of the cornual ectopic pregnancy was achieved. Then, ligamentum ovarii proprium was ligated and cut by using 1.0 vicryl and U sutures were placed in 3 planes after skeletalization of cornual ectopic pregnancy mass. After cornuotomy was performed and the pregnancy material was removed the uterine myometrium layer and serosa were closed separately with baseball stitches. Total operation time was 20 minutes, perioperative blood loss was recorded as 50 ccs/dl and the patient was discharged at 24<sup>th</sup> hour without any complications. With this surgical technique applied with minilaparotomic incision, fertility-preserving surgery can be performed in a short time without causing excessive blood loss or hysterectomy. Studies involving many cases are needed to prove perioperative and postoperative results of this surgical technique.

**Keywords:** Cornual ectopic pregnancy; demonstration of surgical technique; minilaparotomic cornuotomy

## INTRODUCTION

Ectopic pregnancy is a gestational sac located outside the endometrium and has high maternal morbidity and mortality (1). Cornual ectopic pregnancy is difficult to diagnose and may have serious complications for obstetricians. This condition is managed medically or surgically (hysteroscopy, laparoscopy, laparotomic cornual resection, and hysterectomy) (2). Risk factors for ectopic pregnancy are pelvic inflammatory disease, previous ectopic pregnancy, salpingectomy, and assisted reproductive techniques (3). Although the incidence is reported as 2-4% in literature it can be diagnosed by clinical suspicion and transvaginal ultrasound-guided examination. Diagnosis can be made by transvaginal ultrasonography in which no gestational sac is observed in the uterine cavity and gestational sac surrounded by myometrium layer of maximum 5 mm thickness at the level of uterine fundus tubal ostium (4). Currently, there is no definite consensus on medical management with methotrexate, minimally invasive approach with hysteroscopy or laparoscopy (5). In this study, we shared

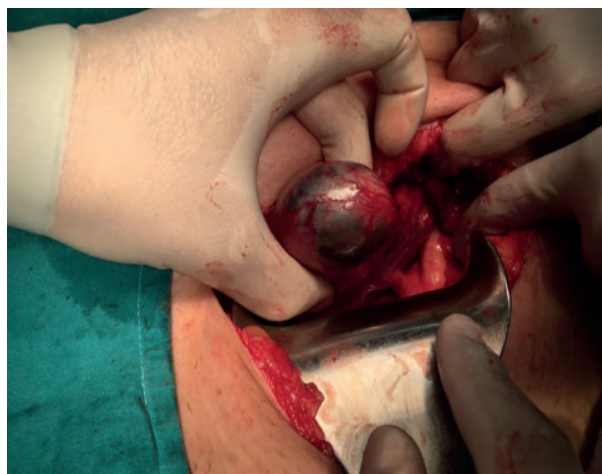a minilaparotomic cornuotomy procedure with both perioperative photographs and black pencil sketches.

## CASE REPORT

A 35-year-old woman with 4 normal births was admitted to our emergency department with active vaginal bleeding, dizziness and severe abdominal pain. In the vaginal examination of the patient, the cervix was observed to be multiparous, active red bleeding from the cervix was observed and the vagina was extremely sensitive during the examination. The patient was conscious. Her arterial blood pressure was 90/60 mmHg and pulse was 110 per minute. Transvaginal ultrasonography showed no gestational sac in the uterine cavity and a gestational sac in the coronal section at the level of the left tubal ostium compatible with 7 weeks and 3 days and 3 cm of heterogeneous echo fluid collection in Douglas were observed. In the anamnesis, it was found that the patient had a history of smoking (1 pack of cigarettes a day) and that she had received oral treatment 3 months ago due to widespread vaginal infection.

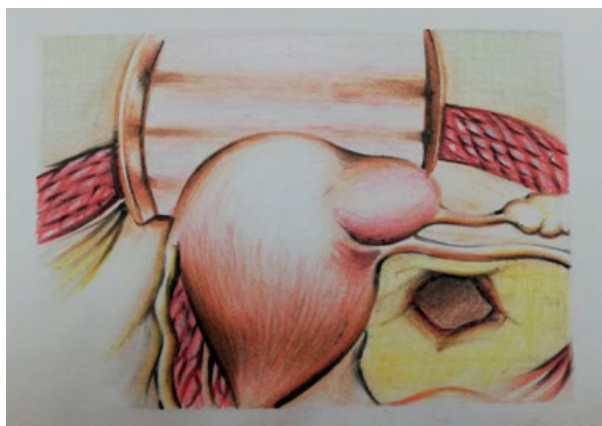
**Received:** 22.12.2019 **Accepted:** 06.03.2020 **Available online:** 22.06.2020

**Corresponding Author:** Erhan Okuyan, Batman Maternity and Child's Health Hospital, Clinic of Gynecology and Obstetrics, Batman, Turkey **E-mail:** dreo06@hotmail.com



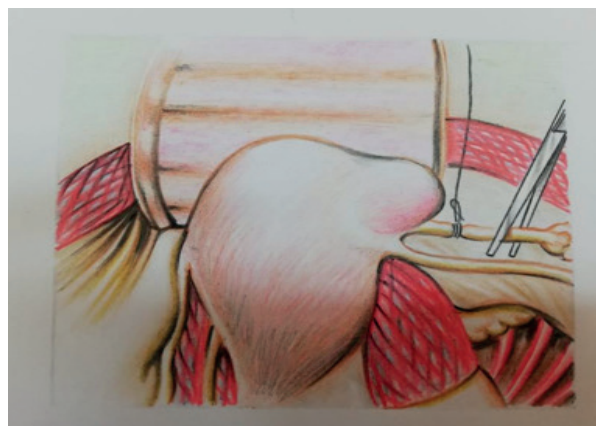
**Figure 1.** Left uterine cornual ectopic pregnancy

The results of transvaginal ultrasonography and physical examination were as follows: the  $\beta$ -hCG value was 9600, hemoglobin value was 9.2 mg/dl, hematocrit value was 26 and platelet count was 105 thousand. Therefore, the patient was diagnosed with cornual ectopic pregnancy so that blood and blood products were prepared. After the informed consent was obtained she was taken to the operating room. Abdominal entry was made with a 5 cm of Pfannenstiel incision. In the observation, the abdomen was filled with approximately 200 ccs of hemorrhagic fluid and aspirated. Cornual ectopic pregnancy with a size of 3.5\* 3 cm was observed in the left cornual region (Figure 1). After intra-abdominal exploration and the right adnexal area check, a window was opened just below the left ligamentum ovarii proprium (Figure 2).

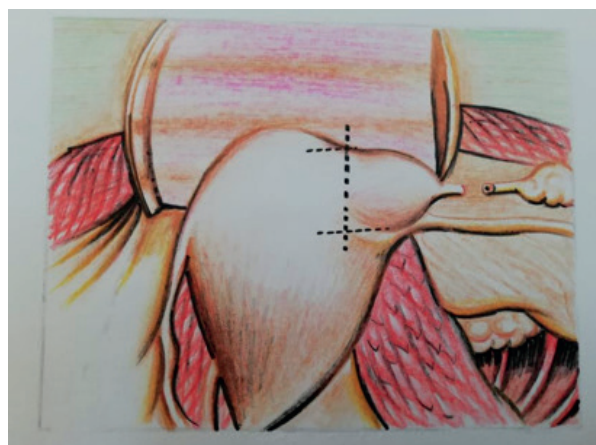


**Figure 2.** Opening window in the ligamentum latum

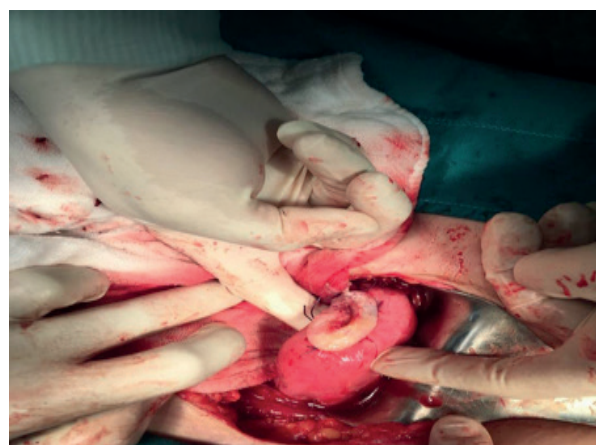
Subsequently, the ligamentum latum was skeletonized from the borderline of the cornual ectopic pregnancy with sharp dissection. After determining the cornual ectopic pregnancy limits clearly, the left ligamentum ovarii was cut and ligated with 1.0 vicryl (Figure 3). Following this step, 3 U sutures were ligated with 1.0 vicryl along the borders of the anterior, transverse and oblique sections of the cornual ectopic pregnancy (Figure 4).



**Figure 3.** Ligation of ligamentum ovarii proprium



**Figure 4.** U sutures placed with vertical, transverse and oblique planes before cornuotomy



**Figure 5.** Uterine serosa and myometrium layer after removal of pregnancy material

After the blood supply of cornual ectopic pregnancy was minimized, the pregnancy and its attachments were evacuated by vertical incision. After the gestational sac moved away from the operation site, uterine myometrium and the serosa layer were detected without blood loss and bleeding control was started (Figure 5).

After careful bleeding control, the uterine myometrium and the serosa layer were closed with baseball stitches using 2.0 vicryl. Perioperative blood loss was recorded as 50 ccs. No complications were observed in the perioperative period and the suture lines were re-checked and parietal peritoneum, fascia, and skin were closed. Duration of the operation from skin to skin was 20 minutes and the postoperative firsthour hemoglobin value was 9.0 mg/dl. Postoperatively, 1 unit of erythrocyte suspension and 1 unit of fresh frozen plasma transfusion were performed and the patient was discharged at 24th postoperative hour without any complication. In the control examination performed 1 week after the surgical procedure, serum  $\beta$ -hCG value was negative and no pathological findings were found.

## DISCUSSION

Cornual ectopic pregnancy is one of the most worrying diagnoses for obstetricians and its early diagnosis is very important to prevent catastrophic events. In one study, the rate of detection of cornual ectopic pregnancy by ultrasonography was reported to be 71% (6). Early diagnosis is very important to manage the condition with conservative treatment (7). In recent years, the trend towards laparoscopy has been increasing due to the increasing technology and interest in minimally invasive gynecological procedures, cosmetic reasons, patients' desire, less hospitalization, less pain, and less bleeding (8). When literature is reviewed, it is seen that cornual ectopic pregnancy cases are managed by laparoscopy (cornuotomy, cornual resection). It has also been observed that surgeons with laparoscopic surgical skills are in multidisciplinary centers (9). As in any surgical case, the management of cornual ectopic pregnancy depends on multiple factors. These factors include the desire to preserve the fertility of the patient, the status of the hemodynamic parameters, the history of previous pelvic surgery, the surgeon's experience in laparoscopy, the patient's health literacy rate, and the availability of blood and blood products. The case should be managed by taking all these factors into consideration. Whether a minimally invasive technique or laparotomy is chosen, the basic logic in the management of cornual ectopic pregnancy is to establish strategies to prevent excessive bleeding and the risk of recurrence. Multiple studies have shown that the anastomoses of the ascending branch of the uterine artery are connected (10-12). We thought that we needed an alternative minimally invasive surgical approach for the management of cornual ectopic pregnancy as there was a lack of experienced surgeons for laparoscopic management and we were a secondary health care provider. In this case, we performed the surgical steps, the operation from skin-to-skin lasted 20 minutes, perioperative blood loss was recorded as 50 ccs, and our patient's desire for fertility was maintained without the need for hysterectomy thanks to our suture technique. Based on our technique, the question lies in how we can maintain the desire for fertility without

performing a hysterectomy and without causing excessive blood loss. In literature, it is known that a minilaparotomic approach is used as an effective and safe method for benign gynecologic procedures (13). Although there are publications comparing minilaparotomy and laparoscopy in benign gynecologic operations, studies comparing the early and late postoperative results of many cases are still needed (14,15).

## CONCLUSION

Cornual ectopic pregnancy is one of the fearful dreams of obstetricians as it may have catastrophic consequences and there is no consensus on its management. Multiple factors such as hemodynamic parameters of the patient, the surgeon's abilities, access to blood and blood products, fertility preservation and cosmetic reasons are effective in the management of these cases.

Minilaparotomic cornuotomy is an alternative, simple and effective method. Studies including the comparison of early and late complications of large case series are needed to determine the efficacy and safety of this surgical technique.

*\*\*\*The pencil drawings were designed by Erhan Okuyan and drawn by Hamit Can the art teacher. Approval and permission of Hamit Can was obtained for publication.*

*Competing interests: The authors declare that they have no competing interest.*

*Financial Disclosure: There are no financial supports.*

## REFERENCES

- Balsak D, Inal M, Yildirim Y, et al. Successful Treatment of Unruptured Cornual Pregnancy Using Intravenous Methotrexate: A Case Report. *Turgut Özal Tıp Merkezi Dergisi* 2007;14:1.
- Yoong W, Neophytou C, de Silva L, et al. Novel laparoscopic cornual resection of interstitial pregnancy using the Endo GIA™ Universal Stapler (Medtronic): A series of 12 cases. *Aust N Z J Obstet Gynaecol* 2019.
- Egger E. Recurrent Interstitial Pregnancy: a Review of the Literature. *Geburtshilfe Frauenheilkd* 2017 ;77:335-9.
- Jurkovic D, Mavrellos D. Catch me if you scan: ultrasound diagnosis of ectopic pregnancy. *Ultrasound Obstet Gynecol* 2007;30:1-7.
- Moawad NS, Mahajan ST, Moniz MH, et al. Current diagnosis and treatment of interstitial pregnancy. *Am J Obstet Gynecol* 2010;202:15-29.
- Morgana M, Aziza M, Mikhaila M, et al. Ultrasound-guided treatment of cornual ectopic pregnancy. *Ultrasound Obstet Gynecol* 2003;25:272-5.
- Grindler NM, Ng J, Tocce K, et al. Considerations for management of interstitial ectopic pregnancies: Two case reports. *J Med Case Rep* 2016;10:106.
- Ng S, Hamontri S, Chua I, et al. Laparoscopic management of 53 cases of cornual ectopic pregnancy. *Fertil Steril* 2009;92:448-52.

9. Watanabe T, Watanabe Z, Watanabe T, et al. Laparoscopic cornuotomy for interstitial pregnancy and postoperative course. *J Obstet Gynaecol Res* 2014;40:1983-8.
10. Gezer A, Mutlu H. Laparoscopic management of cornual pregnancy without sutures. *Arch Gynecol Obstet* 2004;270:194-6.
11. Pasic RP, Hammons G, Gardner JS, et al. Laparoscopic treatment of cornual heterotopic pregnancy. *J Am Assoc Gynecol Laparosc* 2002;9:372-5.
12. Dagar M, Srivastava M, Ganguli I, Bhardwaj P, Sharma N, Chawla D. Interstitial and Cornual Ectopic Pregnancy: Conservative Surgical and Medical Management. *J Obstet Gynaecol India*. 2018 Dec;68(6):471-476. DOI: 10.1007/s13224-017-1078-0. Epub 2017 Nov 28. PMID: 30416274; PMCID: PMC6207538..
13. Kumar A, Pearl M. Mini-laparotomy versus laparoscopy for gynecologic conditions. *J Minim Invasive Gynecol* 2014;21:109-14.
14. Kucukozkan T, Ozkaya E, Ucar FO, et al. Hysterectomy for large symptomatic myomas: mini-laparotomy versus midline vertical incision. *Arch Gynecol Obstet* 2011;284:421-5.
15. Bhave Chittawar P, Franik S, Pouwer AW, et al. Minimally invasive surgical techniques versus open myomectomy for uterine fibroids. *Cochrane Database Syst Rev* 2014;CD004638.