

Evaluation of the demographic and clinical findings of pediatric patients that developed acute graft-versus-host disease after allogeneic hematopoietic stem cell

 Mavise Yuksel¹,  Yontem Yaman²,  Murat Elli²

¹Department of Dermatology, Istanbul Medipol University, Istanbul, Turkey

²Department of Pediatric Health and Diseases, Division of Hematology, Istanbul Medipol University, Istanbul, Turkey

Copyright © 2020 by authors and Annals of Medical Research Publishing Inc.

Abstract

Aim: Acute graft-versus-host disease (GVHD) is a complication after allogeneic hematopoietic stem cell transplantation (allo-HSCT), manifesting with an erythematous maculopapular rash followed by liver disease and dysfunctions of the gastrointestinal tract. This study aimed to retrospectively investigate the demographic and clinical characteristics of pediatric patients diagnosed with acute GVHD after undergoing allo-HSCT due to various hematological diseases.

Material and Methods: The study included 33 pediatric patients that underwent their first allogeneic bone marrow transplantation in the Pediatric Bone Marrow Transplant Unit between 2015 and 2018 and were consecutively diagnosed with acute GVHD in consultation with the department of dermatology. The demographic characteristics, clinical findings, donor characteristics, treatments, and survival status of each patient were recorded.

Results: Between 2015 and 2018, bone marrow transplantation was performed in 150 pediatric patients, of whom 33 (22%) developed acute GVHD. Of the 33 pediatric patients, 19 (57.6%) were boys and 14 (42.4%) were girls. At the time of transplantation, the mean age of the patients was 8.5 years, and the median age was 7 years. Twenty patients (60.6%) had only skin GVHD while 13 (39.4%) had skin and gastrointestinal and/or hepatic GVHD. It was found that the rashes had appeared on average 27.4 days after allo-HSCT. Palmoplantar involvement was detected in 13 patients (39.4%), painful erosion in the oral mucosa in 11 (33%), and conjunctivitis in seven (21.2%). The factors of being a male patient, being a female donor, transplantation from unrelated donors, liver involvement, and palmoplantar involvement were found to create risk of mortality, but not significantly (respectively $p=0,753$; $p=0,145$, $0,66$). Five patients (15%) progressed from acute to chronic GVHD. In patients that progressed from acute to chronic had, the mean donor age was higher, the mean time from transplantation to rash was longer, and oral involvement was higher, but not significantly (respectively; $p=0,596$; $p=0,980$; $p=0,193$).

Conclusion: In acute GVHD, the skin is the first and most involved organ; therefore, dermatologists play an important role in its diagnosis. This study is important for determining the factors affecting the decrease in progression to chronic GVHD and prolonging survival.

Keywords: Acute graft-versus-host disease; demographics; hematopoietic stem cell transplantation; pediatrics; survival

INTRODUCTION

Graft-versus-host disease (GVHD) is the main cause of non-recurrence-related morbidity and mortality and affects 40-60% of patients after allogeneic hematopoietic stem cell transplantation (allo-HSCT), resulting in mortality in 15% (1). The National Institutes of Health Consensus study group divided GVHD into four main groups: a) classic acute GVHD with an onset within 100 days of allo-HSCT, b) persistent/recurrent acute GVHD with the presence of acute GVHD findings 100 days after allo-HSCT, c) classic chronic GVHD presenting with classic GVHD findings without acute GVHD findings at any time

following allo-HSCT, and d) overlap syndrome in which the clinical features of chronic and acute GVHD coexist (2).

Cutaneous findings are among the most common and earliest findings of the disease (3). Acute GVHD usually begins with itchy and painful erythematous maculopapular rashes on the palms, soles, ear lobes, cheeks, neck, and upper trunk two to eight weeks after allo-HSCT. These rashes are then combined to form large patches and plaques. In more advanced cases, generalized erythema and bullae may occur. The GVHD of the gastrointestinal tract often presents with abdominal pain, nausea, vomiting, paralytic ileus, and high-volume diarrhea while hepatic

Received: 01.06.2020 Accepted: 21.08.2020 Available online: 18.09.2020

Corresponding Author: Mavise Yuksel, Department of Dermatology, Istanbul Medipol University, Istanbul, Turkey

E-mail: mavisey107@gmail.com

GVHD manifests with abdominal pain and elevated liver and bilirubin levels (4,5). The diagnosis of acute GVHD is based on clinical findings in patients that underwent allo-HSCT. A skin or gastrointestinal system biopsy can exclude possible causes, such as drug eruption and infection and confirm the diagnosis (6).

This study aimed to retrospectively investigate the demographic and clinical characteristics of pediatric patients diagnosed with acute GVHD after undergoing allo-HSCT due to various hematological diseases.

MATERIAL and METHODS

The study included 33 pediatric cases that underwent allo-HSCT due to malignant or non-malignant hematological diseases in the Pediatric Hematology Bone Marrow Transplant Unit between 2015 and 2018 and were histopathologically diagnosed with acute GVHD. For each patient, gender, age at the time of transplantation, date of transplantation, primary disease, donor type, donor age, donor gender, donor compliance, time between transplantation and skin rash, preparation regimen, GVHD prophylaxis, and steroid response were recorded. Acute GvHD grading was performed for all patients according to the Consensus Grading System criteria (7). The steroid response to the treatment was evaluated seven to 14 days after steroid onset. A complete response to steroid was evaluated as a complete regression of acute GVHD symptoms in all organs, a partial response was considered as an improvement in the degree of acute GVHD in all involved organs without complete regression, and non-response as the lack of any change in acute GVHD symptoms, progression of the disease, or mortality (8).

The study was conducted in accordance with the principles of the Helsinki Declaration.

Statistical analysis

The data were collected by the relevant clinical physician, transferred to Microsoft Excel program, edited and cleaned, and made suitable for statistical analysis. The Mann-Whitney U, Spearman's correlation and chi-square tests were used in analyses. The Kaplan-Meier survival method was used for the analysis of survival. Data analysis was performed using IBM Statistical Package for Social Sciences v. 25.0. A p value of 0.005 was accepted as statistically significant.

RESULTS

Between 2015 and 2018, bone marrow transplantation was performed in 150 pediatric patients, of whom 33 (22%) developed acute GVHD. A total of 33 pediatric patients, 19 males (57.6%) and 14 females (42.4%) were included in the study. At the time of transplantation, the mean age of the patients was 8.5 years, and the median age was 7 years. Twenty patients (60.6%) had only skin GVHD while 13 (39.4%) had skin and gastrointestinal and/or hepatic GVHD (Figure 1). It was recorded that the maculopapular rash had started on the body on average 27.4 days after allo-HSCT. Palmoplantar involvement was detected in 13 patients (39.4%), painful erosion

in the oral mucosa in 11 (33%), and conjunctivitis in seven (21.2%). The demographic findings and clinical characteristics of the patients are summarized in Table 1. The primary disease was acute lymphocytic leukemia in 15 cases (45.5%). The primary diseases of the patients that underwent transplantation are summarized in Table 2. There was no significant relationship between the time from transplantation to the onset of an acute GVHD rash and patient age and gender, histological grading, clinical grading, donor type, donor gender, preparation regimen, and the protocol used in prophylaxis. Five patients (15%) progressed from acute to chronic GVHD. In these patients, the mean donor age was higher (34.4 years), the mean patient age was higher (9.6 years), and the duration of rash after allo-HSCT was longer (30,2days compared to those that did not develop chronic form of the disease (27 years, 8.3 years, and 26,9 days, respectively), but there was no statistically significant difference between the two groups (Table 3). The rate of conversion to chronic GvHD was higher in patients with oral involvement (27.3%) compared those without oral involvement (9.1%), but this was not statistically significant ($p=0,193$).

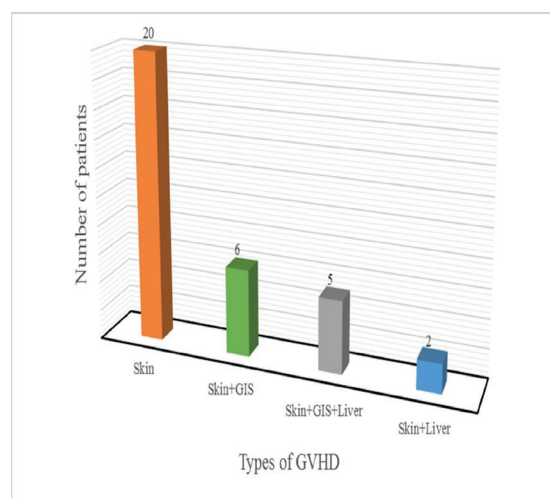


Figure 1. Number of patients according to the type of acute graft-versus-host disease

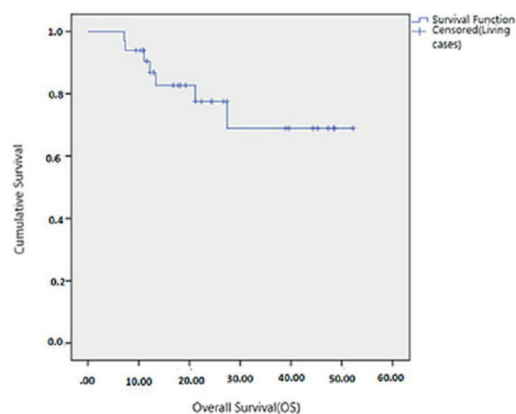


Figure 2. The overall survival of the patients

Table 1. Characteristics of the patients, donors, and transplantation

Variable	N (%)
Gender	
Male	19 (57.6%)
Female	14 (42.4%)
Donor gender	
Male	17 (51.5%)
Female	16 (48.5%)
Skin GvHD	
Stage 1	-
Stage 2	11 (33.3%)
Stage 3	11 (33.3%)
Stage 4	11 (33.3%)
Donor type	
Haploidentical	3 (9.1%)
Matched sibling	9 (27.3%)
Matched Unrelated	21 (63.6%)
Histological grade	
Grade 1	1 (3%)
Grade 2	30 (90.9%)
Grade 3	1 (3%)
Grade 4	1(3%)
Clinical grade	
Grade 1	7 (21.2%)
Grade 2	12 (36.4%)
Grade 3	3 (9.1%)
Grade 4	11 (33.3%)
Preparation regime	
Myeloablative	31 (93.9%)
Non-Myeloablative	2 (6.1%)
Development of chronic GVHD	
No	28 (84.8%)
Yes	5(15.2%)
Year of transplantation	
2015	6 (18.2%)
2016	4 (12.1%)
2017	10 (30.3%)
2018	13 (39.4%)
System involvement	
Skin	20 (60.6%)
Skin+gastrointestinal system	6 (18.2%)
Skin+gastrointestinal system+liver	5 (15.2%)
Skin+liver	2 (6.1%)
Recipient-donor gender	
Female-Female	7 (21.2%)
Female-Male	7 (21.2%)
Male-Male	10 (30.3%)
Male-Female	9 (27.3%)

The rate of conversion to chronic GvHD was also higher in male patients than in female patients without statistical significance (21.0% and 7.1%, respectively). The male patient-female donor constituted the group that had the highest rate (22%) of conversion to the chronic form of the disease. Approximately 94% of the patients received a myeloablative regimen while cyclosporine and short-term methotrexate were used in all patients as the preparation regimen. After the development of acute GvHD, the response to steroids was complete in 15 patients (45.5%) while partial or no response was observed in 18 cases (5.5%) (Table 2). The median follow-up period was 24.3 months, for which the survival rate was calculated as 78.8%. The mean overall survival was 41.2 months (Figure 2). In this study, male patient-female donor, transplantation from unrelated donors, liver involvement, and palmoplantar involvement were found to be risk factors in terms of mortality, but none of these parameters was statistically significant.

Table 2. Primary disease, acute treatment and GvHD prophylaxis distribution

Variable	N (%)
Primary disease	
All	15 (45.5%)
Thalassemia major	7 (21.3%)
Acute myeloid leukemia	5 (15.1%)
Fanconi aplastic anemia	3 (9.1%)
Sickle cell anemia	1 (3%)
Mucopolysaccharidosis type 1 Hurley	1 (3%)
Leukocyte adhesion deficiency type III	1 (3%)
Acute treatment	
Systemic Steroid	33(100%)
Mesenchymal stem cell transplantation	12 (36.4%)
Photopheresis	8 (24.2%)
Etanercept	6 (18.2%)
Mycophenolate mofetil	5 (15.2%)
Basiliximab	2 (6.1%)
Ruxolitinib	1 (3%)
Tacrolimus	1 (3%)
Steroid response	
Complete response to steroids	15 (45.5%)
Partial response to steroids	11(33.3%)
Unresponsive to steroids	7 (21.2%)
GVHD prophylaxis	
Cyclosporine	33 (100%)
Methotrexate	33 (100%)
Anti-thymocyte globulin	2 (6%)

Table 3. Results of difference tests between cases with and without chronic GvHD cases [Mean (N) ± standard deviation]

Variable	Chronic GvHD absent	Chronic GvHD present	Total	p
Age (at time of transplantation)	8.37 (28) ± 5.97	9.6 (5) ± 2.61	8.56 (33) ± 5.58	0.596
Time from transplantation to rash (days)	26.96 (28) ± 15.53	30.2 (5) ± 18.97	27.45 (33) ± 15.81	0.980
Mortality (years)	1.64 (28) ± 1.08	2.4 (5) ± 1.14	1.76 (33) ± 1.1	0.122
Donor age*	27.07 (28) ± 13.98	34.4 (5) ± 9.81	28.18 (33) ± 13.56	0.272

Mann-Whitney U test; *t-test

DISCUSSION

Acute GVHD occurs following graft infusion due to the activation of donor T cells against MHC class II antigens in the recipient cells and the resulting cytokine release. T cells originating from transplanted stem cells undergo tolerance induction in the thymus. In this process, reactive T cells that recognize and proliferate antigen-presenting cells are deleted. Since the thymus is not as functional in adults as in children, the deletion of self-reactive T cells cannot be performed efficiently; thus, GVHD is generally more common in children than adults and requires longer treatment (9). Pediatric acute GVHD presents with more isolated skin involvement and less liver and multiorgan involvement compared to adult cases (3).

The major risk factor for acute GVHD is human leukocyte antigen incompatibility. Gender differences between the recipient and the donor, the intensity of the preparation regimen, advanced age, multiparous female donors, and insufficiency of GVHD prophylaxis also play a role (10). In their study including 346 patients that underwent allo-HSCT and developed acute GVHD, Lee et al. reported that young age, unrelated donor, and acute leukemia posed increased risk for acute GVHD compared to other hematologic malignancies (11).

Sanli et al. conducted a study with 67 adult transplantation patients (bone marrow in 32 and peripheral blood stem cell in 35). Of the 67 patients, 49 were diagnosed with GVHD, and skin lesions began to appear on average 30.4 days after transplantation. Chronic GVHD developed in 63% of these patients (12). In our study, chronic GVHD developed in five patients (15.2%), of whom three had lichen planus-like clinical type chronic GVHD and two only presented with oral ulcers.

Oral involvement in acute GVHD has been rarely reported. Clinically, it is seen as widespread erosions of the oral mucosa or pseudomembranous ulceration. In a study of 2,578 adult allo-HSCT patients, oral mucosal involvement was observed in only 21 patients and was more frequently associated with grade 3 and 4 GVHD (13). In our study, oral involvement was detected in 11 patients with acute GVHD (33%). The clinical presentation was in the form of painful erosions in the oral mucosa in all patients. Compared to that found in the literature, the mortality rate (27.3%) was higher in patients with oral involvement than

those without oral involvement (18.2%), but the difference was not statistically significant.

It is known that the prognosis is poor when conjunctivitis occurs in the course of acute GVHD (14). In our study, the frequency of conjunctival involvement was higher in patients that died compared to those that survived, but this was not statistically significant (23% and 14.3%, respectively).

Although the rate of chronic GVHD in children (20-50%) is lower than that in adults (60-70%), its frequency is increasing due to the recent use of peripheral blood stem cells and unrelated donors. The known risk factors for chronic GVHD include the presence of acute GVHD, non-related donor, use of peripheral blood stem cells as the donor source, male recipient-female donor, and elderly recipient-elderly donor (15). In the current study, chronic GVHD developed in five patients (15%). In accordance with the literature, male recipient-female donor, advanced age, and unrelated donor were found to be risk factors for the development of chronic GVHD.

Today, a combination of prophylactic drugs to prevent GVHD is considered essential in patients receiving allogeneic hematopoietic stem cells in many healthcare centers. Cyclosporine, methotrexate, and calcineurin inhibitors are used in GVHD prophylaxis. The most common combination used in GVHD prophylaxis is cyclosporine and short-term methotrexate, which has been shown to improve survival to a greater degree than their individual use (10,16). Most centers also use cytokine-based agents, such as anti-thymocyte globulin that neutralize tissue damage leading to acute GVHD (17).

Despite the rapid development in the treatment of acute GVHD in recent years, steroids are still the first and optimal choice. As the first line of treatment, topical steroid or topical tacrolimus is used in grade 1 GVHD and systemic steroids (1-3 mg/ kg/da) in grades 2 to 4. In general, 40-50% of patients fully respond to systemic corticosteroids. The progression of the disease within three to five days after systemic steroid treatment or partial response after seven to 14 days indicates treatment failure, and requires switching to second-line therapy, in which these agents can be used in combination with corticosteroids or as monotherapy. The second-line treatment options include extracorporeal photopheresis, anti-inflammatory agents, such as etanercept, interleukin-2 receptor antagonists,

mesenchymal stem cell therapy, and tyrosinkinase inhibitors, such as ruxolitinip and imatinib (18,19).

Faraci et al. evaluated 197 pediatric patients diagnosed with acute GVHD between 2000 and 2009 over a median follow-up of 3.34 years. Eighteen percent of the patients were unresponsive to standard-dose first-line steroid treatment. The authors reported the overall survival rate to be 72% (8). In our study, the median follow-up time was 24.3 months, and 21.2% of the patients were unresponsive to standard-dose first-line steroid treatment. The median survival rate was 78.8%.

CONCLUSION

Hematologists, dermatologists, and gastroenterologists are important stakeholders in the multidisciplinary approach to the diagnosis and management of acute GVHD. Although in this study, there were not a sufficient number of patients to reach definitive results, this research is considered to be important because it shows the demographic distribution, risk factors, and survival analysis of acute GVHD cases in our center.

Competing interests: The authors declare that they have no competing interest.

Financial Disclosure: There are no financial supports.

Ethical approval: This study was approved by the Institutional Ethics Committee and conducted in compliance with the ethical principles according to the Declaration of Helsinki. This retrospective study was approved by the ethics committee of Istanbul Medipol Mega University Hospital (number: 10840098-604.01.01-E.53541, date: 30.09.2019).

REFERENCES

- Sung AD, Chao NJ. Acute graft-versus-host disease: Are we close to bringing the bench to the bedside? *Best Pract Res Clin Haematol* 2013;26:285-92.
- Filipovich AH, Weisdorf D, Pavletic S, et al. National Institutes of Health consensus development project on criteria for clinical trials in chronic graft-versus-host disease: I. Diagnosis and staging working group report. *Biol Blood Marrow Transplant* 2005;11:945-56.
- MacMillan ML, Holtan SG, Rashidi A, et al. Pediatric acute GVHD: clinical phenotype and response to upfront steroids. *Bone Marrow Transplant* 2019;55:165-71.
- Johnson MR, Farmer ER. Graft-versus-host reactions in dermatology. *J Am Acad Dermatol* 1998;38:369-92.
- Couriel D, Caldera H, Champlin R, et al. Acute graft-versus-host disease: pathophysiology, clinical manifestations, and management. *Cancer* 2004;101:1936-46.
- Ramachandran V, Kolli SS, Strowd LC. Review of graft-versus-host disease. *Dermatol Clin* 2019;37:569-82.
- Przepiorka D, Weisdorf D, Martin P, et al. 1994 consensus conference on Acute GVHD grading. *Bone Marrow Transplant* 1995;15:825-8.
- Faraci M, Giardino S, Bagnasco F, et al. Allogeneic hematopoietic stem cell transplantation in congenital disorders: A single-center experience. *Pediatr Transplant* 2017;21.
- Goddard DS, Horn BN, McCalmont TH, et al. Clinical update on graft-versus-host disease in children. *Semin Cutan Med Surg* 2010;29:92-105.
- Aladag E, Kelkitli E, Goker H. Acute graft versus host disease: A brief review. *Turk J Haematol* 2019.
- Lee SE, Cho BS, Kim JH, et al. Risk and prognostic factors for acute GVHD based on NIH consensus criteria. *Bone Marrow Transplant* 2013;48:587-92.
- Sanli H, Ekmekçi P, Arat M, et al. Clinical manifestations of cutaneous graft-versus-host disease after allogeneic haematopoietic cell transplantation: Long-term follow-up results in a single Turkish centre. *Acta Derm Venereol* 2004;84:296-301.
- Ion D, Stevenson K, Woo SB, et al. Characterization of oral involvement in acute graft-versus-host disease. *Biol Blood Marrow Transplant* 2014;20:1717-21.
- Saito T, Shinagawa K, Takenaka K, et al. Ocular manifestation of acute graft-versus-host disease after allogeneic peripheral blood stem cell transplantation. *Int J Hematol* 2002;75:332-4.
- Baird K, Cooke K, Schultz KR. Chronic graft versus host disease (GVHD) in children. *Pediatr Clin North Am* 2010;57:297-322.
- Svennilson J, Remberger M, Ringdén O. Risk factors for moderate-to-severe acute graft-vs.-host disease after allogeneic stem cell transplantation in children. *Pediatr Transplant* 2003;7:130-6.
- Harris AC, Ferrara JL, Levine JE. Advances in predicting acute GVHD. *Br J Haematol* 2013;160:288-302.
- Hu SW, Cotliar J. Acute graft-versus-host disease following hematopoietic stem-cell transplantation. *Dermatol Ther* 2011;24:411-23.
- Carreras E, Dufour C, Mohty M, et al. (2019), *The EBMT handbook hematopoietic stem cell transplantation and cellular therapies*. Switzerland: Springer.