

Surgical complications after pediatric kidney transplantation; Single center experience

 Gokalp Okut¹,  Gulec Mert Dogan²,  Sait Murat Dogan³

¹Department of Gastrointestinal Surgery, Faculty of Medicine, Turgut Ozal Medical Center, Inonu University, Malatya, Turkey

²Clinic of Pediatric Radiology, Malatya Research and Training Hospital, Malatya, Turkey

³Department of General Surgery, Faculty of Medicine, Turgut Ozal Medical Center, Inonu University, Malatya, Turkey

Copyright@Author(s) - Available online at www.annalsmedres.org

Content of this journal is licensed under a Creative Commons Attribution-NonCommercial 4.0 International License.



Abstract

Aim: Kidney transplantation is the most effective treatment for end stage renal disease in all age groups. In this study, we analyzed our surgical complications after pediatric kidney transplantation.

Materials and Methods: The data of pediatric patients who underwent kidney transplantation in our center between April 2009 and April 2019 were retrospectively analyzed. We divided the complications of the patients requiring secondary surgery into two groups as early and late according to their appearance in the first week and after. Wound problems, local or systemic infections, incisional hernias were not included in the surgical complication group.

Results: Among the 27 pediatric kidney transplant procedures performed in our center, there were 11 surgical complications (6% early and 5 late complications) (40%). 4 of the complications in the early transplant period were due to bleeding, 1 was due to the torsion of the vascular structures belonging to the graft, and 1 was due to lymphocele development. Three of the late complications were ureteral stenosis, and two were due to vesicoureteral reflux to the transplant kidney. In our study group, there was no patient loss due to transplantation. Graft loss was not related to surgical complication in any patient.

Conclusion: Pediatric kidney transplantation is a procedure that can be safely performed in our center, by looking at our patient and graft survival results and low surgical complications. Immediate identification and treatment of any complications are critical to the graft and patient survival.

Keywords: Complication; outcome; pediatric renal transplantation

INTRODUCTION

Kidney transplant (KT) is the most appropriate treatment for adult and pediatric patients with end-stage renal disease. Obstacles to transplantation in pediatric patients with end-stage renal disease (ESRD) include frequent hospitalizations, psychosocial effects of dialysis, immature immune system, and difficult donor matching for body size (1). Despite advances in surgical techniques and immunosuppressive regimens, surgical complications; It continues to be an important clinical problem that increases morbidity rates, length of hospital stay and costs. Some of these complications can be life-threatening, and early diagnosis can save both the patient and the graft. At the end of uncomplicated processes, pediatric patients can achieve normal growth and development with an optimum and controlled immunosuppressive treatment plan after transplantation (2). In this study, we analyzed our surgical complications after pediatric KT.

MATERIALS and METHODS

In the retrospective analysis of pediatric KT patients followed up in our clinic between April 2009 and April 2019, follow-up data were collected until May 2020. Demographic (gender, age of recipient at transplantation) and clinical data (end stage renal failure etiology, previous RRT type, donor type, length of hospital stay, follow-up time after KT, creatinine values, graft loss and death), complications (perioperative and postoperative surgical complications, those occurring in the first seven days were considered as early and others as late) were analyzed. Delayed graft function (DGF) was defined as the need for dialysis in the first week after transplantation. The cases considered for rejection were included in the analysis. Graft loss was defined as the need for permanent dialysis. A descriptive statistical analysis was performed. Categorical variables were presented as frequency and

Received: 28.11.2020 **Accepted:** 31.12.2020 **Available online:** 21.09.2021

Corresponding Author: Gokalp Okut, Department of Gastrointestinal Surgery, Faculty of Medicine, Turgut Ozal Medical Center, Inonu University, Malatya, Turkey **E-mail:** gokalp.okut@gmail.com

percentage. All statistical analyzes were performed using SPSS software version 17 for Windows (SPSS Inc., Chicago, IL, USA). For the retrospective study, approval was obtained from the ethics committee.

Standard surgical techniques are used in our center. In our series, retroperitoneal transplantation was performed in all our patients. We use monofilament non-absorbable sutures with 7-0 for renal arteries and 6-0 for veins. We use continuous suture technique with 6-0 Polydioxanone sutures (PDS) for ureteral anastomoses. In addition, we place a double J catheter during ureter anastomosis. We remove this catheter 4 weeks after the transplantation, as long as there are no adverse situations. All our recipients used trimethoprim / sulfamethoxazole for 6 months after transplant. All recipients received tacrolimus-based triple regimen (steroids, mycophenolic acid in addition). Induction therapy was used in all patient.

Wound problems, local or systemic infections, incisional hernias were not included in the surgical complication group.

RESULTS

Since 2009, 27 pediatric KT procedures have been performed in our center. 12 of our patients were women and 15 were men. Mean age of KT was 12.36 ± 4.18 years (range 4-17 years). The most common cause of end-stage renal disease was vesicoureteral reflux (VUR). Twenty-two patients were on peritoneal dialysis and 4 patients on hemodialysis. A patient with chronic kidney disease due to Alport syndrome was transplanted preemptively. Average dialysis duration was 29 (3-104) months. Eighteen (66.7%) of the transplanted kidneys came from cadaver donors and 9 (33.3%) from living donors. All operations were performed by the same surgical team. All demographic and clinical data were obtained by retrospective scanning of patient files. In 27 pediatric KT, 11 patients (40%) had complications requiring surgery. Six complications were evaluated as early and 5 as late complications (Figure 1). Four of the complications in the early transplant period were due to bleeding, 1 was due to torsion of the vascular structures of the graft, and 1 was due to lymphocele development. In only 1 of the cases requiring re-operation due to bleeding, bleeding from vascular origin was detected. The bleeding area in the renal artery was sutured. In the other 3 patients, the reason for bleeding was from the retroperitoneal surgical site. After clearing the hematoma, the areas with leakage were treated with local interventions. While the intervention time was first 24 hours in 3 of the patients, surgery was performed on the 5th day in our other patient because of the cessation of active bleeding due to hematoma compression. In the lymphocele case, surgical drainage was applied due to the pressure on the vascular structures. There was no recurrence of lymphocele and no additional intervention was required. In another patient, an exploration decision was made due to decreased renal artery flow in the ultrasonography performed upon the development of GGF. On exploration, it was found that the flow in the graft

kidney was disrupted due to torsion, and the flow was patent with intraoperative Doppler ultrasonography after repositioning. Three of the late complications were due to ureteral stricture and two of them were due to vesicoureteral reflux to the transplant kidney. The etiology of ESRD in patients operated for VUR was neurogenic bladder and ureterovesical stenosis. For the treatment of VUR, both patients were initially injected with a subureteric volume-enhancing agent with endoscopic technique to increase the resistance in the ureteral orifice, while success was achieved in one patient, ureteroneocystostomy was performed in our other patient at the 4th year after transplantation. Ureteroneocystostomy was performed in revision operations in 3 patients who were operated due to ureter stenosis. Revision times were 3 months after transplantation in 2 patients, and 37 months in our other patient.

The mean lowest creatinine value in all patients was 0.68 ± 0.21 mg/dl, the mean lowest creatinine value was 0.69 ± 0.21 mg/dl in patients with complications requiring surgery, and the mean lowest creatinine value in patients with graft loss after surgical complications was 0.68 ± 0.07 mg/dl. The mean end creatinine value of patients without complication was 1.14 ± 0.74 mg/dl. The mean end creatinine value of the patients who did not have graft loss despite having complications that required surgery was 1.35 ± 1.20 mg/dl.

GGF was seen in three of our patients with early complications. There was graft loss in four patients (34%) during the 10-year follow-up. The etiology of graft loss was chronic allograft nephropathy in all 4 patients. There was no transplantation-related mortality in our study group. Graft loss was not related to surgical complications in any patient.

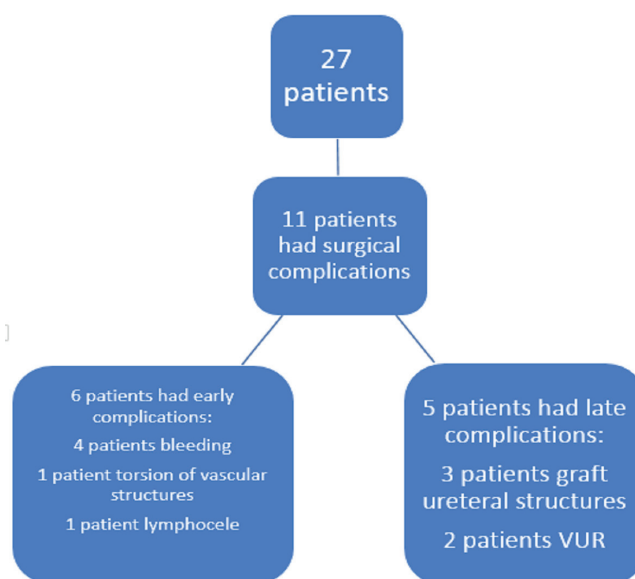


Figure 1. Flow chart of the study

DISCUSSION

KT is the best option for the treatment of end stage renal failure in the pediatric patient group. The success rate has been higher in recent years due to improvements in immunosuppressive regimens and improvements in operative techniques. As surgical experience increases, safer techniques have been adopted to reduce complications in many centers. In this context, renal graft survival is closely related not only to immunosuppression and donor and patient selection protocols, but also to surgical complications and their treatment.

Since the emergence of KT as the optimal treatment of end-stage renal disease, vascular thrombosis and transplant renal artery stenosis are well-known complications in pediatric patients (3). The incidence of vascular complications is variable depending on various factors such as the clinical status of the donor and recipient, prophylactic heparinization strategy, and immunosuppressive therapy (4). In our study, the incidence of vascular complications was 18%. This value appears to be slightly higher than in the literature, where the incidence does not exceed 6% (5). According to the literature, the high incidence can be associated with the low body weight of our patient group. In patients with low body weight, the vascular diameter is correspondingly smaller, which makes the anastomosis technically difficult.

Renal artery stenosis is one of the complications that can lead to graft loss after KT. Its incidence is between 1% and 23% in the literature, and it often presents with medical treatment-resistant hypertension and progressive allograft dysfunction. Traumatization of the renal artery (especially due to damage to the intima during perfusion of the kidney with a cannula), artery torsion due to positional or long graft artery, vascular type rejection, and atherosclerosis in the recipient or donor artery are the main causes. New onset or worsening of hypertension should be suspected, usually with increased proteinuria and / or plasma creatinine levels. The diagnosis of transplant renal artery stenosis has been facilitated by recent radiological developments and its prevalence has increased. (7). Wong reported that the prevalence of 2.4% before the use of routine Doppler ultrasound was 12.4% after the use of Doppler (8). Treatment consists of balloon revision or endovascular stent placement and surgical revision or percutaneous transluminal angiography. In our series, a patient who developed GGF was explored, considering that there might be a stenosis due to thrombosis due to the decrease in renal artery flow as a result of USG, but it was seen that the cause of the decreased flow was vascular torsion, in the patient who did not require intervention to the vascular structures, patent arterial flow was achieved by repositioning the graft.

Graft vein thrombosis is a serious vascular complication. It usually manifests in the first few days after the transplant, but it can also occur later. It is more common in living donor transplantation. It is less common in men than in women, and more common in adults than children (9). Mechanical

causes (hematoma or lymphocele and compression of the renal vein), narrow venous anastomosis or renal vein plication are the most common causes. Early severe vascular rejection and hereditary coagulopathies are other possible contributing factors (10). Investigation of hemostatic pathologies is mandatory to look for predisposing factors, especially in vascular thrombosis that cannot be associated with surgical technique. We did not encounter any renal vein thrombosis problem in our series, because we tried to keep the graft renal vein length as short as possible in order not to impair position-related flow during renal vein anastomosis. Vascular complications in childhood KT are mainly reported in kidneys taken from cadaver donors (11). However, other studies have revealed that vascular complications are evenly distributed between living or cadaveric donor transplants. Unfortunately, the number of patients in our classroom is too low to gather information on this subject.

Urological complications can be a real threat to graft and patient survival. In the literature, urinary leakage and ureteral stenosis have a particularly significant mortality rate. Ureteral obstruction may occur early or late postoperatively, the ureteral fistula usually tends to appear immediately after transplantation. In our study, none of the patients died due to urological complications, and when compared with the literature (urinary leakage 2.5% - ureteral stenosis 25%), we obtained very good results (0% - 11%) (12). Failure to preserve ureter vascularization during donor surgery and faulty technical practices in transplantation increase urological complications. In addition, immunosuppressive drugs and rejections also cause stricture secondary stenosis in the late period.

Although it is aimed to reduce urological complications with more rigorous surgery and low-dose steroid protocols, this rate tends to increase due to the elderly donors who have been used with expanded donor criteria in recent years and their weak ureteral vascularization (13). Our urological complication rates after pediatric KT are similar to other series in the literature. In our practice, we aim to prevent complications by being careful about protecting the vascularization of the graft ureter. At the same time, we aim to prevent early leakages and ureter trace disorders by not pulling the double J catheter for about 4 weeks in the posttransplant period.

Lymphocele, a surgical complication of KT, represents an extraperitoneal lymph accumulation created by cutting lymphatic vessels and is best avoided by meticulous lymphatic ligation during recipient vascular dissections. It shows an incidence of 1% to 26% (14). Lymphocele is often asymptomatic. However, localized symptoms such as leakage or swelling from the incision line or postrenal acute kidney failure may present. Septic complications due to lymphocele are rarely seen. We did not see any major complications related to lymphocele. We bind the lymphatics in the area close to the vascular during the preparation process of the recipient retroperitoneal area for transplantation. We think that this technique is important in terms of preventing lymphatic leakage. Surgical

drainage was performed in 1 patient with lymphocele and compression findings; the lymphocele did not recur and the patient did not need any further intervention.

CONCLUSION

In recent years, with advances in surgical technique and increasing experience, successful results similar to adults have been obtained in pediatric KT. Complications can be reduced with careful transplantation techniques and current immunosuppressive treatment regimens. Early diagnosis is very important for both graft and patient survival in the management of complications.

Competing Interests: The authors declare that they have no competing interest.

Financial Disclosure: There are no financial supports.

Ethical Approval: The approval for the study was obtained from the NonInterventional Clinical Research Ethics Committee of Inonu University Institute of Health Sciences (2020/932).

REFERENCES

1. Verghese PS. Pediatric kidney transplantation: a historical review. *Pediatr Res* 2017;81:259-64.
2. Dalgic A, Boyvat F, Karakayali H, et al. Urologic complications in 1523 renal transplantations: The Baskent University experience. *Transplant Proc* 2006;38:543-47.
3. Sinha R, Saad A, Marks SD. Prevalence and complications of chronic kidney disease in paediatric renal transplantation: a K/DOQI perspective. *Nephrol Dial Transplant* 2010;25:1313-20.
4. El Atat R, Derouiche A, Guellouz S, et al. Surgical complications in pediatric and adolescent renal transplantation. *Saudi J Kidney Dis Transpl* 2010;21:251-7.
5. Osman Y, Shokeir A, Ali-El-Dein B, et al. Vascular Complications After Live Donor Renal Transplantation: Study of Risk Factors and Effects on Graft and Patient Survival. *J Urol* 2003;169:859-62.
6. Gargah T, Abidi K, Rajhi H, et al. Vascular complications after pediatric kidney transplantation. *Tunis Med* 2011;89:458-61.
7. Fervenza FC, Lafayette RA, Alfrey EJ, et al. Renal artery stenosis in kidney transplants. *Am J Kidney Dis* 1998;31:142-8.
8. Ponticelli C, Moia M, Montagnino G. Renal allograft thrombosis. *Nephrol Dial Transplant* 2009;24:1388-93.
9. Taher A, Zhu B, Ma S, et al. Intra-abdominal Complications After Pediatric Kidney Transplantation: Incidence and Risk Factors. *Transplantation* 2019;103:1234-9.
10. Fathi T, Samhan M, Gawish A, et al. Renal allograft venous thrombosis is salvageable. *Transplant Proc* 2007;39:1120-1.
11. Roach JP, Bock ME, Goebel J. Pediatric kidney transplantation. *Semin Pediatr Surg* 2017;26:233-40.
12. Sheldon CA, Churchill BM, Khoury AE, et al. Complications of surgical significance in pediatric renal transplantation. *J Pediatr Surg* 2001;4:485-9.
13. Dawidek MT, Aquil S, Alogaili R, et al. Renal Lymphangiectasia in the Transplanted Kidney: Case Series and Literature Review. *Transplantation* 2020;104:172-5.
14. Zietek Z, Sulikowski T, Tejchman K, et al. Lymphocele after kidney transplantation. *Transplant Proc* 2007;39:2744-7.