

Determining the effects of Hyperoside as a protective agent against to testicular damage

 Fazile Nur Ekinçi Akdemir¹,  Ayhan Tanyeli²,  Mustafa Can Guler²,  Ersen Eraslan³

¹Department of Nutrition and Dietetics, High School of Health, Agri, Turkey

²Department of Physiology, Faculty of Medicine, Ataturk University, Erzurum, Turkey

³Department of Physiology, Faculty of Medicine, Bozok University, Yozgat, Turkey

Copyright@Author(s) - Available online at www.annalsmedres.org

Content of this journal is licensed under a Creative Commons Attribution-NonCommercial 4.0 International License.



Abstract

Aim: The aim of this study is to evaluate the possible beneficial effects of hyperoside (HYP) in the mitigation of torsion detorsion (TD)-induced testicular oxidative damage.

Materials and Methods: For this purpose, Wistar Albino rats were grouped (n=6 in each group) as sham, TD and TD+HYP groups. HYP was administered at 50 mg/kg dose p.o for 1 week. Torsion was created by twisting the spermatic cord clockwise by 720 degrees. The detorsion model was made by restoring the spermatic cord. Tissue oxidative and antioxidative stress parameters were measured according to biochemical methods to evaluate oxidative damage in testis.

Results: In particular, the oxidative stress parameters we measured were found to be significantly increased compared to the sham group in TD group depending on the TD model, but showed a significant decrease depending on the HYP treatment (p<0.05). In addition, it was observed that the antioxidative parameters decreased significantly in the TD group, while this decrease effectively changed in the TD+HYP group.

Conclusion: Considering the current results, HYP therapy is thought to be useful in alleviating TD-induced oxidative damage in the testicles.

Keywords: Hyperoside; testis; torsion detorsion; oxidative stress

INTRODUCTION

Hyperoside (quercetin-3-O-galactoside), a flavonoid compound isolated from *Hypericum perforatum* L. (1), has various biological activities in its efficacy against oxidative stress by increasing its anti-apoptotic, anti-ischemic, anti-inflammatory properties and antioxidative enzyme activity (2-4). In the studies conducted to date have been reported to be highly effective against ischemia reperfusion (IR)-induced myocardial injury (5). In another study, it was revealed to be preventive of the Hyperoside against oxidative damage caused by hydrogen peroxide on lung fibroblast cells (6). It is also said to be an effective therapeutic agent of hyperoside on liver damage caused by IR (4) (Figure 1).

Testicular torsion is the deterioration of testicular blood flow as a result of rotating around their axis the spermatic cord structures. If left untreated in the early period, necrosis develops in the testicular tissue and it can cause subfertility and infertility. Therefore, it is important to re-supply of blood flow of testicular tissue it as soon as possible.

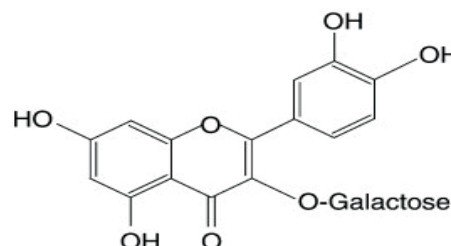


Figure 1. The chemical structure of Hyperoside (quercetin-3-O-galactoside) (6)

Especially, testicular torsion detorsion (TD) seen more during late childhood or early adolescent the period (7-9). Testicular TD results with ischemia reperfusion. In fact, the first stage of testicular injury begins in the ischemic period and reaches a critical level in the reperfusion period. Reasons of this critical period include lipid peroxidation, intracellular intensive Ca^{2+} release, overproduction of reactive oxygen species (ROS), metabolic acidosis, recruitment of neutrophil and acute oxidative and inflammatory responses leading to serious

Received: 08.05.2020 Accepted: 26.05.2020 Available online: 18.05.2021

Corresponding Author: Fazile Nur Ekinçi Akdemir, Department of Nutrition and Dietetics, High School of Health, Agri, Turkey

E-mail: fazilenur85@gmail.com

tissue damage (10-12). In fact, under physiological conditions, intracellular antioxidant system modulates ROS. However, due to increased ROS thanks to ischemia/reperfusion (I/R), the capacity of the antioxidant defense system to neutralize ROS remains insufficient; therefore, an imbalance occurs between the produced ROS and the antioxidant defense system, which causes serious cellular damage (13,14).

When the studies in the literature are investigated, it is seen that there are many studies evaluating the testicular damage caused by torsion detorsion. However, there is not study evaluating the effectiveness of hyperoside therapy in alleviating testicular torsion detorsion damage has been encountered. Therefore, the aim of this study is to evaluate the possible beneficial effects of hyperoside in the mitigation of testicular torsion detorsion-induced testicular damage.

MATERIALS and METHODS

The study was carried out with ethical consent from the Atatürk University Animal Experiments Local Ethics committee (Protocol number and date: 200/07.11.2019). Wistar Albino type male rats were kept in international standard laboratory conditions (continuously controlled 55 % humidity, average room temperature and dark/light 12h;12h cycle). These standard conditions were provided by Atatürk University Animal Experiments Research and Application Center (ATADEM). Rats were provided with standard pellet feed and tap water until 12 hours before the experiment. HYP (98%) and sodium carboxymethyl cellulose (CMC) were obtained from Sigma Aldrich USA. Xylazine and Ketamine (Ketalar 50 mg/ml) was supplied from Rompun BAYER Istanbul, Turkey and from Pfizer Medicines Limited Company, Istanbul, Turkey.

Experimental Process and Groups

After all experimental animals were weighed (210±5 g), they were distributed randomly in sham, TD and TD+HYP groups. In the group designated as sham, the scrotum was opened with an incisional incision and closed again by suturing. TD model, which was established in TD and TD+HYP groups, was made by twisting the spermatic cord clockwise 720 degrees for 2 hours and restoring it for 2h. For the scrotal incision, rats were anesthetized with ketamine/xylazine (50/10 mg/kg), a midline scrotal incision was made under aseptic condition. The TD model we applied was made according to the method used in previous studies (12,15,16). HYP was prepared fresh daily by dissolving in 1% CMC. HYP treatment was applied at a dose of 50 mg/kg p.o for one week. HYP final dose was applied 30 minutes before detorsion. In order to prevent animal loss due to drug toxicity, the dose of HYP and anesthesia were selected from previous studies (4, 17). Upon completion of the TD procedure, the rats were sacrificed by applying high-dose anesthesia, the testicular tissues were taken, washed, and kept under appropriate conditions (-80 °C) until biochemical measurements were made.

Biochemical Measurements

Testis tissues were weighed for 100 mg and homogenized with 2 mL of phosphate buffer. Homogenized tissues were centrifuged at 5000 rpm for 20 minutes at +4°C and the supernatant was transferred to eppendorf tubes and maintained at -80°C. The MDA, as a result of lipid peroxidation, was measured according to previous MDA analysis method (18). SOD and MPO activities were analysed in accordance with the methods described by Sun et al. and Bradley et al. (19,20). TAS and TOS measurements were performed with commercially available kits (Rel Assay Diagnostics). The ratio of TOS to TAS was accepted as the OSI. OSI value was calculated as follows: $OSI = [(TOS, \mu\text{mol/L}) / (TAS, \text{mmol/L}) \times 10]$. We used OSI as another indicator of oxidative stress. OSI has been suggested that it may reflect the state of oxidative status more accurately than TOS (21,22).

Statistical Analysis

One-way analysis of variance (ANOVA) and Duncan tests were performed for the biochemical data of this study. The results are presented in a table and presented as Mean ± SEM. p value was accepted as statistically significant at 0.05 level.

RESULTS

In this study, the evaluation of TAS, TOS, OSI values, MDA level, SOD and MPO activity results are very important in terms of revealing TD-induced oxidative stress in testicular tissue. As a result of biochemical evaluations of testis tissues, TOS, OSI values, MDA level and MPO activities increased significantly in TD group compared to sham group. However, these results decreased in TD+HYP group compared to TD group (see Table 1 and 2, p<0.05). Our antioxidant results are valuable in explaining whether oxidative stress can be alleviated. In this respect, while SOD activity and TAS value decreased in TD group, it was determined that it was significantly supported in TD+HYP treatment group (see Table 1 and 2, p<0.05).

Table 1. Total Antioxidant Status (TAS) (mmol/L), Total Oxidant Status (TOS) (μmol/L) and Oxidative Stress Index (OSI) values in testicular tissue of all groups

	TAS (mmol/L)	TOS (μmol/L)	OSI
Sham (n=6)			
Mean	1.83*	7.06*	0.41*
Std. Deviation	0.11	0.95	0.07
Maximum	1.99	8.45	0.50
Minimum	1.71	6.04	0.30
TD (n=6)			
Mean	0.80***	13.01***	1.65***
Std. Deviation	0.13	0.41	0.26
Maximum	0.98	13.49	2.10
Minimum	0.63	12.49	1.40
TD+HYP (n=6)			
Mean	1.59**	7.19**	0.48**
Std. Deviation	0.33	0.57	0.13
Maximum	1.89	8.07	0.70
Minimum	0.96	6.57	0.30

*** The statistical significance between the same letters in the columns is at 0.05 level

Table 2. Malondialdehyde (MDA) ($\mu\text{mol}/\text{gr}$ tissue) level, (Superoxide Dismutase (SOD) (U/mg protein) and Myeloperoxidase (MPO) (U/g protein) activities in testicular tissue of all groups

	MDA ($\mu\text{mol}/\text{gr}$ tissue)	SOD (U/mg protein)	MPO (U/mg protein)
Sham (n=6)	193.95*	438.05*	38737.54*
Mean	12.59	37.56	3368.01
Std. Deviation	211.26	480.85	43892.82
Maximum	176.87	394.15	35478.97
Minimum			
TD (n=6)			
Mean	459.01***	189.00***	98447.14***
Std. Deviation	31.28	14.77	8781.96
Maximum	491.87	211.69	113274.20
Minimum	404.3	174.20	89032.27
TD+HYP (n=6)			
Mean	202.06**	413.49**	41390.82**
Std. Deviation	11.87	29.63	3620.60
Maximum	222.49	459.47	45518.79
Minimum	190.76	384.33	37325.15

*** The statistical significance between the same letters in the columns is at 0.05 level

DISCUSSION

Testicular torsion, which is encountered in the clinic, is one of the important urological urgent cases, lead to sudden and severe scrotal pain and requiring immediate diagnosis and surgical treatment (9,15). If this ischemic condition lasts for more than a few hours, it may lead to irreversible damage to the testicle, and in this case the indication for the affected testicle removal may arise (23). Although the applied surgical intervention can stop the destruction of the testicles with ischemia, it is not certain that the function of the testicles is fully preserved. Since the blood flow restored during detorsion can trigger more intensive ROS production in ischemic tissue (24). In summary, testicular damage depends on the critical level of oxidative damage due to reperfusion. In this regard, the discovery of new therapeutic agents is important as adjuvant therapy in surgical detorsion to reduce IR-induced oxidative stress.

In the presented experimental model, the ischemic model was established by rotating the left testicle of the rats around 720° clockwise and creating a testicular torsion. After two hours of ischemia, reperfusion was performed by detorsion and blood flow to the testis was re-established for 2 hours. Based on the oxidant and antioxidant findings we obtained, we observed that testicular tissue had severe damage as a result of IR. In particular, we think that oxidant molecules play an important role in the pathogenesis of testicular damage. In the literature, various biological agents that have antioxidant properties such as hygenamine, cryptotanshinone and barbaloin have been used to reduce testicular damage (11,12,16). These agents have been shown to be effective in reducing IR injury. In this study, which we think will contribute to the literature; we evaluated the role of hyperoside, which is known to have antioxidant properties, in preventing testicular tissue damage. In previous studies with hyperoside, whose antioxidant properties are known, data

has been presented that hyperoside has a protective effect on the organs such as heart and ovary (25,26).

In a previous experimental testicular TD study, researchers demonstrated that the testicles damaged and MDA level increased due to 720° degrees of rotation and 6 hours of ischemia and 6 hours of reperfusion (27). In another study, in which testicular TD was established, it was shown that damage occurred in testicles and MDA level increased due to 720° degree rotation and 1 hour ischemia and reperfusion time application (28). Moreover, Jafari et al. were reported that MDA level increased, antioxidant defense was insufficient and damage occurred in the testicles due to performed 1 hour ischemia with 720° degree rotation and 5 hours of reperfusion. In addition, it has been reported that MDA levels increase and antioxidant defense is insufficient due to 2-hour ischemia with 720° degree rotation and 24-hour reperfusion, and as a result, significant damage on the testicles developed (29). In addition, it has been stated that in some studies that performed 2 hours of torsion and 2 hours of reperfusion with 720° degree spermatic cord occlusion, MDA level increased and caused oxidative damage in testicular tissue (11,12,16). The MDA results we obtained reflected oxidative damage in testicular tissue in accordance with the studies in the literature. MPO is an enzyme involved in nitrite, nitrate and peroxidation processes involved in nitric oxide metabolism. In addition to the decrease in cellular antioxidant capacity, MPO is an important indicator showing the level of oxidative stress. In previous studies, in the testicular TD model created experimentally, MPO activity was significantly increased in the torsioned group (11,30). SOD is a member of the antioxidant defense system that catalyzes the conversion of superoxide to H_2O_2 and molecular oxygen (14). Topdagi et al. were expressed that SOD activity decreased due to 720° degrees of rotation and 2 hours of ischemia and 2 hours of reperfusion (12). In another study, it was reported that SOD activity decreased due to 1 hour of ischemia and 5 hours of reperfusion (31). Kazaz et al. were reported that TOS and OSI values increased due to performed 4 hours ischemia and 2 hours of reperfusion (32). Moreover, it was stated that TOS and OSI values increased significantly while TAS value decreased in Tanyeli et al studies (11). The biochemical results obtained in this study are compatible with previous studies in the literature.

It was stated that hyperoside protected granulosa cells against H_2O_2 -induced apoptosis and oxidative stress by reducing MDA levels and supporting SOD activity (26). In another study, it was suggested that hyperoside significantly inhibited OVA-induced oxidative stress as demonstrated by decreased MDA, and increased GSH and SOD levels. As a result of hyperoside protected against OVA-induced asthma by inflammatory and oxidative responses (33). It was found in the study done by Piao et al that effective of the hyperoside to decrease the ROS generation as well as increment antioxidant enzyme activity (6). Hyperoside was noticed to leak the cell membrane as well as restrict free radical consistution and the spread of free radical reactions by chelating transition metal ions in the cells (34).

CONCLUSION

In this study, it was determined that hyperoside treatment was very effective in reducing oxidizing damage of testicular tissue formed due to testicular TD model and reducing lipid peroxidation. As a result, hyperoside therapy is thought to act as a free radical scavenger or promote antioxidant enzyme activity and further modulate cellular antioxidant potential.

Competing interests: The authors declare that they have no competing interest.

Financial Disclosure: There are no financial supports.

Ethical approval: The study was carried out with ethical consent from the Ataturk University Animal Experiments Local Ethics committee (Protocol number and date: 200/07.11.2019).

REFERENCES

- Zou YP, Lu YH, Wei DZ. Antioxidant activity of a flavonoid-rich extract of *Hypericum perforatum* L. in vitro. *J Agr Food Chem* 2004;52:5032-9.
- Conforti F, Statti GA, Tundis R, et al. Antioxidant activity of methanolic extract of *Hypericum triquetrifolium* Turra aerial part. *Fitoterapia* 2002;73:479-83.
- Schettler V, Methe H, Staschinsky D, et al. Review: the oxidant/antioxidant balance during regular low density lipoprotein apheresis. *Ther Apher* 1999;3:219-26.
- Shi YP, Qiu XX, Dai MJ, et al. Hyperoside Attenuates Hepatic Ischemia-Reperfusion Injury by Suppressing Oxidative Stress and Inhibiting Apoptosis in Rats. *Transpl P* 2019;51:2051-9.
- Xiao R, Xiang AL, Pang HB, et al. Hyperoside protects against hypoxia/reoxygenation induced injury in cardiomyocytes by suppressing the Bnip3 expression. *Gene* 2017;629:86-91.
- Piao MJ, Kang KA, Zhang R, et al. Hyperoside prevents oxidative damage induced by hydrogen peroxide in lung fibroblast cells via an antioxidant effect. *Bba-Gen Subjects* 2008;1780:1448-57.
- Asghari A, Akbari G, Meghdadi A, et al. Protective effect of metformin on testicular ischemia/reperfusion injury in rats. *Acta Cir Bras* 2016;31:411-6.
- Parlaktas BS, Atilgan D, Ozyurt H, et al. The biochemical effects of ischemia-reperfusion injury in the ipsilateral and contralateral testes of rats and the protective role of melatonin. *Asian J Androl* 2014;16:314-8.
- Pentyala S, Lee J, Yalamanchili P, et al. Testicular torsion: a review. *J Low Genit Tract Dis* 2001;5:38-47.
- Ghasemnejad-Berenji M, Ghazi-Khansari M, Yazdani I, et al. Effect of metformin on germ cell-specific apoptosis, oxidative stress and epididymal sperm quality after testicular torsion/detorsion in rats. *Andrologia* 2018;50.
- Tanyeli A, Eraslan E, Ekinci Akdemir FN, et al. Cryptotanshinone mitigates ischemia reperfusion-induced testicular damage: A experimental study. *Annals Med Res* 2019;26:2549-52.
- Topdagi O, Tanyeli A, Ekinci Akdemir FN, et al. The Effects of Higenamine on Testicular Damage Injured by Ischemia Reperfusion: A Biochemical Study. *Turk J Sci.* 2019;4:92-9.
- Gulcin I. Antioxidant and antiradical activities of L-carnitine. *Life Sci* 2006;78:803-11.
- Gulcin I. Antioxidant activity of food constituents: an overview. *Arch Toxicol* 2012;86:345-91.
- Ameli M, Hashemi MS, Moghimian M, et al. Protective effect of tadalafil and verapamil on testicular function and oxidative stress after torsion/detorsion in adult male rat. *Andrologia* 2018;50.
- Topdagi O, Tanyeli A, Ekinci Akdemir FN, et al. Barbaloin Attenuates Oxidative Testicular Injury Induced by Ischemia Reperfusion via Antioxidant Effects. *Turk J Sci* 2020;5:28-33.
- Akdemir FNE, Yildirim S, Kandemir FM, et al. Protective effects of gallic acid on doxorubicin-induced cardiotoxicity; an experimental study. *Arch Physiol Biochem* 2019.
- Ohkawa H, Ohishi N, Yagi K. Assay for lipid peroxides in animal tissues by thiobarbituric acid reaction. *Anal Biochem* 1979;95:351-8.
- Bradley PP, Priebat DA, Christensen RD, et al. Measurement of Cutaneous Inflammation - Estimation of Neutrophil Content with an Enzyme Marker. *J Invest Dermatol* 1982;78:206-9.
- Sun Y, Oberley LW, Li Y. A Simple Method for Clinical Assay of Superoxide-Dismutase. *Clin Chem* 1988;34:497-500.
- Harma M, Harma M, Kocyigit A, et al. Increased DNA damage in patients with complete hydatidiform mole. *Mutat Res-Gen Toxicol Environment Mutagen* 2005;583:49-54.
- Tanyeli A, Ekinci Akdemir FN, Eraslan E, et al. Antioxidant and anti-inflamatur effectiveness of caftaric acid on gastric ulcer induced by indomethacin in rats. *Gen Physiol Biophys* 2019;38:175-81.
- Dejban P, Rahimi N, Takzare N, et al. Beneficial effects of dapsone on ischemia/reperfusion injury following torsion/detorsion in ipsilateral and contralateral testes in rat. *Theriogenol* 2019;140:136-42.
- Dokmeci D, Kanter M, Inan M, et al. Protective effects of ibuprofen on testicular torsion/detorsion-induced ischemia/reperfusion injury in rats. *Arch Toxicol* 2007;81:655-63.
- Li ZL, Hu J, Li YL, et al. The effect of hyperoside on the functional recovery of the ischemic/reperfused isolated rat heart: Potential involvement of the extracellular signal-regulated kinase 1/2 signaling pathway. *Free Radical Bio Med* 2013;57:132-40.
- Wang XX, Fan GM, Wei FM, et al. Hyperoside protects rat ovarian granulosa cells against hydrogen peroxide-induced injury by sonic hedgehog signaling pathway. *Chem-Biol Interact* 2019;310.
- Yurtcu M, Abasiyanik A, Avunduk MC, et al. Effects of melatonin on spermatogenesis and testicular ischemia-reperfusion injury after unilateral testicular torsion-detorsion. *J Pediatr Surg* 2008;43:1873-8.

28. Mirhoseini M, Talebpour Amiri F, Karimpour Malekshah AA, et al. Protective effects of melatonin on testis histology following acute torsion-detorsion in rats. *Int J Reprod Biomed* 2017;15:141-6.
29. Fouad AA, Qutub HO, Jresat I. Dose-dependent protective effect of baicalin against testicular torsion-detorsion in rats. *Andrologia* 2017;49.
30. Aksoy H, Yapanoglu T, Aksoy Y, et al. Dehydroepiandrosterone treatment attenuates reperfusion injury after testicular torsion and detorsion in rats. *J Pediatr Surg* 2007;42:1740-4.
31. Jafari A, Ghasemnejad-Berenji H, Nemati M, Ghasemnejad-Berenji M. Topiramate: A novel protective agent against ischemia reperfusion-induced oxidative injury after testicular torsion/detorsion. *Am J Emerg Med* 2020.
32. Kazaz IO, Mentese A, Demir S, et al. Berberine inhibits the ischemia-reperfusion induced testicular injury through decreasing oxidative stress. *Am J Emerg Med* 2020;38:33-7.
33. Ye P, Yang XL, Chen X, et al. Hyperoside attenuates OVA-induced allergic airway inflammation by activating Nrf2. *Int Immunopharmacol* 2017;44:168-73.
34. Liu ZY, Tao XY, Zhang CW, et al. Protective effects of hyperoside (quercetin-3-o-galactoside) to PC12 cells against cytotoxicity induced by hydrogen peroxide and tert-butyl hydroperoxide. *Biomed Pharmacother* 2005;59:481-90.