

Amyand's hernia in children: A 20-year experience at a tertiary referral hospital

 Tugay Tartar,  Mehmet Sarac,  Unal Bakal,  Ibrahim Akdeniz,  Ahmet Kazez

Department of Pediatric Surgery, Faculty of Medicine, Firat University, Elazig, Turkey

Copyright@Author(s) - Available online at www.annalsmedres.org

Content of this journal is licensed under a Creative Commons Attribution-NonCommercial 4.0 International License.



Abstract

Aim: Amyand's hernia is detected in 0.42%–1% of children with inguinal hernia (IH) and is quite difficult to diagnose prior to surgery. There is no consensus on its treatment.

Materials and Methods: The records of patients who underwent IH repair and were diagnosed with Amyand's hernia between 2001 and 2019 were retrospectively analysed in terms of age, gender, complaints at presentation, side of IH, treatment methods (with appendectomy or reduction of appendix), complications, duration of hospital stay and follow-up.

Results: In total, 3,577 patients (male/female: 3,045/532) who underwent surgery for IH and 1,898 patients who underwent appendectomy were analysed. Cases with Amyand's hernia (n=47, male/female: 41/6) accounted for 1.31%, 1.4% and 0.31% of all IH, incarcerated/strangulated hernia and appendectomy cases, respectively. The median age was 3 months. In one case, the appendix was located within the left hernial sac. One patient presented with a complaint of recurrent abscess in the right inguinal region. In all cases, the diagnosis was made intra-operatively based on identification. In 23.4% of the cases with Amyand's hernia, appendectomy was performed. In 46 of the 47 cases diagnosed with Amyand's hernia, inguinal transverse incision and high ligation procedures were performed. Acute appendicitis did not develop during follow-up in cases without appendectomy.

Conclusion: Because the appendix plays an active role in the immune system, especially during childhood, and is used in some pathologic cases as luminal supportive tissue, we believe that appendectomy should not be performed if there are no signs of inflammation and the appendix can be reduced into the abdomen.

Keywords: Amyand's hernia; appendectomy; child; incarcerated/strangulated; inguinal hernia

INTRODUCTION

Amyand's hernia is a condition in which the appendix is located within an inguinal hernia (IH) sac, which first described by Claudius Amyand in 1735 (1). It is rare condition, and detected in 0.42%–1% of all inguinal hernias in children (2,3). The diagnosis of Amyand's hernia is incidental; in most cases during IH repair (3). There is no consensus optimal treatment of Amyand's hernia. Some authors recommend performing appendectomy an irritated appendix in the inguinal canal can initiate the inflammatory process, along with hernia repair surgery, whereas others suggest that appendectomy should not be performed in the absence of symptoms of inflammation in the appendix (2-4).

The present study aimed to present our 19-year experience of the treatment of Amyand's hernia at a tertiary referral hospital with a focus on the difficulty in preoperative diagnosis and the decision whether or not to perform appendectomy.

MATERIALS and METHODS

The present study was conducted in accordance with the principles of the Declaration of Helsinki and was approved by Firat University Non-Interventional Trials Ethics Committee (Decision no: 2020/01-11, Date: 02/01/2020). Records of the cases that underwent IH repair and were diagnosed with Amyand's hernia at the pediatric surgery clinic of a university hospital between January 2001 and December 2019 were retrospectively analysed. We created registration forms that included information about the patients' age, gender, complaints at presentation, and side of IH, physical and radiological examination findings, treatment methods (hernia repair with appendectomy or hernia repair with reduction of appendix), complications, duration of hospital stay, postoperative follow-up duration and histopathological results of the cases with appendectomy. The number of patients who underwent appendectomy without Amyand's hernia within the same period of the study was determined.

Received: 31.03.2021 **Accepted:** 29.06.2021 **Available online:** 17.01.2022

Corresponding Author: Tugay Tartar, Department of Pediatric Surgery, Faculty of Medicine, Firat University, Elazig, Turkey

E-mail: tugaytartar@gmail.com

Statistical Analysis

IBM SPSS Statistics version 22 (SPSS Inc., Chicago, IL, USA) was used for statistical analysis. In the Post Hoc Power analysis performed after the data were extracted (for an effect size (w) of 0.6, the number of patients with Amyand's hernia would be 47 at a significance level of 0.05), it was determined that 90% power was reached. The normality of the distribution of quantitative data was analyzed using the Shapiro–Wilk test. Furthermore, Mann–Whitney U test was used for grouped comparison of continuous variables. Baseline demographic data and clinical characteristics were summarized using descriptive statistics; categorical variables were expressed as frequencies and percentages and continuous variables were expressed as mean (\pm standard deviation) or median (minimum–maximum). $P < 0.05$ was considered statistically significant.

RESULTS

The data of 3,577 patients (male/female: 3,045/532) who underwent surgery for IH within a period of 19 years were analyzed. The Amyand's hernia incidence was 1.31% ($n=47$) among cases with IH ($n=3,577$). Furthermore, 12.2% of the cases with IH ($n=438$; male/female: 231/207) had incarcerated/strangulated (I/S) hernia. The incidence of Amyand's hernia in cases with I/S hernia was 1.37% ($n=6$). There were 1898 cases that underwent appendectomy for acute appendicitis within the same period. The incidences of normal appendix and acute appendicitis in the IH sac were 2.16% and 0.31%, respectively. Among the cases with Amyand's hernia, 89.1% ($n=41$) were male, and 10.9% ($n=6$) were female. The median age was 3 (minimum–maximum: 1–72) months. Among the cases with Amyand's hernia, 78.8% ($n=37$) of the cases had right IH, 2.1% ($n=1$) had left IH and 19.2% ($n=9$) had bilateral IH. The most common complaints of the patients were swelling in the groin and vomiting. The most common physical examination findings were swelling, tenderness and redness in the groin. Superficial tissue ultrasonography was performed in seven cases and abdominal computed tomography in one case. Radiological examination showed the presence of a bowel loop in the inguinal canal in five cases. Furthermore, 12.8% ($n=6$) of patients were urgently operated due to I/S hernia. In all cases, the diagnosis was made intraoperatively based on the identification of the appendix within the hernia sac (Figure 1).

In total, 23.4% ($n=11$) of the patients underwent appendectomy. The demographical and clinical characteristics of the patients with Amyand's hernia are presented in Table 1. Six of these patients showed macroscopic presentation of acute appendicitis. In five patients, blood supply to the appendix was disrupted owing to the detachment of the appendix lying adjacent to the hernia sac. Histopathological images of patients with acute appendicitis and lymphoid hyperplasia are shown in Figure 2. One case with appendectomy presented with a complaint of recurrent abscess in the right inguinal region. Direct abdominal radiography revealed a foreign body in the inguinal region (Figure 3) (5).

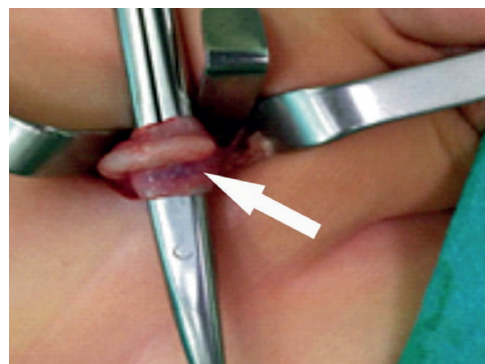


Figure 1. Appendix tissue located in the right inguinal hernia sac

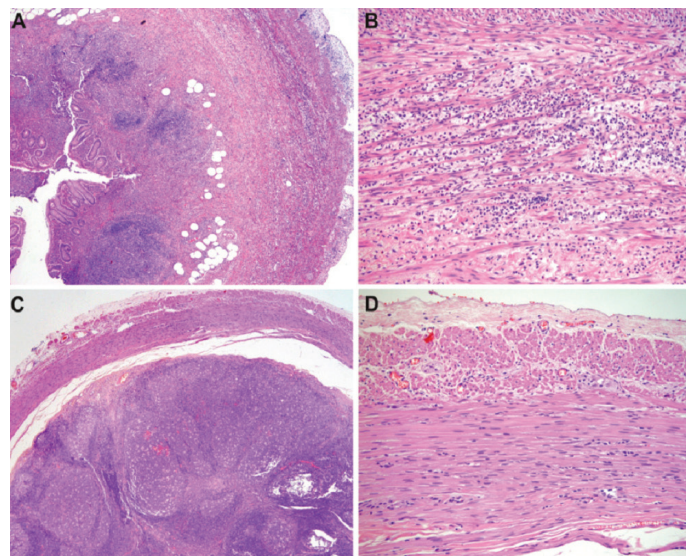


Figure 2. Histopathological images of patient with acute appendicitis (A: X40, B: X200). Histopathological images of patient with lymphoid hyperplasia (C: X40, D: X200)

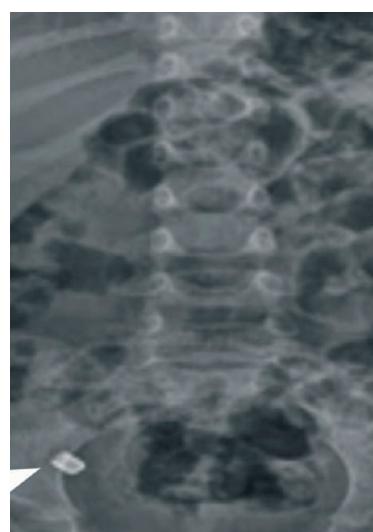


Figure 3. Direct abdominal radiography. Foreign body (arrow) in the right inguinal region

Abdominal computed tomography revealed that the foreign body was located intra-abdominally (Figure 4). Laparotomy revealed perforated appendicitis extending into the inner part of the hernia sac in the inguinal canal and containing a foreign body (metal lid) in it. Apart from

this case, appendectomy was performed within the hernia sac through inguinal transverse incision during hernia repair in all other cases. In 76.6% (n=36) of the cases, appendectomy was not performed and the appendix was reduced into the abdomen. The median age for the cases with and without appendectomy was 3 (minimum–maximum: 1–72) months and 3 (minimum–maximum: 1–30) months, respectively. Although the median age of patients with appendectomy was younger, there was no

statistically significant difference ($p=0.990$). The median duration of hospital stay of the cases with Amyand's hernia was 1 (minimum–maximum: 1–6) day. The median duration of follow-up was 116 ± 9.4 months. There was no complication in any of the cases treated for Amyand's hernia. No signs of acute appendicitis developed during the follow-up period in 36 cases that underwent reduction of the appendix into the abdomen. Pathology reports of three cases could not be retrieved.

Table 2. Demographical and clinical characteristics of patients with Amyand's hernia

	Median Age (month)	Gender (n: 47)	Side	Surgical intervention (n, %)	Appendectomy pathologies	
Patients with appendectomy	3 (min.–max.: 1–72)	Male: 10 Female: 1	Right: 11	11 23.4%	Appendix vermiformis	3
					Lymphoid hyperplasia	2
					Acute appendicitis	2
					Inflammation	1
					*	3
Patients without appendectomy	3 (min.–max.: 1–30)	Male: 31 Female: 5	Right: 35 Left: 1	36 76.6%		

Min: minimum; max: maximum; *: patients with no pathology reports

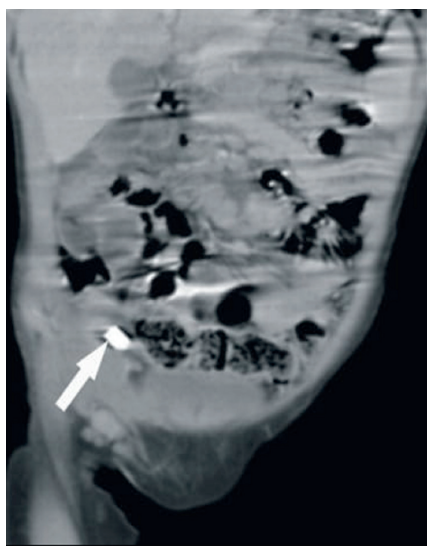


Figure 4. Computed tomography image (coronal section). Foreign body (arrow) extending into the right inguinal region

DISCUSSION

Inguinal hernia is one of the most common surgical pathologies in children. The prevalence of IH is between 0.8% and 4.4% (6). Amyand's hernia is detected in 0.4%–1% of children with IH (2,3). According to the literature, almost all cases with Amyand's hernia were male (2-4,7-11). A possible reason for this is the localization of ovarian tissue in girls, which is inside the hernia sac rather than the appendix. The Amyand's hernia incidence in cases with IH in the present study (1.31%) was found to be higher than that in the literature (2,3). IH is 6–10 times more common

in boys than in girls (12-14). The male/female ratio in the present study was 5.7 and 8.2 for cases with IH and those with Amyand's hernia, respectively. The gender distribution in cases with IH in this study was consistent with that in the literature, whereas the incidence of Amyand's hernia in girls was higher in this study than in the literature (2-4).

Amyand's hernia is right-sided in most cases owing to the localization of the appendix. However, left-sided Amyand's hernia can also be rarely observed owing to mobile caecum, situs inversus and malrotation (7). Consistent with the literature, 97.9% (n=46) of the cases in this study had right-sided Amyand's hernia, whereas one case with mobile caecum (2.1%) had left-sided Amyand's hernia. Furthermore, 33% of all cases with IH are diagnosed within 0–6 months (6,13,14). Studies indicate that Amyand's hernia is more common within the first 6 months of life (56.5%–85.7%) (3,4). In the present study, 84.8% (n=39) of the cases were diagnosed within the first 6 months, which is consistent with the literature.

According to mainstream opinion about the etiology of Amyand's hernia, the appendix enters into the hernia sac and is compressed due to increased intra-abdominal pressure, thereby distorting blood flow and resulting in inflammation (15). The incidences of normal appendix and acute appendicitis in IH sac were 1% and 0.13%, respectively (8). The incidences of normal appendix and acute appendicitis in IH sac in the present study were 2.5-fold higher than those in the literature (2.16%, 0.31%). In 45.5% (n=5) of the cases with appendectomy, the cause was detachment of the appendix and meso-appendix

from the hernia sac, which resulted in impaired blood flow to the appendix. It has been suggested that the appendix might have adhered to the hernia sac via formation of fibrous bands due to inflammation and the appendix remaining in the hernia sac for a long time because of a prolonged increase in intra-abdominal pressure owing to reasons such as crying and contractions, particularly in children (16).

Amyand's hernia is diagnosed during surgery in most cases. These patients are commonly operated with the diagnosis of I/S hernia (9). Although it has been reported that ultrasonography and computed tomography can be employed in preoperative identification, they are not routinely used in the diagnosis of IH (10,11,17). A study has reported that most cases with Amyand's hernia were missed in ultrasonography (11). The first preoperative diagnosis of Amyand's hernia using ultrasonography was made by Akfirat et al. in 1999 in a 2-month old male infant (11). In the present study, Amyand's hernia could not be diagnosed by superficial tissue ultrasonography, which was performed in seven cases with symptoms of I/S hernia. Furthermore, 12.8% (n=6) of patients were urgently operated for I/S hernia. We believe that macroscopic findings and the appendix being reducible into the abdomen by detaching it from the hernia sac are important for making decisions regarding appendectomy in cases with Amyand's hernia. Although preoperative diagnosis provides benefits in preventing manipulation of the appendix, it does not introduce any difference in terms of the treatment to be given. Furthermore, computed tomography may also be considered as an unnecessary procedure in terms of benefit/damage ratio taking into account the amount of radiation exposure of the patient.

There is no definite consensus regarding whether appendectomy should be performed to treat Amyand's hernia (9,18). The prevailing opinion, however, is that appendectomy should not be performed in cases without findings of acute appendicitis in which intra-abdominal reduction is feasible (3,4,18). In 23.4% of the cases included in the present study, appendectomy was performed. There were no signs of acute appendicitis during follow-up in any of the cases without appendectomy. Considering that the appendix is beneficial for the immune system (19) and can be used for urinary diversion or Mitrofanoff stoma (2,3) and that symptoms of acute appendicitis were not observed in cases with Amyand's hernia in which the appendix was reduced, appendectomy should not be performed in cases with no symptoms of acute appendicitis and in which intra-abdominal reduction is feasible. Early intervention is crucial for preventing potential complications in Amyand's hernia (20). Particularly in male patients with right-sided I/S hernia, not being too insistent on the reduction of structures within the hernia sac and performing an early surgical procedure may be effective in preventing acute appendicitis, which may develop due to manual manipulation. However, opening the hernia sac during surgery and evaluating whether there are intra-abdominal structures is effective in preventing possible complications.

CONCLUSION

Amyand's hernia is a rare pathology in pediatric surgery. Amyand's hernia should be considered in the first 6 months of life in male infants with right-sided I/S hernia. Although there is no clear standard in treatment, considering the appendix plays an active role in the immune system, especially during childhood, and is used in some pathologic cases as luminal supportive tissue, we suggest that appendectomy should not be performed if there are no signs of inflammation and the appendix can be reduced into the abdomen.

Acknowledgements: The authors thanks to Prof. Dr. A. Ferda Dagli for his efforts to the preparing histopathologic preparations.

Competing Interests: The authors declare that they have no competing interest.

Financial Disclosure: There are no financial supports.

Ethical Approval: The present study was conducted in accordance with the principles of the Declaration of Helsinki and was approved by Firat University Non-Interventional Trials Ethics Committee (Decision no: 2020/01-11, Date: 02/01/2020).

REFERENCES

- Hutchinson R. Amyand's hernia. J R Soc Med 1993;86:104-5.
- Kaymakci A, Akillioglu I, Akkoyun I, et al. Amyand's hernia: a series of 30 cases in children. Hernia 2009;13:609-12.
- Cigsar EB, Karadag CA, Dokucu AI. Amyand's hernia: 11 years of experience. J Pediatr Surg 2016;51:1327-9.
- Gunduz M. Amyand's hernia in children. Haydarpasa Numune Med J 2018;58:45-7.
- Tartar T, Sarac M, Bakal B, Onur MR, Kazez A. Turk J Pediatr 2020;62:889-92.
- Lloyd DA, Rintala RJ. Inguinal hernia and hydrocel. In: O'Neill JA Jr, Rowe MI, Grosfeld, et al (eds), Pediatric Surgery. 5th ed. St. Louis, MO: Mosby Year – Book; 1998.
- Gupta S, Sharma R, Kaushik R. Left-sided Amyand's hernia. Singapore Med J 2005;46:424-5.
- Apostolidis S, Papadopoulos V, Michalopoulos A, Paramythiotis D, Harlaftis N. Amyand's hernia: a case report and review of the literature. Internet J Surg 2005;6.
- Sarsu SB. Is Appendectomy Necessary in Children with Amyand Hernia? J Pediatr Res 2016;3:50-2.
- Maekawa T. Amyand's Hernia Diagnosed by Computed Tomography. Intern Med 2017;56:2679-80.
- Akfirat M, Kazez A, Serhatlioglu S. Preoperative sonographic diagnosis of sliding appendiceal inguinal hernia. J Clin Ultrasound 1999;27:156-8.
- Zorludemir U. Inguino-skrotal patolojiler. Turk Ped Ars 2010;45:23-8.
- Brandt ML. Pediatric hernias. Surg Clin North Am 2008;88:27-43.

14. Ein SH, Njere I, Ein A. Six thousand three hundred sixty-one pediatric inguinal hernias: a 35-year review. *J Pediatr Surg* 2006;41:980-6.
15. Boukesra T, Zitouni H, Mefteh S, Ben Dhaou M, Jallouli M, Mhiri R. Preoperative clinical diagnosis of an Amyand's hernia. *Tunis Med* 2014;92:231-2.
16. Tisdale JB, Barwell NJ. Amyand's hernia and peri-appendicular abscess in primary care. *Hernia* 2008;12:311-2.
17. Inan I, Myers PO, Hagen ME, et al. Amyand's hernia: 10 years' experience. *Surgeon* 2009;7:198-202.
18. Bozan MB, Yazar FM, Erol F, Gul E, Alatas OD. A condition that should be kept in mind in incarcerated hernia: Amyand's hernia. *North Clin Istanb* 2017;4:78-80.
19. Svensson JF, Hall NJ, Eaton S, et al. A review of conservative treatment of acute appendicitis. *Eur J Pediatr Surg* 2012;22:185-94.
20. Sharma P, Dixit S, Batra R, et al. Amyand's hernia in month old child: a rare case report. *Int J Sci Stud* 2015;2:181-3.