



Nightmare of a pathologist: Metastatic adenocarcinoma from breast to gastrointestinal system and gallbladder

Selma Sengiz Erhan^{a,*}, Sevinc Hallac Keser^b, Sibel Sensu^c, Damla Karabiyik Altio^k^a,
 Bahar Sari^d, Ali Alemdar^e

^aDepartment of Pathology, Prof. Dr. Cemil Tascioglu City Hospital, Istanbul, Turkey

^bDepartment of Pathology, Kartal Dr. Lutfi Kirdar City Hospital, Istanbul, Turkey

^cDepartment of Pathology, Faculty of Medicine, Istinye University, Istanbul, Turkey

^dDepartment of Pathology, Kahta State Hospital, Adiyaman, Turkey

^eDepartment of Surgery, Prof. Dr. Cemil Tascioglu City Hospital, Istanbul, Turkey

Abstract

ARTICLE INFO

Keywords:

Breast; gallbladder; gastrointestinal system; metastasis

Received: May 03, 2021

Accepted: Aug 19, 2021

Available Online: Feb 15, 2022

DOI: [10.5455/annalsmedres.2021.05.382](https://doi.org/10.5455/annalsmedres.2021.05.382)

Aim: Breast tumors usually metastasize to lymph nodes, bone, lung, liver and central nervous system, and rarely to gastrointestinal system (GIS) and gallbladder. In this study, we aimed to present and discuss our breast carcinoma cases with GIS and gallbladder metastases.

Material and Methods: Clinicopathological findings of nine breast tumors with metastases to gallbladder and GIS were evaluated in our study.

Results: The mean age was 51.2 years. Seven cases, five of which were invasive ductal carcinoma (IDC) and two invasive lobular carcinoma (ILC), had metastases to GIS. In these cases, metastatic foci were mostly observed in stomach, small intestine, sigmoid colon and rectum, respectively. The diagnosis of two cases with metastases to gallbladder was IDC. In two cases, one with gastric and other, with gallbladder metastases, lymph nodes were also involved. All cases died aside from an IDC with gallbladder metastasis and an ILC with gastric metastasis.

Conclusion: Metastasis from a breast tumor should be taken into consideration particularly in cases with unknown primary. GIS and gallbladder, though rare, might be the metastatic foci of breast carcinomas.



Copyright © 2022 The author(s) - Available online at www.annalsmedres.org. This is an Open Access article distributed under the terms of Creative Commons Attribution-NonCommercial-NoDerivatives 4.0 International License.

Introduction

Breast carcinoma is the most common type of cancer in women that causes mortality with metastases (1, 2). Metastases are mostly observed in lymph nodes, chest wall, bone, lung and liver. Less frequently observed metastatic foci are ovary, bone marrow, gastrointestinal system (GIS), adrenal and very rarely gallbladder (3, 4). Among the most frequent histopathological sub types, the metastatic spread of invasive ductal carcinoma (IDC) and invasive lobular carcinoma (ILC) are different. While IDC has a tendency to metastasize to liver, lungs and brain, ILC spreads to GIS, gynecological organs and peritoneal metastasis (1, 2, 5). Since it will affect the treatment of the patient, it is important to get the precise diagnosis of the lesion in the metastatic organ and rare metastatic sites can cause difficulties in diagnosis (5, 6). In our study, we aimed to examine the clinicopathological findings of the primary breast carcinoma cases with rare metastatic foci which are GIS and gallbladder, in the light of the literature.

Materials and Methods

Our study is a retrospective one in which cases diagnosed in our department between 2012-2018 and showing metastases to GIS and gallbladder were included. Clinical information of the cases was investigated. The clinicopathological findings of the primary breast tumor (year of diagnosis, tumor location, histological subtype and size, lymph node positivity, estrogen receptor (ER), progesterone receptor (PR) and cerbB2 expressions, and treatments) were reviewed. The clinicopathological findings of the metastatic focus (metastasis location, endoscopic and radiological findings, surgical procedures for these foci, if any, ER, PR and cerbB2 expression in the metastatic focus, time to metastasis and post-metastatic follow-up) were reviewed. Pathology preparations (hematoxylin&eosin (H&E) and immunohistochemical (IHC) markers) of the cases were re-examined. The cases were listed according to the year of primary tumor diagnosis and encoded numerically.

Results

Clinicopathological findings related to primary breast tumor of cases Nine cases were included in our study. All of the cases were women; the average age was 51.2 (age range 38- 62).

*Corresponding author:

Email address: selmaserhan@hotmail.com (Selma Sengiz Erhan)

Seven of the cases were diagnosed as IDC and two as ILC. Surgical treatment was performed in all of the cases. Neoadjuvant chemoradiotherapy (CRT) was performed in the two cases before surgery. Seven patients were given chemotherapy (CT), radiotherapy (RT), and endocrine therapy as additional therapy. At the time of the diagnosis, all the cases had metastatic lymph nodes in axillary dissections. Since two cases were sent to our department for consultation, information about primary tumor size, lymph node status and hormone expressions could not be obtained. The clinicopathological findings of the primary breast tumors of the cases are given in Table 1.

Clinicopathological findings of patients who metastasized to GIS

In our study, the organs that received metastases in GIS were stomach, small intestine, sigmoid colon and rectum. There were seven cases with metastatic foci in GIS. Five of the cases were diagnosed as IDC and two were ILC. Gastric metastasis was detected in four patients with IDC (Case No: 1, 4, 7, 8) and in one case with ILC (Case No: 9). One of the patients with IDC (Case No: 7) had a second primary tumor with a diagnosis of squamous cell carcinoma located in the distal esophagus, which occurred five years after the diagnosis of primary breast tumor. There were two cases (Case No: 1, 4) with different organ metastases before the diagnosis of gastric metastasis, and both were at ovaries. There were four cases with simultaneous organ involvement with gastric metastasis. Rectum, liver and bone metastases were detected in each one (Case No: 4, 8, 9, respectively).

The fourth case (Case No: 7) was the case with the second primary diagnosis of distal esophagus squamous cell carcinoma. In this case, one of the metastatic foci was at esophagus and 10 small lymph nodes in small and large curvature were also involved. In one case with IDC (Case No: 2), sigmoid colon was detected; and in one case with ILC (Case No: 3), small bowel and sigmoid colon metastasis were detected. In the histopathological examinations of endoscopic biopsies of the cases, pertaining to the cases with IDC, tumoral infiltration consisting of solid islands and small adenoid structures was observed (Figure 1).

Nuclear pleomorphism was mild. In the metastases of the patients with the ILC diagnosis, there was discohesive small tumoral cell infiltration (Figure 2).

The cells which showed linear alignments and some signet-ring cells also attracted attention. In biopsies, no signs of dysplasia or atypia were detected in normal surface epithelium and glandular structures of gastric or intestinal mucosal tissue. In the case with the second primary diagnosis of squamous cell carcinoma, the tumor detected in the lymph nodes consisted of small solid and adenoid structures with pericapsular spread. The average time between primary tumor diagnosis and metastases of the cases was 7.14 years (1-18 years).

Clinicopathological findings of the patients who have metastases to the gallbladder In our study, there were two cases (Case No: 5, 6) that metastasized to the gallbladder and both were IDC. In infiltrated half of the lymph node, consisted of adenoid structures that anastomosed with each other (Figure 3).

Chronic cholecystitis and focal antral metaplasia were detected in the sections of the gallbladder. The other case (Case No: 5) was sent to our department for consultation. The tumor observed in the sections had a full thickness infiltration of the

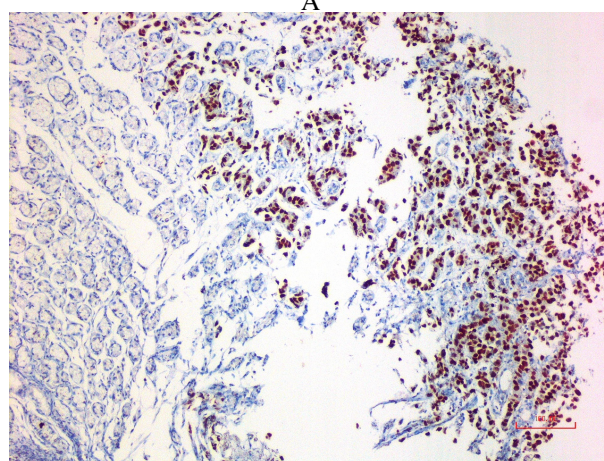
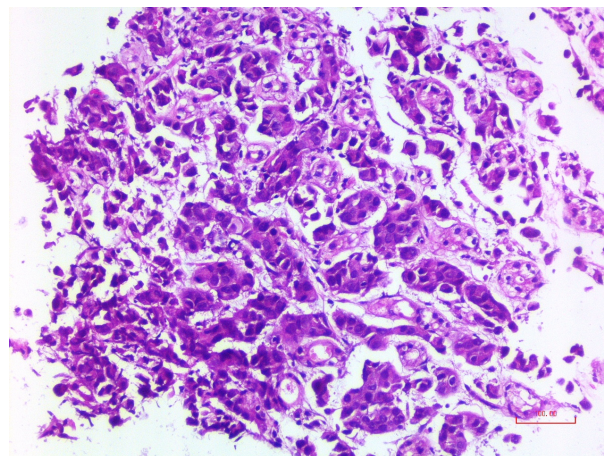


Figure 1. Invasive ductal carcinoma metastasis in stomach tissue a: Tumor consisting of adenoid structures that spread between normal gland structures (H&E, x200) b: GATA3 expression on tumor cells (x100)

gallbladder wall. It consisted of small adenoid structures that were spreading through the mucosa, muscular layer and perimuscular connective tissue and extending to the serosa. The period between the primary tumor diagnosis and metastases of the cases was 4 years. The clinicopathological findings of the metastatic foci of all the cases are presented in Table 2. one of the cases (Case No: 6), cholecystectomy material due to multiple stones revealed metastasis in the lymph node dissected from the neck region. The tumor, which infiltrated half of the lymph node, consisted of adenoid structures that anastomosed with each other (Figure 3). Chronic cholecystitis and focal antral metaplasia were detected in the sections of the gallbladder. The other case (Case No: 5) was sent to our department for consultation. The tumor observed in the sections had a full thickness infiltration of the gallbladder wall. It consisted of small adenoid structures that were spreading through the mucosa, muscular layer and perimuscular connective tissue and extending to the serosa. The period between the primary tumor diagnosis and metastases of the cases was 4 years. The clinicopathological findings of the metastatic foci of all the cases are presented in Table 2.

Hormone receptor expressions of cases In our study, one case with GIS and gallbladder metastasis was sent to our department

Table 1. Clinicopathological findings of the cases belonging to primary breast tumors

Patient No	Age	Tumor type	Year of diagnosis	Location	Tumor size	Lymph node	ER (%)	PR (%)	CerbB2	Treatment
1	47	IDC	2000	Left	3 cm	+3/3	50	40	0	MRM+Axillary dissection CT +Endocrine therapy
2	56	IDC	2007	Right	2.5 cm	+18/23	50	40	0	Mastectomy+axillary dissection CT+ Endocrine therapy
3	56	ILC	2007	Right	2 cm	+12/20	70	70	0	MRM+ axillary dissection CT Neoadjuvant CRT
4	38	IDC	2008	Left	Microscopic foci (due to treatment)	+24/31	70	0	0	Mastectomy+axillary dissection CT+ Endocrine therapy
*5	61	IDC	2008	Right	Consultation	*	*	*	*	BSS
6	53	IDC	2011	Left	Biggest: 3 cm multiple	+23/28	90	40	0	BSS+ axillary dissection RT
7	48	IDC	2011	Right	3.5 cm	+3/3	100	100	0	Neoadjuvant CRT Lumpectomy+ axillary dissection CT +Endocrine therapy
8	40	IDC	2016	Right	3.5 and 0.8 cm (2 foci)	+3/4	10	0	0	BSS+ axillary dissection
*9	62	ILC	2018	Left	Consultation	*	*	*	*	Mastectomy CT

IDC: Invasive ductal carcinoma, ILC: Invasive lobular carcinoma, ER: Estrogen receptor, PR: Progesterone receptor, MRM: Modified Radical Mastectomy, CT: Chemotherapy, CRT: Chemoradiotherapy, BSS: Breast-sparing surgery, RT: Radiotherapy, *Consultation cases

for consultation. Therefore, information about hormone receptor expressions in primary tumor focus could not be obtained. It was noted that there was a difference of ER and PR expression rates between the primary tumor and metastatic foci of the cases evaluated. The difference was complete loss in the expression in four cases diagnosed with IDC metastasized to GIS (Case No: 1, 2, 4, 7). Loss of ER expression was observed in one case with gastric metastasis and PR expression loss in two cases with gastric metastasis and one sigmoid colon metastasis. In the other cases, decrease in hormone receptors, slight increase or similar expression rates were observed. CerbB2 was negative in the primary and metastatic foci of all the cases. The related detailed information is provided in Table 3.

Survival The mean follow-up period of the cases after metastasis is 16 months (6 months-48 months). During the follow-up period, two cases (Case No: 1, 4) died within the same year, four cases (Case No: 3, 5, 7, 8) one year later, and one case (Case No: 2), two years later. The clinical follow-up of two cases (Case No: 6,9) is ongoing.

Discussion

GIS is one of the rare metastatic foci for solid organ-derived tumors (7). The most common origin of a metastatic tumor is the breast with its frequency varying between 8-12%. In the GIS, it is most frequently observed in stomach, followed by esophagus, small intestine, colon, rectum and anus, respectively (8, 9). While the rate reported for gastric metastasis of breast tumors in studies is below 1%, this rate varies between 4-18% in autopsy studies (10). Metastasis can be detected simultaneously in different organs along with gastric metastasis (5, 11). Our study was compatible with the literature and stomach was the most frequently metastasized organ. Small bowel and sigmoid colon

metastasis were observed in the second frequency. Four of the patients with gastric metastases had different organ metastases diagnosed simultaneously. Clinically, endoscopically and radiologically, it is difficult to differentiate metastatic breast tumors from the primary tumors of the gastric or colorectal region they metastasize (3, 12). Nonspecific findings such as nausea, weight loss, epigastric pain are clinical findings that may also suggest digestive system diseases (10). On endoscopic examination, the mucosa may appear heterogeneous.

It may be normal as well as a solitary lesion, erosion or ulcers can be seen (5, 9). As a result of the radiological examinations, diffuse intramural infiltration with the appearance of linitis plastica is observed in ILC cases, while focal involvement can be detected in IDC patients (13). In our cases with endoscopic examinations, usually a hyperemic mucosa was observed, while erosion or ulcers were the other findings that accompanied. Radiological features of the cases were also compatible with the literature. Definitive diagnosis in GIS metastases requires a histopathological examination. However, differentiation is quite hard in cases with unknown primary tumor diagnosis (10). Especially in the histopathological examination of ILC gastric metastases, signet-ring cell appearance can be detected and it can be difficult to differentiate from primary gastric tumor (9). The absence of dysplasia or atypia on the surface and gland epithelium, the absence of tumor to normal mucosa transition, and tumor with an infiltrative spread within normal tissue should primarily suggest the possibility of metastasis (14). In our study, the tumor tissues found in the adequately sampled biopsy materials consisted of adenoid structures showing infiltration within normal tissue suggesting IDC and discohesive cells suggesting ILC. The metastatic behaviors of ILC and IDC differ from each other. In GIS metastases, tumors with

Table 2. Table 2. Clinicopathological findings of the cases belonging to metastatic foci

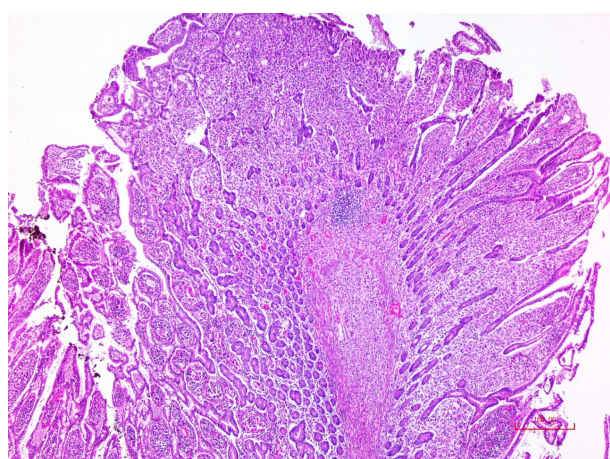
Patient No	Tumor type	Metastatic focus	Radiological and endoscopic findings	ER (%)	PR (%)	CerbB2	YM	SM	Surgical procedures	Second primary
1	IDC	Ovaries (2017) Stomach (2018)	PET/CT: Focal intense hypermetabolic focus at gastric corpus level EF: Hemorrhagic 2 cm ulcer in middle part of gastric corpus	40	0	0	18. year	Ex in same year	None	
2	IDC	Sigmoid colon (2014)	PET/CT: Increased FDG uptake in abdominal lymph nodes EF: Mucosa is hyperemic in sigmoid colon and, 4 mm ulcer	1	0	0	7. year	Ex after 2 years	None	
3	ILC	Sigmoid colon and small intestine (2016)	CT: Diffuse wall thickening in distal segment of transverse colon EF: Hyperemic, hard stenosis in sigmoid colon	70	80	0	9. year	Ex after 1 year	Small intestine resection (for ileus)	
4	IDC	Ovaries (2014) Rectum, Omentum, Stomach (2016)	CT: Diffuse concentric wall thickening at rectum level EF: Hyperemic, milimetric erosion in rectum and hyperemic area in gastric antrum	0	0	0	8. year	Ex in same year	None	
*5	IDC	Gallbladder (2012)		90	30	0	4. year	Ex after 1 year	*	
6	IDC	Gallbladder LN (2015)	USG and CT; Multiple stones in gallbladder	90	40	0	4. year	Alive	None	
7	IDC	Esophageal LN, Gastric LN (2016)	CT: Diffuse wall thickening in the 6 cm segment in distal esophagus EF: Lesion starting from Z line and extending to proximal and partially occluding the lumen (EGJ tm?) Other gastric areas; Normal				5. year	Ex after 1 year	Distal esophagectomy+ subtotal gastrectomy	Esophagus SCC (2016)
8	IDC	Stomach (2018) Liver (2018)	PET/CT: Focal increased FDG uptake in gastric wall EF: Hyperemic and ulcerated area in gastric antrum	60	0	0	2. year	Ex after 1 year	None	
*9	ILC	Stomach (2018) Bone (2018)	EF: Milimetric erosions, edema and hyperemia in gastric antrum	70	0	0	1. year	Alive	*	

IDC: Invasive ductal carcinoma, ILC: Invasive lobular carcinoma, ER: Estrogen receptor, PR: Progesterone receptor, YM: Years of metastasis, SM: Survi of metastasis, LN: Lymph node, PET/CT: Positron Emission Tomography/Computarized Tomography, EF: Endoscopic findings, FDG: Fluorodeoxyglucose, CT: Computarized Tomography, USG: Ultrasonography, EGJ: Esophagogastric junction, SCC: Squamous cell carcinoma, *Consultation cases

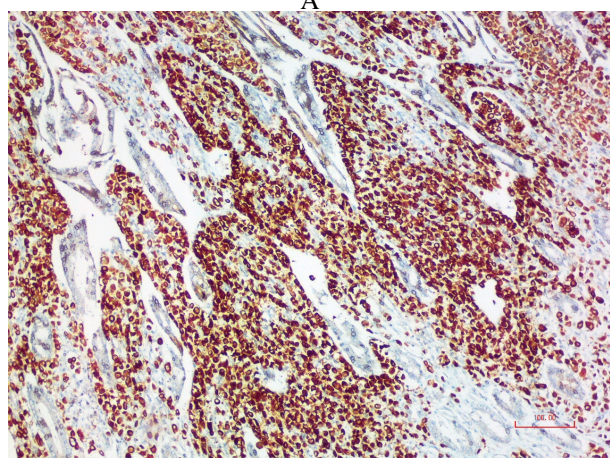
Table 3. Hormone receptor expressions detected in primary tumor focus and metastatic focus

	Primary tumor focus GIS N	%	Gallbladder N	%	Metastatic Focus GIS N	%	Gallbladder N	%	
Histological subtype	IDC	5	0		5		0		
	ILC	2	2		2		2		
Hormone receptors	ER+	6*	(100)	1*	(100)	6*	(85.7)	2*	(200)
	ER-					1	(14.3)	0	
	PR+	4*	(66.7)	1*	(100)	1	(14.3)	2*	(100)
	PR-	2	(33.3)			6*	(85.7)	0	
	CerbB2+	0		0		0		0	
	CerbB2-	6*	(100)	1*	(100)	7*	(100)	2*	(100)

IDC: Invasive ductal carcinoma, ILC: Invasive lobular carcinoma, ER: Estrogen receptor, PR: Progesterone receptor, GIS: Gastrointestinal system, N: Noun, *Since two cases were consultations, ER, PR and CerbB2 expression results in primary focus could not be obtained



A



B

Figure 2. Invasive lobular carcinoma metastasis in small intestine tissue a: Full-thickness infiltration by tumor cells (H&E, x40) b: CK7 expression on tumor cells (x100)

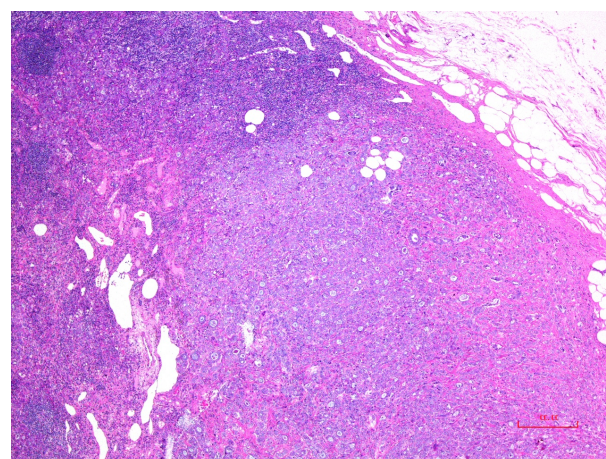


Figure 3. Invasive ductal carcinoma metastasis in lymph node on gallbladder. Tumor tissue that removes the normal structure of the lymph node (H&E, x40)

a lobular carcinoma morphology are observed more frequently (1, 2, 5). In the largest autopsy series, ILC rate was 4.5%, while IDC was 0.2% (15). Although the exact cause is not known, it is emphasized that the loss of E-cadherin, the intercellular adhesion molecule, may be responsible for ILC metastases. In our study, contrary to the literature, the cases diagnosed with IDC metastasized to GIS more frequently. The fact that our ILC cases were less than the number of IDCs might be the reason for this result.

Breast carcinoma metastasis in the gallbladder is extremely rare. It is often included in the literature as case reports (12, 16, 17). In one of the autopsy studies, it was reported that the rate of metastatic tumor in the gallbladder was lower than 6%, and within this group, breast tumor metastases were 4-7% (4, 12, 18). Signs such as pain, cholecystitis, cholelithiasis or obstructive jaundice were observed (12, 16, 18). As for our study, one of our patients had cholelithiasis and related symptoms. Since the other case was sent for consultation, informa-

tion on clinical findings was not available. In the literature, IDC was more common in gallbladder metastases compared to ILC (17, 18). Our study was compatible with the literature and both of our cases were IDC. In one case, metastasis was observed in the lymph nodes in the neck region, while in the other, a full-thickness tumoral infiltration was observed in the gallbladder wall. Immunohistochemical analysis has an important role in the differential diagnosis of primary and metastatic tumors. Studies have reported that ER may be negative in some breast tumors and positive in some gastric tumors (19, 20). For this reason, additional IHC markers such as GCDFP-15, GATA-3 or mammoglobin, which have high sensitivity and specificity, should be used for precise diagnosis (21). In our study, positivity was found for IHC markers as GCDFP-15, GATA3, CK7 and mammoglobin, performed to support breast tumor metastasis besides ER, PR and *cerbB2*. Discordance of hormone receptors between primary and metastatic foci during progression of the breast tumor is important, because it shapes the treatment. Especially in hormone receptors, up to 40% discordance have been reported (22), most of which are in the form of expression loss and may indicate a progression to a more aggressive type (22). However, there are also studies reporting an expression gain (23, 24). The mechanisms responsible for discordance are intratumoral heterogeneity, genetic shift during tumor progression or clonal selection as well as technical reasons for evaluating biopsy results (tumor sampling, tissue fixation, IHC study). While it has been reported to be associated with poor survival rates in some of the retrospective studies, the reason for this poor outcome has not been clarified in a prospective study (25). However, especially patients with ER expression gain in metastases can benefit from endocrine treatment, and thus, show a better prognosis. In our study, in patients with GIS metastasis, there was a difference between primary and metastatic foci in terms of ER and PR expression rates. The difference was in the form of expression loss and was detected in four cases with IDC who metastasized to GIS. In the other cases, a decrease, a slight increase or similar expressions were observed in hormone receptors. Treatment in metastatic breast tumor will be systemic chemotherapy and/or endocrine therapy (5, 6). Surgery can often be required for the diagnosis and treatment of complications such as bleeding or intestinal obstruction (26). In our study, small bowel resection was performed due to ileus in our ILC case with metastasis to the small intestine and sigmoid colon.

The metastatic spread of the breast tumor may be synchronous or may occur many years after the diagnosis of primary tumor. In the literature, there are cases with metastases occurring even after 30 years (3, 27). Metastasis to gallbladder was reported to vary between 18 months and 10 years (6). In our study, the time to metastases in GIS varied between 1 and 18 years, while in the patients who metastasized to the gallbladder, it was four years.

The prognosis is quite poor in metastatic patients and in most patients, the mean survival was reported to be 1 or 2 years (5, 26, 28). In our study, the results were similar to those in the literature. All the patients had died except the IDC with gallbladder metastasis and ILC with gastric metastasis.

Limitations

The limitations of our study were the small sample size and not being able to access to some of the data in two cases sent to our clinic for consultation.

Conclusion

In conclusion, breast tumors are mostly expected to metastasize to lymph nodes, chest wall, bone, lung and liver. Since it will have an impact on differential diagnosis and treatment of tumors with an unknown primary, it should be borne in mind that although less frequently, breast tumors might metastasize to gastrointestinal tract and gallbladder.

Ethical Approval

This study was approved by the Ethics Committee of the Okmeydani Education and Research Hospital, Istanbul, Turkey (2017/514/118/8)

References

1. Cummings MC, Simpson PT, Reid LE, et al. Metastatic progression of breast cancer: Insights from 50 years of autopsies. *J Pathol* 2014;232:23-31.
2. Allison KH, Brogi E, Ellis IO, et al. Epithelial tumours of the breast. WHO classification of tumours editorial board. *Breast Tumours*. 5th ed. Lyon: World Health Organization; 2019.p.9-159.
3. Nazareno J, Taves D, Preiksaitis HG. Metastatic breast cancer to the gastrointestinal tract: A case series and review of the literature. *World J Gastroenterol* 2006;12:6219-24.
4. Riaz N, Ahmed R, Afzal S, Masood N. Breast carcinoma with asymptomatic metastasis to the gallbladder. *Singapore Med J* 2012;53:e136-8.
5. Taal BG, Peterse H, Boot H. Clinical presentation, endoscopic features, and treatment of gastric metastases from breast carcinoma. *Cancer* 2000;89:2214-21.
6. Zagouri F, Sergeantanis TN, Koulocheri D, Nonni A, Bousiotou A, Domeyer P, et al. Bilateral synchronous breast carcinomas followed by a metastasis to the gallbladder: A case report. *World J Surg Oncol* 2007;5:101.
7. Lin L, Wang X, Tang C, Liang J. Clinical characteristics and prognosis of gastrointestinal metastases in solid tumor patients: A retrospective study and review of literatures. *Anal Cell Pathol* 2019;2019:4508756.
8. Weigt J, Malfertheiner P. Metastatic disease in the stomach. *Gastrointest Tumors* 2015;2:61-4.
9. Bento LH, Minata MK, Batista CP, et al. Clinical and endoscopic aspects of gastrointestinal metastases to the gastrointestinal tract. *Endoscopy* 2019;51:646-52.
10. Almubarak MM, Laé M, Cacheux W, et al. Gastric metastasis of breast cancer: A single centre retrospective study. *Dig Liver Dis* 2011;43:823-7.
11. DiVita M, Zanghì A, Lanzafame S, et al. Gallbladder metastases of breast cancer: from clinical- pathological patterns to diagnostic and therapeutic strategy. *Clin Ter* 2011;162:451-6.
12. Markelov A, Taheri H, Vunnamadala K, Ibrahim G. Biliary dyskinesia as a rare presentation of metastatic breast carcinoma of the gallbladder: A case report. *Case Rep Pathol* 2011; 2011:806570
13. He H, Gonzalez A, Robinson E, Yang WT. Distant metastatic disease manifestations in infiltrating lobular carcinoma of the breast. *Am J Roentgenol* 2014;202:1140-8.
14. Pectasides D, Psyrrì A, Pliarchopoulou K, et al. Gastric metastases originating from breast cancer: Report of 8 cases and review of the literature. *Anticancer Res* 2009;29:4759-63.
15. Borst MJ, Ingold JA. Metastatic patterns invasive lobular versus invasive ductal carcinoma of the breast. *Surgery* 1993;114:637-41.
16. Shah RJ, Koehler A, Long JD. Bile peritonitis secondary to breast cancer metastatic to the gallbladder. *Am J Gastroenterol* 2000;95:1379-81.
17. Mouchli M, Grider DJ, Yeaton P. Gallbladder Metastases: A Report of Two Cases. *Case Rep Oncol* 2019;12:235-40.
18. Urade T, Oka S, Iimori S, Man-I M, Abe T, Sawa H, et al. A resected case of gallbladder metastasis with symptoms of acute cholecystitis in multiple metastatic ductal carcinoma of the breast. *Clin J Gastroenterol* 2019;12:52-6.
19. Xu CY, Guo JL, Jiang ZN, Xie SD, Shen JG, Shen JY, et al. Prognostic role of estrogen receptor alpha and estrogen receptor beta in gastric cancer. *Ann Surg Oncol* 2010;17:2503-9.
20. Yip CH, Rhodes A. Estrogen and progesterone receptors in breast cancer. *Future Oncol* 2014;10:2293-301.
21. Zaha DC. Significance of immunohistochemistry in breast cancer. *World J Clin Oncol* 2014;5:382-92.
22. Curtit E, Nerich V, Mansi L, et al. Discordances in estrogen receptor status, progesterone receptor status, and HER2 status between primary breast cancer and metastasis. *Oncologist* 2013;18:667-74.

23. Lower EE, Glass EL, Bradley DA, et al. Impact of metastatic estrogen receptor and progesterone receptor status on survival. *Breast Cancer Res Treat* 2005;90:65-70.
24. Guarneri V, Giovannelli S, Ficarra G, et al. Comparison of HER-2 and hormone receptor expression in primary breast cancers and asynchronous paired metastases: Impact on patient management. *Oncologist* 2008;13:838-44.
25. Amir E, Miller N, Geddie W, et al. Prospective study evaluating the impact of tissue confirmation of metastatic disease in patients with breast cancer. *J Clin Oncol* 2012;30:587-92.
26. Ambroggi M, Stroppa EM, Mordenti P, et al. Metastatic breast cancer to the gastrointestinal tract: Report of five cases and review of the literature. *Int J Breast Cancer* 2012;2012:439023.
27. Shakoor MT, Ayub S, Mohindra R, et al. Unique presentations of invasive lobular breast cancer: A case report. *Int J Biomed Sci* 2014;10:287-93.
28. Noor A, Lopetegui-Lia N, Desai A, et al. Breast Cancer Metastasis Masquerading as Primary Colon and Gastric Cancer: A Case Report. *Am J Case Rep* 2020;21:e917376.