



Kimmerle's Anomaly: Posterior Osseous Bridging of Atlas

Deniz Senol, Mustafa Canbolat, Sumeyye Ulutas, Mahmut Cay, Songul Cuglan, Evren Kose, Davut Ozbag

Department of Anatomy, Inonu University Faculty of Medicine, Malatya, Turkey

Abstract

Kimmerle's anomaly is a rare and serious pathology of the 1st cervical vertebra, which may sometimes lead to hardly explicable changes in vertebrobasilar circulation. Also known as ponticulus posticus (PP), this phenomenon encircles the vertebral artery and suboccipital nerve and is associated with vertigo, vertebro-basilar insufficiency, neck pain, shoulder pain and cervicogenic headache symptoms. It can also lead to migraine as a result of its interaction with dura. As the knowledge of this variant by clinicians is important for obtaining a fast result in the treatment, it should also be taken into account in surgical approaches so as not to harm the vessels and nerves in this area.

Keywords: Anomaly, ponticulus posticus, Kimmerle, atlas

(Rec.Date: Sept 30, 2015 Accept Date: Dec 07, 2015)

Corresponding Author: Deniz Senol, Department of Anatomy, Inonu University Faculty of Medicine, Malatya, Turkey

E-mail: deniz.senol@inonu.edu.tr

Introduction

In human atlas vertebrae, there is sulcus arteriae vertebralis through which vertebral artery and the posterior branch of C-1 spinal nerve pass beside superior articular process of vertebrae and it is situated just on the side of the lateral mass of the atlas. In some cases, this groove turns into a foramen by abnormal ossification and the frequency of incidence in human beings varies by race [1]. Though this abnormal phenomenon had many different names such as ponticulus posticus (PP), foramen atlantoideum posterius/vertebrale, foramen retroarticular superior, foramen arcuate, the most common name used by clinicians is "Kimmerle's Anomaly". It is thought that this case occurs as a regressive and morphological phenomenon and as a result of the ossification of atlanto-occipital membrane [2,3]. However, it is known that this anomaly is not commonly seen among the elderly though the ossification of the ligamentum tends to increase with aging [4,5].

Case presentation

Kimmerle's Anomaly was found in 3 different atlases during the routine anatomy practice within the scope of medical education. In one of these atlases, bilateral and total (Figure 1) anomaly was discovered while in another, the anomaly was unilateral (left) and partial (Figure 2). As for the third one, it was unilateral (left) and tunnel-shaped (Figure 3 and 4).



Figure 1. Bilateral and total Kimmerle's Anomaly. (1: Bony bridge PP joins arcus posterior atlantis and lateral mass of the atlas, 2: Canalis arteriae vertebralis, 3: Proc. art. superior, 4: Tuberculum posterius, 5: For. transversarium)



Figure 2. Unilateral and partial Kimmerle's Anomaly. (1: Ponticulus posticus, 2: Arcus posterior atlantis, 3: Proc. art. superior; 4: Fovea dentis; 5: For. transversarium; 6: Proc. Transversus)



Figure 3. Unilateral and tunnel-shaped Kimmerle's Anomaly. (1: Ponticulus posticus, 2: Lateral view of the tunnel-shape, 3: For. transversarium, 4: Proc. art. superior, 5: Proc. transversus)

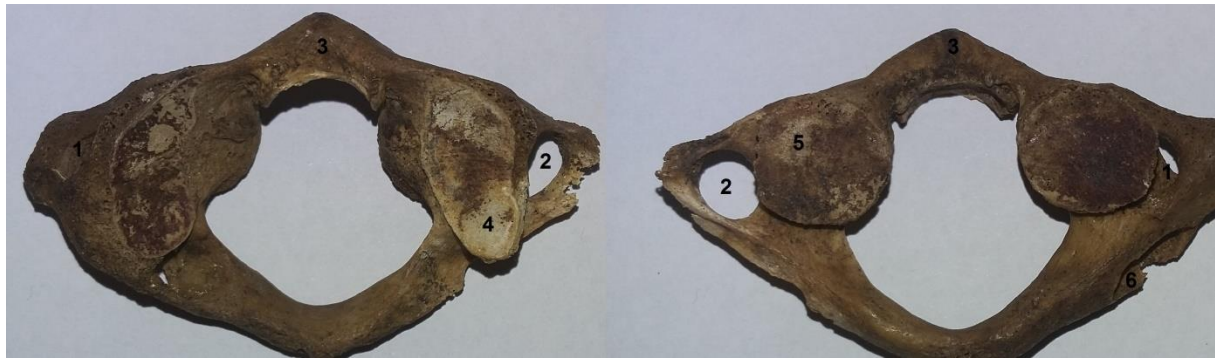


Figure 4. 1: Top (left) and base (right) views of the unilateral and tunnel-shaped Kimmerle's Anomaly. It is seen that the right and left foramen transversaria are asymmetrical and the right for. transversarium looks fairly narrow from the left. (1: Left for. transversarium, 2: Right for. transversarium, 3: Arcus ant. atlantis, 4: Proc. art. superior, 5: Facies art. inferior, 6: Base view of the tunnel-shape)

Table 1. Some length measurements taken from the atlas vertebrae diagnosed with Kimmerle's Anomaly

Parameter	Bilateral and Complete (mm)	Unilateral and Partial (mm)	Unilateral and Tunnel (mm)
T-Leg.	79,8	80,1	64,9
Ant-Post Leg.	46,8	50,0	39,5
FAS Ant-Post Leg	25,0	28,3	21,4
FAS T- Leg.	16,9	11,9	10,8
FV Ant-Post Leg.	33,6	32,3	26,4
FV T- Leg.	31,0	31,2	25,6
L-CAV Sup-Inf D.	6,4	-	4,7
L-CAV Ant-Post D.	5,8	-	5,8
R-CAV Sup-Inf D.	6,8	-	-
R-CAV Ant-Post D.	7,0	-	-
L-PP Th.	1,4	1,9	1,3
R-PP Th.	1,4	-	-
L-FT Ant-Post Leg.	8,8	7,8	6,5
L-FT T- Leg.	8,4	6,3	5,1
R-FT Ant-Post Leg.	8,3	7,7	8,7
R-FT T-Leg.	6,7	6,8	5,9

T-Leg.: Transvers Length, **Ant-Post Leg.:** Anterior Posterior Length, **FAS:** Facies Art. Superior, **FV:** Foramen vertebrale, **L-CAV Sup-Inf D.:** Left Canalis Arteria Vertebralis Superior Inferior Diameter, **R-CAV Sup-Inf D.:** Right Canalis Arteria Vertebralis Superior Inferior Diameter, **L-PP Th.:** Left Ponticulus Posticus Thickness, **R-PP Th.:** Right Ponticulus Posticus Thickness; **L-FT:** Left Foramen Transversarium, **R-FT:** Right Foramen Transversarium

Discussion

Ponticulus posticus' encircling the vertebral artery and suboccipitalis nerve may lead to vertigo, vertebro-basilar insufficiency, neck pain, shoulder pain and cervicogenic headache [6,7]. In some studies, it is indicated that injuries may be caused during the curling of the vertebral artery on the lateral mass, in the presence of PP [8-11]. In the atlanto-occipital area dissection studies by Lamberty and Zivanovic [11], it was seen that the ponticulus posticus and membrane atlanto-occipitalis were bound together tightly while this membrane was tied to dura [1,3]. Some dural stretches may result in severe headaches, a type of migraine [13]. It is very reasonable that the mechanical function disorder in atlanto-occipital joint cause dural stretch which is a very common cause in migraine onset. It was demonstrated that the ischemic compression caused by PP led to basilar insufficiency symptoms [15] and it was determined that the surgical treatment of PP occlusion declined the incidence of these symptoms [14-16]. It is possible that the surgical excision of PP return the blood flow to normal and later, the symptoms are alleviated. It is considered that the spinal manipulation performed on art. atlantooccipitalis alleviate the symptoms of vertigo, headache and nausea. Though these symptoms are assumed to be of vertebrogenic proprioceptive origin, it is indicated that they come out as a result of the vertebral artery's being triggered by functional joint disorder especially in patients with PP [17]. The injury of the vertebral artery during the surgery may cause a catastrophic intraoperative hemorrhage and this dangerous blood flow may cause a non-predictable neurological damage depending on the sufficiency of the blood flow from the collateral vertebral artery [18]. In order to reduce the possibility of the incidence of this damage, some surgeons recommend performing the beginning steps in surgical operations in C1 from different directions [19, 20]. However, some researchers think that PP (the bony bridge) will reduce the risk of injury in the vertebral artery as it serves as a protective barrier. However, taking the atlas as the starting point, in the presence of this anomaly, in the interventional steps to be taken in vertebrae may be dangerous, thus any operation to be performed in this area should start from a different point [21].

The present study explores the Kimmerle's Anomaly and the clinical situations it may cause. The results coming out with the presence of PP highlight the clinical and surgical importance of this anomaly. The knowledge of this variation by clinicians and their considering the fact

that it might be seen in a patient with the abovementioned symptoms are considerably important for getting quick results in the treatment.

Conflict of Interests

The authors hereby declare that they have no competing interests.

References

1. Pait TG, Arnautovic KI, Borba LAB. The anatomy of the atlantoaxial complex. *Neurological Surgery*. 1997;7(1):91-8.
2. Koutsourakia E, Avdelidia E, Michmizosa D, Kapsalia SE, Costaa V, Baloyannisa S. Kimmerle's Anomaly as a Possible Causative Factor of Chronic Tension-Type Headaches and Neurosensory Hearing Loss: Case Report and Literature Review. *International Journal of Neuroscience*. 2010;120(3):236-9.
3. Wight S, Osborne N, Breen AC. Incidence of Ponticulus Posterior of the Atlas in Migraine and Cervicogenic Headache. *Journal of Manipulative and Physiological Therapeutics*. 1999;22(1):15-20.
4. Lamberty BHG, Zivanovic S. The retro-articular vertebral artery ring of the atlas and its significance. *Acta Anat*. 1973;85(1):113-22.
5. Stubbs DM. The arcuate foramen: variability in distribution related to race and sex. *Spine*. 1992;17(12):1502-4.
6. Tubbs RS, Johnson PC, Shoja MM, Loukas M, Oakes WJ. Foramen arcuale: anatomical study and review of the literature. *J Neurosurg Spine*. 2007;(1):31-4.
7. Chitroda PK, Katti G, Baba IA, Najmudin M, Ghali SR, Kalmath B, et al. Ponticulus posticus on the posterior arch of atlas, prevalence analysis in symptomatic and asymptomatic patients of gulbarga population. *J Clin Diagn Res*. 2013; (12):3044-7.
8. Elgafy H, Pompo F, Vela R, Elsamaloty HM. Ipsilateral arcuate foramen and high-riding vertebral artery: implication on C1-C2 instrumentation. *Spine J*. 2014;14(7):1351-5.
9. Ahmad FU, Wang MY. Lateral mass of C1 fixation and ponticulus posticus. *World Neurosurg*. 2014;82(1-2):e145-6.
10. Gebauer M, Barvencik F, Briem D, Kolb JP, Seitz S, Rueger JM, et al. Evaluation of anatomic landmarks and safe zones for screw placement in the atlas via the posterior arch. *Eur Spine J*. 2010;19(1):85-90.
11. Lamberty BHG, Zivanovic S. The retro-articular vertebral artery ring of the atlas and its significance. *Acta Anat*. 1973;85(1):113-22.
12. Young JP, Young PH, Ackermann MJ, Anderson PA, Riew KD. The ponticulus posticus: implications for screw insertion into the first cervical lateral mass. *J Bone Joint Surg Am*. 2005;87(11):2495-8.

13. Wolff S. Headache and other head pain. 7th edition. Oxford University Press. New York, 1972:62-71.
14. Li S, Li W, Sun J. Operative treatment for cervical vertigo caused by foramen arcuale. *Chung Hua Wai Ko Tsa Chih.* 1995;33(3):137-9.
15. Barsukov SF, Grishin GP. The vertebrobasilar blood circulation of the brain in the presence of Kimmerle's anomaly. *Voen Med Zh.* 1991(6):42-5.
16. Bernal Sprekelsen M, Hormann K, Weh L. Sudden hearing loss and the cranio-cervical junction. *Ann Otorhinolaringol Ibero AM.* 1990;17:353-68.
17. Vernon H., Dhimi MSI. Vertebrogenic migraine. *J Can Chiropr Assoc.* 1985;29(1):20-4.
18. Serkan Simsek S, Yigitkanli K, Comert A, Acar HI, Seckin H, Er U, Belen D, Tekdemir I, Elhan A. Posterior osseous bridging of C1. *J Clin Neurosci.* 2008;15(6):686-8.
19. Chen JF, Wu CT, Lee SC, et al. Posterior atlantoaxial transpedicular screw and plate fixation. Technical note. *J Neurosurg Spine.* 2005;2(3):386-92.
20. Resnick DK, Benzel EC. C1-C2 pedicle screw fixation with rigid cantilever beam construct: case report and technical note. *Neurosurgery.* 2002;50(2):426-8.
21. Tan M, Wang H, Wang Y, Zhang G, Yi P, Li Z, Wei H, Yang F. Morphometric evaluation of screw fixation in atlas via posterior arch and lateral mass. *Spine (Phila Pa 1976).* 2003;28(9):888-95.