

Laryngotracheal reconstruction of the congenital glotto-subglottic stenosis with autogenous thyroid cartilage interposition: a case report*

Doğuştan glotto-subglottik stenozun otojen tiroit kartilaj interpozisyonu ile larengotrakeal rekonstrüksiyonu: Bir olgu sunumu

Orhan ÖZTURAN,¹ Ahmet KIZILAY,¹ Murat Cem MİMAN,¹
Semih ÖNCEL,² M. Tayyar KALCIOĞLU,¹ Tamer ERDEM¹

Surgical correction of grade III glotto-subglottic stenosis in a two-month-old girl was illustrated in a staged manner. Firstly, a silicone keel was placed via anterior thyrotomy following a tracheotomy. Secondly, laryngotracheal reconstruction was performed by interposing an autogenous thyroid cartilage anteriorly between the edges of the longitudinally divided cricoid cartilage and the upper tracheal rings. A stent was maintained for two months. The glottis and subglottis appeared patent and healed following removal of the stent. A meaningful voice and rather comfortable respiration were observed during a 13-month follow-up. The use of thyroid cartilage autograft offers many advantages in laryngotracheal reconstruction with considerably less technical difficulty.

Key Words: Cartilage/transplantation; laryngeal cartilages/transplantation; laryngeal diseases/surgery/congenital; laryngostenosis/surgery/congenital; tracheal stenosis/surgery; transplantation, autologous.

Grade III doğuştan glotto-subglottik stenozlu iki aylık bir kız bebekte aşamalı cerrahi tedavi uyguladık. İlk aşamada, trakeotomiye takiben anterior tirotomiyoluyla silikon bir kil yerleştirildi. İkinci aşamada, önde ve orta hatta longitudinal olarak kesilen krikoid ve üst trakeal halkaların kenarları arasına otojen tiroit kartilaj greftinin interpozisyonu ile larengotrakeal rekonstrüksiyon yapıldı. İki ay süreyle stent uygulandı. Stentin alınmasını takiben glottis ve subglottisin açık ve iyileşmiş olduğu görüldü. On üç aylık izlem sırasında anlamlı bir ses ve oldukça rahat solunum gözlemlendi. Larengotrakeal rekonstrüksiyonda tiroit kartilaj otogreftinin kullanımı, önemli derecede teknik kolaylıklar yanı sıra birçok avantaj sağlamaktadır.

Anahtar Sözcükler: Kartilaj/transplantasyon; larenjeal kırıkdağlar/transplantasyon; larenjeal hastalıklar/doğuştan/cerrahi; larengostenoz/doğuştan/cerrahi; trakeal stenoz/cerrahi; transplantasyon, otolog.

Laryngeal webs mostly occur at the glottic level and represent a recanalization failure of the larynx during prenatal development, frequently having a

subglottic extension.^[1] Congenital subglottic stenosis is the third most common congenital laryngeal anomaly following laryngomalacia and vocal cord paraly-

- ◆ Departments of Otolaryngology, ¹Medicine Faculty of İnönü University, Malatya; ²Atatürk Training and Research Hospital, İzmir, both in Turkey.
- ◆ Received: November 14, 2001. Accepted for publication: January 15, 2002.
- ◆ Correspondence: Dr. Orhan Özturan, İnönü Üniversitesi, Tıp Fakültesi, KBB Anabilim Dalı, 44300 Malatya, Turkey.
Tel: +90 422 - 341 06 60 / 4602 Fax: +90 422 - 341 07 28
e-mail: orhanent@yahoo.com
- * Presented at the 26th National Congress of Turkish Otorhinolaryngology, Head and Neck Surgery (September 22-26, 2001, Antalya, Turkey).

- ◆ İnönü Üniversitesi Tıp Fakültesi Kulak Burun Boğaz Hastalıkları Anabilim Dalı, Malatya; ²Atatürk Eğitim ve Araştırma Hastanesi Kulak Burun Boğaz Kliniği, İzmir.
- ◆ Dergiye geliş tarihi: 14 Kasım 2001. Yayın için kabul tarihi: 15 Ocak 2002.
- ◆ İletişim adresi: Dr. Orhan Özturan, İnönü Üniversitesi Tıp Fakültesi KBB Anabilim Dalı, 44300 Malatya.
Tel: 0422 - 341 06 60 / 4602 Faks: 0422 - 341 07 28
e-posta: orhanent@yahoo.com
- * 26. Ulusal Türk Otorinolarenoloji ve Baş-Boyun Cerrahisi Kongresi'nde sunulmuştur (22-26 Eylül 2001, Antalya).

sis.^[2] The diagnosis is suspected in a child who presents with an abnormally shaped cricoid, without a previous history of intubation.^[3]

Insertion of a keel between the divided vocal cords is a well-accepted surgical treatment of a glottic web. For subglottic stenosis, laryngotracheal reconstruction has become the standard treatment in the pediatric population. A number of surgical techniques have been developed to deal with this condition. Grafting of the exposed larynx and trachea with cartilage provides healing and a speedy extubation or decannulation. Costal or auricular conchal cartilages have become the most common grafting materials used to expand the airway through open surgical procedures. However, donor site discomfort and morbidity are potential problems when either costal or auricular cartilage is used in laryngotracheal procedures.^[4]

Recently, the beneficial use of autogenous thyroid cartilage graft for the expansion of the subglottic region of the larynx have been demonstrated in animal models.^[5,6] This article presents the application of this technique in an infant with grade III glotto-subglottic stenosis.

CASE REPORT

A two-month-old girl presented with manifestations of aphonia, biphasic stridor, suprasternal retractions, and cyanotic episodes which had made nursing difficult since birth. No history of prescribed medications and intubation were elicited for the mother and the infant, respectively. She was born to consanguineous parents; however, other siblings did not have any evidence of an anomaly. The mother was delivered at 32 weeks of gestation. A complete physical examination was undertaken to exclude any associated anomalies including atrial or ventricular septal defects. Flexible laryngoscopy showed a glottic web along the membranous cord. Tracheotomy was performed at the level of the third tracheal cartilage with a vertical incision under general anesthesia through a face mask. Then, anesthesia was maintained through an intubation tube inserted via tracheotomy. Laryngeal structures were examined by direct laryngoscopy, which revealed a thick web involving 70% of the glottis. The individual vocal folds seemed to undergo fusion. A diagnosis of type III congenital glottic web was made (Fig. 1a).^[1] The glottic web was incised endoscopically with precision prior to an anterior thyrotomy approach. The incision was made in the midline up to the anterior commissure with the use of a microlaryn-

goscopic blade under magnified vision of an operating microscope. During direct laryngeal examination, microscopic and rigid endoscopic views and instrumental manipulation disclosed extension of the glottic web causing subglottic stenosis. Because the glottic web prevented the use of an endotracheal tube through the glottic aperture, a rigid endoscope, 4 mm in diameter, was inserted through glottic webbing to determine the size of the subglottic stenosis. Subglottic airway was assessed as grade III according to the Myer-Cotton's classification system.^[7]

Due to the inherent risks for granulation tissue formation at the glottic level and aspiration, a staged procedure was performed. In the first stage, a Montgomery silicone laryngeal keel (Boston Medical, Westborough, MA, USA) was placed between the divided vocal cords through anterior thyrotomy to provide smooth healing of the glottic web. The intubation tube inserted via tracheotomy was removed and a tracheotomy tube was introduced. Respiration was maintained through this tracheotomy tube for six weeks, with the silicone keel placed between the vocal cords.

In the second stage, the keel was removed externally without reopening the thyroid cartilage at the time of laryngotracheal reconstruction. Direct laryngoscopy showed the separated and healed, but edematous vocal cords (Fig. 1b) and a 75% occlusion of the subglottic space, mostly by cartilaginous shelves anteriorly and laterally (Fig. 2a). A vertical incision was made in the skin over the laryngotracheal structures and the strap muscles were divided along the median raphe. After an adequate exposure, a vertical midline incision was made over the cricothyroid membrane, the cricoid cartilage, and the first two tracheal cartilages extending down to the tracheotomy site. The posterior cricoid plate was also divided in the midline to the posterior perichondrium of the cricoid cartilage with the use of a number 15 blade. Adequate enlargement of the subglottic lumen by anterior and posterior incisions obviated lateral divisions. A fusiform-shaped cartilage graft, 2x1 cm in size, was removed from the superior aspect of the right thyroid lamina (Fig. 3a), with special attention given to leave the inner layer of the perichondrium intact. The outer layer of the perichondrium was harvested with the graft (Fig. 3b). Another piece of cartilage, small in size, was inserted between the divided posterior cricoid plate and was fit flush between the divided posterior cricoid lamina, which was then

fixed with 6-0 Vicryl sutures placed only to the cut ends of the posterior cricoid cartilage plate. The knots were buried under the mucosal layer.

A Montgomery T-tube (Boston Medical, Westborough, MA, USA) with an inner diameter of 6 mm was placed into the lumen. The level of the upper limp was shortened so that it can lie at a lower level than that of the glottis, with the external limp extending out from the tracheotomy site. The harvested thyroid cartilage autograft was interposed between the divided cricoid and upper tracheal cartilages, with the perichondrial layer facing the airway lumen and covering the upper limp of the Montgomery T-tube (Fig. 3b). The graft was fixed in position with the use of 6-0 polypropylene figure-of-8 sutures. The strap muscles were reunited with absorbable sutures in the midline and a contact between the strap muscles and autogenous thyroid cartilage was established. The patient's weight was 5.5 kg at the time of laryngotracheal reconstruction. A circular granulation tissue formation which appeared in the skin surrounding the external limp of the T-tube was treated effectively at two different times by topical application of mitomycin-C (0.4 mg/ml) solution.

After two months, the stent was removed and the patient was intubated via tracheotomy for the final direct laryngoscopic evaluation. The glottis and sub-

glottis appeared patent and healed (Fig. 1b and 2b). The patient was administered cisapride 0.6 mg/kg/daily divided into three doses at approximately equal intervals from the time of diagnosis to six months after the laryngotracheal reconstruction to avoid adverse effects of gastroesophageal reflux on healing. A meaningful voice and rather comfortable respiration were observed during a 13-month follow-up.

DISCUSSION

Congenital subglottic stenosis should be considered in a newborn with no history of airway manipulation.^[8] Subglottic stenosis occurs when the airway lumen of the cricoid region measures less than 4 mm in a full-term infant and 3.5 mm in a preterm infant.^[8] In our case, the airway lumen was 2 mm and was located posteriorly. Not all patients with subglottic stenosis can be managed with a standard treatment plan. Each case must be individually evaluated and the degree of the stenosis, associated laryngotracheal pathologies, such as the congenital glottic web in our case, and the general medical condition of the patient should be considered prior to giving a decision for reconstruction.

Watchful waiting with tracheotomy alone has been advocated by some authors, hoping that a spontaneous growth of the stenotic laryngeal lumen may occur.^[9] This approach may be appropriate for mild

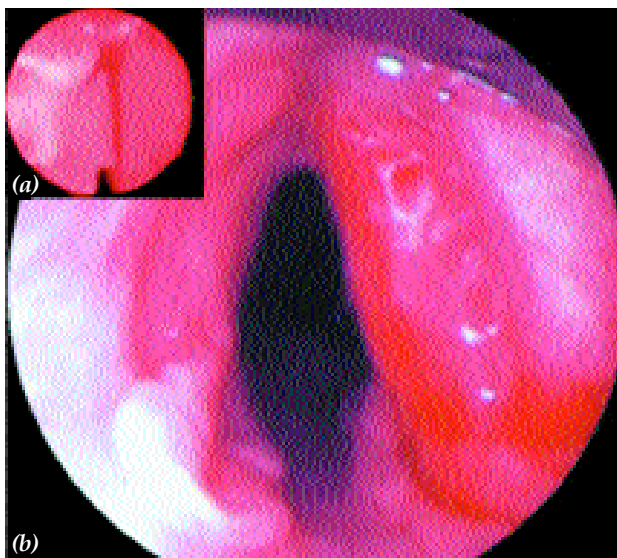


Fig. 1 - (a) Grade III congenital glottic web. Seventy percent of the glottis was involved by a thick web, extending into the subglottis. The individual vocal folds were fused. (b) Direct laryngoscopic view of the separate and healed, but edematous vocal cords.

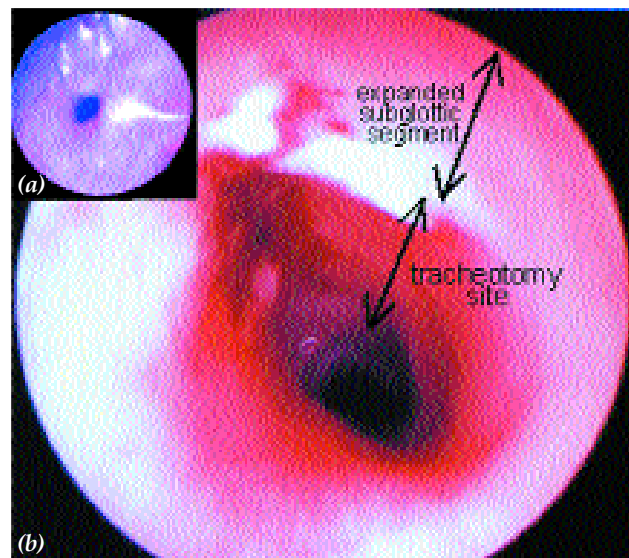


Fig. 2 - (a) Grade III congenital subglottic stenosis. Seventy-five percent of the subglottic space was occluded mostly by cartilaginous shelves anteriorly and laterally. (b) Direct laryngoscopic view of the subglottis right after the removal of the stent.

cases in which growth may be anticipated to create an airway sufficient to meet the needs of the child. However, prolonged tracheotomy is not without problems; it may cause some tracheal damage at the stoma and tip of the tube, and a tracheocutaneous fistula.^[8] Decannulation of the patient is not easy and some problems may arise. The physical and mental dependence makes decannulation difficult.^[8] The existence of a tracheotomy tube can inhibit vocalization and subsequent language development that may also result in decreased efforts for language stimulation by the parents. In addition to these morbid conditions, mortality rates ranging from 6% to 24% have been reported for young children with tracheotomy, whose airway is significantly obstructed above the tube as with in our case.^[10] Thus, it is advised that laryngotracheal reconstruction be performed as early as possible, utilizing surgical techniques that will enable early decannulation.^[11] In our case, we preferred early enlargement surgery to conservative waiting taking into consideration the severity of the subglottic stenosis (grade III), glottic web (grade III), and the inherent risks of the conservative treatment.

Although a minimum of 10 kg body weight is desirable for most children undergoing laryngotra-

cheal reconstruction, this amount seems to be rather arbitrary.^[12] There are no age limitations for laryngotracheal reconstruction, but a minimum weight of 6 kg is needed before surgery.^[13] We had to resort to surgery in our patient at a time her weight was 5.5 kg, little less than the minimum desirable value.

Montgomery T-tubes may be relatively safe in children, providing that both postoperative and home care are meticulously undertaken.^[14] It has the advantage of serving both as a stent and a tracheotomy tube.^[15] The stent was used to minimize the movement of the laryngeal segment induced by normal swallowing, respiration, and daily activities which enhance graft viability and decrease granulation tissue formation.^[12] On the other hand, it has a potential risk for obstruction, especially when the inner diameter is small, as was in our case. Since insertion of a posterior graft shortens the duration for stenting (from 6 months or longer to a 4- to 8-week period)^[16] and because of the potential risk for plugging of the T-tubes having a small diameter, the stent was kept for only two months after surgery. The family was made aware of a possible risk for obstruction and was trained during hospitalization for four weeks following laryngotracheal reconstruction. The external limb of the tube was continuously kept

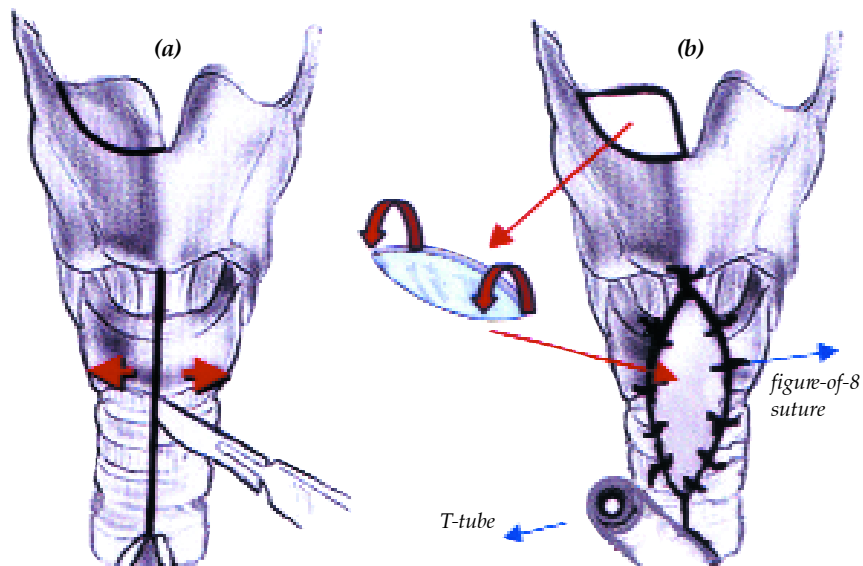


Fig. 3 - (a) A vertical midline incision was made over the cricothyroid membrane, the cricoid cartilage and the upper tracheal rings. A fusiform-shaped cartilage graft was removed from the superior aspect of the right thyroid lamina, leaving the inner layer of perichondrium intact; (b) The thyroid cartilage autograft harvested was placed between the divided cricoid and the upper tracheal cartilages using figure-of-8 sutures, with the perichondrial layer facing the airway lumen and covering the upper limb of the Montgomery T-tube.

plugged to prevent crust formation within the stent lumen, with proper suctioning and humidification. Since the glottic web was treated with a silicone keel and complete healing was obtained, the upper limb of the T-tube was placed below the level of the vocal cords to eliminate the possibility of aspiration and formation of granulation tissue.

Grade III subglottic stenosis usually requires an open intervention to establish an airway sufficient to permit decannulation.^[12] An autologous tissue must be inserted to maintain the structural integrity. The ribs and the auricles are the most commonly used sources for augmentation grafts. Autogenous costal cartilage grafts present both potential morbidity such as pneumothorax and technical difficulty in sewing the graft in the desired position.^[17] On the other hand, harvesting choncal cartilage graft from the auricle may result in donor site deformity and morbidity. In a series of 46 procedures in which auricular choncal grafts were used, occurrence of donor site infection and postauricular keloids were reported in one and two cases, respectively.^[17]

Pedicled thyroid alar cartilage was proposed as a graft material for cricoid expansion, first by Fearon and Cotton.^[18] Although the idea of using a pedicled muscle graft with its own blood supply and mucoperichondrium is attractive, it may not prove to be a good surgical choice due to small size of the structures.

Autogenous thyroid cartilage was utilized in animal models for laryngotracheal reconstruction, with comparable advantages to those of auricular and costal cartilage grafts, including viability of the thyroid cartilage, need for a single incision and a single operative site.^[5,6] In addition, the thickness of the superior thyroid cartilage is almost identical to that of the cricoid cartilage, which decreases the possibility of graft prolapse into the airway. The thyroid cartilage is firm and it can easily be carved and shaped.^[6] Its outer aspect covered by the perichondrium can be positioned facing the lumen, providing a convenient surface for epithelization that can eliminate granulation tissue formation, preventing graft infection, and improving survival of the cartilage graft.^[19] A contact area with the strap muscles is established, providing a bridge for nutrients to the graft.^[12] During the procedure, extreme care is necessary to ensure a single needle pass through the graft to avoid necrosis of the cartilage along the suture tracts.^[20] With an appropriate technique and precautions, no complications

including graft failure or migration, pneumonia, pneumothorax, wound infection or seroma, or subcutaneous emphysema occurred in our case.

Possible disadvantages of the thyroid cartilage graft include limitations such as that related to the size of the graft, the likelihood of destabilization of the laryngeal skeleton, and altered growth of the thyroid lamina. We did not observe donor site morbidity in our patient up to 13 months after surgery. The graft was well-secured with figure-of-8 sutures of 6-0 polypropylene monofilament, keeping the knots away from the respiratory lumen. This type of suture prevented the graft and laryngotracheal structures from moving in a telescopic manner, a point which has not hitherto been mentioned. There are concerns regarding the strength of the thyroid cartilage following graft removal and the effect on subsequent laryngeal growth. Park and Forte^[5] showed in kittens that removal of the superior portion of the thyroid alar cartilage had no apparent effect on subsequent laryngeal growth and stability. Conversely, the inner perichondrium of the thyroid cartilage should be preserved at the donor site for its potential to induce new cartilage generation.

In conclusion, the use of thyroid cartilage autograft for laryngotracheal reconstruction in our patient enabled successful decannulation. This technique proved useful and provided many advantages such as a single operation site, minimal graft remodelling, convenient size, shape, and ease in trimming and suturing the cartilage graft to laryngotracheal structures, and significantly less technical difficulty in obtaining the graft. This technique was first described by Park and Forte^[5] and de Jong et al.^[6] for laryngotracheal reconstruction in animal models. We demonstrated that it may also be employed in an infant with a stenotic airway. The lack of the need for additional incisions and operation site, and fewer potential complications are obvious benefits of the thyroid cartilage graft in comparison with the use of auricular or costal cartilage grafts. Yet, the use of the autogenous thyroid cartilage graft technique should be validated by further studies in cases with acquired stenosis.

REFERENCES

1. Cotton RT, Prescott CA. Congenital anomalies of the larynx. In: Cotton RT, Myer CM, editors. Practical pediatric otolaryngology. 1st ed. Philadelphia: Lippincott-Raven; 1999. p. 497-513.
2. Sichel JY, Dangoor E, Eliashar R, Halperin D.

- Management of congenital laryngeal malformations. *Am J Otolaryngol* 2000;21:22-30.
3. Hartley BE, Cotton RT. Paediatric airway stenosis: laryngotracheal reconstruction or cricotracheal resection? *Clin Otolaryngol* 2000;25:342-9.
 4. Lusk RP, Kang DR, Muntz HR. Auricular cartilage grafts in laryngotracheal reconstruction. *Ann Otol Rhinol Laryngol* 1993;102(4 Pt 1):247-54.
 5. Park AH, Forte V. Effect of harvesting autogenous laryngeal cartilage for laryngotracheal reconstruction on laryngeal growth and support. *Laryngoscope* 1999; 109(2 Pt 1):307-11.
 6. de Jong AL, Park AH, Raveh E, Schwartz MR, Forte V. Comparison of thyroid, auricular, and costal cartilage donor sites for laryngotracheal reconstruction in an animal model. *Arch Otolaryngol Head Neck Surg* 2000; 126:49-53.
 7. Myer CM 3rd, O'Connor DM, Cotton RT. Proposed grading system for subglottic stenosis based on endotracheal tube sizes. *Ann Otol Rhinol Laryngol* 1994; 103(4 Pt 1):319-23.
 8. Lesperance MM, Zalzal GH. Assessment and management of laryngotracheal stenosis. *Pediatr Clin North Am* 1996;43:1413-27.
 9. Holinger PH, Kutnick SL, Schild JA, Holinger LD. Subglottic stenosis in infants and children. *Ann Otol Rhinol Laryngol* 1976;85(5 Pt.1):591-9.
 10. Cotton RT, Gray SD, Miller RP. Update of the Cincinnati experience in pediatric laryngotracheal reconstruction. *Laryngoscope* 1989;99:1111-6.
 11. Zalzal GH. Treatment of laryngotracheal stenosis with anterior and posterior cartilage grafts. A report of 41 children. *Arch Otolaryngol Head Neck Surg* 1993;119:82-6.
 12. Willging JP, Cotton RT. Subglottic stenosis in the pediatric patient. In: Myer CM, Cotton RT, Shott SR, editors. *The pediatric airway. An interdisciplinary approach*. 1st ed. Philadelphia: JB Lippincott; 1995. p. 111-32.
 13. Cotton RT, Evans JN. Laryngotracheal reconstruction in children. Five-year follow-up. *Ann Otol Rhinol Laryngol* 1981;90(5 Pt 1):516-20.
 14. Stern Y, Willging JP, Cotton RT. Use of Montgomery T-tube in laryngotracheal reconstruction in children: is it safe? *Ann Otol Rhinol Laryngol* 1998;107:1006-9.
 15. Montgomery WW, Montgomery SK. Manual for use of Montgomery laryngeal, tracheal, and esophageal prostheses: update 1990. *Ann Otol Rhinol Laryngol Suppl* 1990;150:2-28.
 16. Choi SS, Zalzal GH. Pitfalls in laryngotracheal reconstruction. *Arch Otolaryngol Head Neck Surg* 1999;125: 650-3.
 17. Silva AB, Lusk RP, Muntz HR. Update on the use of auricular cartilage in laryngotracheal reconstruction. *Ann Otol Rhinol Laryngol* 2000;109:343-7.
 18. Fearon B, Cotton R. Surgical correction of subglottic stenosis of the larynx. Preliminary report of an experimental surgical technique. *Ann Otol Rhinol Laryngol* 1972;81:508-13.
 19. Zalzal GH, Cotton RT, McAdams AJ. The survival of costal cartilage graft in laryngotracheal reconstruction. *Otolaryngol Head Neck Surg* 1986;94:204-11.
 20. Cotton RT. The problem of pediatric laryngotracheal stenosis: a clinical and experimental study on the efficacy of autogenous cartilaginous grafts placed between the vertically divided halves of the posterior lamina of the cricoid cartilage. *Laryngoscope* 1991;101(12 Pt 2 Suppl 56):1-34.