



Jeune Syndrome (Asphyxiating Thoracic Dystrophy)

Ozgu Suna Celiloglu*, Metin Dogan**, Muharrem Ak***, Derya Gumus Dogan*,
Can Celiloglu*, Ahmet Sigirci**, Ahmet Karadag*

*Inonu University School of Medicine, Department of Pediatrics, Malatya

**Inonu University School of Medicine, Department of Radiology, Malatya

***Inonu University School of Medicine, Department of Family Medicine, Malatya

Jeune syndrome, otherwise called as “asphyxiating thoracic dystrophy” (ATD) is a rare autosomal recessive inherited chondrodysplasia characterized by severely constricted thoracic cage, limb anomalies, respiratory insufficiency and considerable neonatal mortality. Most of the children suffering from this syndrome present severe respiratory insufficiency and need serious ventilatory support during the early infancy period. The syndrome has a wide clinical spectrum including renal dysplasia, retinitis pigmentosa, hepatic and pancreatic fibrosis. Herein we present a neonate who had a prenatal diagnosis of achondroplasia, showed serious respiratory insufficiency postnatally and was diagnosed as Jeune syndrome.

Key Words: Jeune Syndrome; Asphyxiating Thoracic Dystrophy; Newborn.

Jeune Sendromu

Jeune sendromu; diğer adıyla ‘Asfiksik Torasik Displazi’ (ATD) daralmış göğüs kafesi, ekstremitte anomalileri, solunum yetmezliği ve kayda değer yenidoğan mortalitesi ile karakterize otozomal resesif kalıtım gösteren nadir bir kondrodizplazidir. Bu sendrom bulunan çocukların çoğu şiddetli solunumsal yetmezlik gösterir ve erken süt çocukluğu döneminde ciddi ventilatör desteğine ihtiyaç duyabilir. Sendromun renal displazi, retinitis pigmentosa, hepatik ve pankreatik fibrozu içerebilen geniş bir klinik spektrumu mevcuttur. Doğum öncesi akondroplazi tanısı bulunan ve doğum sonrası ciddi solunumsal yetmezlik gösteren ve Jeune sendromu tanısı konulan bir hastayı sunduk.

Anahtar Kelimeler: Akondroplazi; Asfiksik Torasik Displazi; Çocuk; Jeune Sendromu.

Introduction

Jeune syndrome, otherwise called as “asphyxiating thoracic dystrophy” (ATD, MIM 208500) is a multisystemic, autosomal recessively inherited skeletal dysplasia characterized by thoracic anomalies, short-limbed dwarfism, renal and hepatic anomalies.¹ It is estimated to occur in 1 per 100.000-130.000 live births.¹ Radiological findings have an essential role for the diagnosis. Most prominent feature of the syndrome is narrow thoracic cage with short ribs and pulmonary hypoplasia. During the neonatal period, other involvements of the syndrome may not be seen, and cases surviving this period may present with ophthalmological, hepatobiliary, pancreatic and renal manifestations. Currently biochemical or radiological markers for the prenatal diagnosis of the syndrome is missing but prenatal ultrasonographic findings such as thoracic circumference/abdominal circumference and rib cage perimeter/TC ratios may be helpful for describing skeletal anomalies. The most important

factor affecting the prognosis of the syndrome is the degree of thoracic involvement.¹ Herein we present a Turkish newborn with Jeune syndrome in order to keep in mind this rare syndrome among newborns with serious respiratory failure and skeletal anomalies.

Case Report

Female neonate, weighing 2180 grams, was born from 22 years old mother having her first pregnancy. The baby was delivered with cesarean section due to the fetal distress during the 37th gestational week. Following the delivery, the neonate was admitted to neonatal intensive care unit due to respiratory insufficiency. Prenatal history revealed that prenatal period was under supervision of an obstetrician and during the follow-up the baby was suspected to be having achondroplasia and the mother was directed to a perinatal center.

The parents of the case were first degree relatives. The parents and the several relatives of the patient were short heighted but no other risk factors were identified

Başvuru Tarihi: 04.01.2011, Kabul Tarihi: 29.03.2011

regarding the pregnancy. During the prenatal examinations; ultrasound examination made on the 30 week(w) 3day(d) revealed biparietal diameter (BPD) compatible with 33w+6d, abdominal.

circumference (AC) 29w+3w and femur length (FL) compatible with 23w+1d and examinations of the long bone every two weeks were planned. Two weeks after, control BPD was found to be compatible with 31w+4d, AC was 29w+1d, FL 22w+6d, humerus length was 22w+1d, radius length was 24w+5d, ulnar length was 23w+6d, tibia length was 22w+3d, and fibula length was 21w + 4d.

When the baby was born anthropometric measurements were as follows; weight; 2870 grams (g) (50 percentile), height; 43,5 centimeters (cm) (< 3 percentile) and the head circumference was 34 cm (50 percentile). The thoracic circumference/abdominal circumference was 0,8. Body temperature was 36,5 C° Subcutaneous oxygen saturation was 70%. Respiratory rate was 80/min, heart rate was 170 beats/min and arterial tension value was normal.

Narrow, long, bell shaped thoracic cavity, intercostal and subcostal retractions, rhizomelic shortness of the upper and lower extremities, abdominal distention, macrocephalic head size were noted (Figure 1).

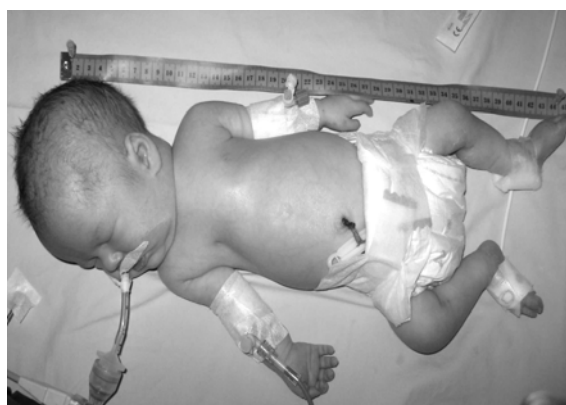

Figure 1. Narrow, long, bell shaped thorax cavity, intercostal and subcostal retractions, rhizomelic shortness of the upper and lower extremities, abdominal distention, macrocephalic head size were noted.

The bilateral lungs were auscultated to be equally participating the respiration effort but fine crackles were extensively positive. The other systemic examinations revealed no positive findings.

Laboratory examinations were as follows; hemoglobin: 19 g/dl, hematocrit: 60%, leukocyte count: $7 \times 10^3/\text{mm}^3$, platelet count: $486,000 \times 10^3/\text{mm}^3$. Hepatic and renal function tests, C-reactive protein, calcium and other serum electrolytes, serum bilirubin,

total protein, albumin levels, urinary analysis, arterial blood gases were within physiological ranges.

During the radiological examinations, thorax x-ray showed narrow thoracic cavity and short ribs (Figure 2).

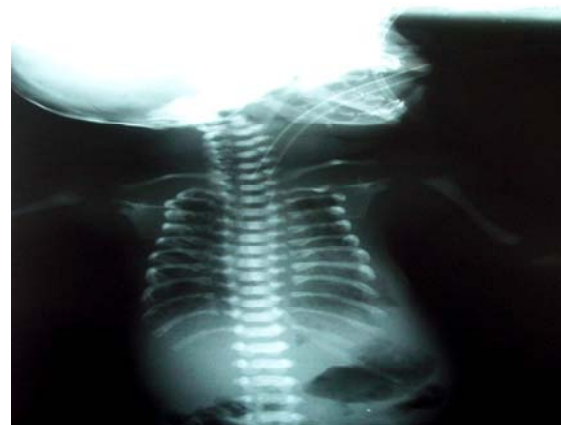


Figure 2. During the radiological examinations, thorax x-ray showed narrow thoracic cavity and short ribs.

Antero-posterior pelvic x-ray revealed hypoplastic iliac wings, narrowed sacrosiatic notches, dysplastic (trident) acetabular roofs and shallow acetabular angles (Figure 3).

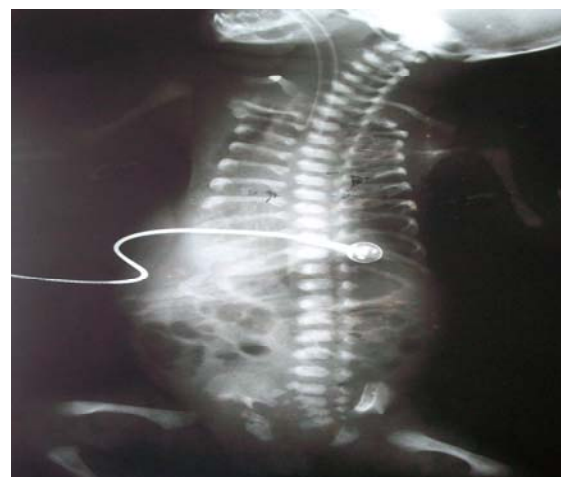

Figure3. Antero-posterior pelvic x-ray revealed hypoplastic iliac wings, narrowed sacrosiatic notches, dysplastic (trident) acetabular roofs and shallow acetabular angles.

The trans-fontanelle ultrasound examination was normal. Abdominal computerized tomography revealed obvious hypodense periportal zones suspecting "lymphatic dilatation", and no other positive findings were obtained. Echocardiography showed pulmonary hypertension secondary to thoracic deformity.

Jeune Syndrome (Asphyxiating Thoracic Dystrophy)

We suspected a skeletal dysplasia because of the thoracic cavity which led to serious respiratory insufficiency and rhizomelic shortness of the upper and lower extremities. Narrow thoracic cavity and short ribs seen on the thorax x-ray (Figure 2) and pelvis x-ray findings of hypoplastic iliac wings, narrowed sacrosciatic notches, dysplastic acetabular roofs and shallow acetabular angles, and absence of polydactyly and absence of cardiac anomalies led us to diagnose the patient as Jeune syndrome.

The newborn was followed for one month with mechanical ventilatory support, and extubation was not possible due to respiratory insufficiency during hospitalization. The patient was given prophylactic antibiotherapy from the first day of admittance but one week after, pneumonia findings were observed and proper antibiotherapy was given but the patient worsened and died due to respiratory insufficiency and pneumonia.

Discussion

Jeune syndrome, otherwise known as “asphyxiating thoracic dystrophy” was first reported in 1955 by Jeune et al. on a newborn with narrow thoracic cavity, multiple cartilage anomalies that died due to respiratory insufficiency during the early neonatal period.² The syndrome is autosomal recessively inherited. Jeune syndrome has no sexual predilections. This rare syndrome is estimated to occur 1 in 100,000-130,000 live births. The number of cases reported up to date is about 100.³

Genetical features of the syndrome are thought to be heterogeneous in nature. Diagnosis is based on clinical and characteristic radiological findings.¹ Typical radiographic findings include a narrow, bell-shaped thorax with short, horizontally oriented ribs and irregular costochondral junctions, elevated clavicles, short iliac bones with a typical trident appearance of the acetabula, relatively short and wide long bones of the extremities, and hypoplastic phalanges of both hands and feet with cone-shaped epiphyses.⁴ Our patient also had a narrow bell shaped thorax, short ribs, hypoplastic iliac wings, trident appearance of the acetabula, and relatively short long bones of the extremities.

During the differential diagnosis, Ellis-van Creveld syndrome, thoracolumbar dysplasia (Barnes syndrome) and short rib polydactyly syndromes should be kept in mind. The phenotypic features of the Jeune syndrome show resemblance with the Ellis-van Creveld syndrome but involvement of the thorax is less pronounced in Ellis-van Creveld syndrome.⁴ Our case presented evident thoracic cavity anomalies.

Characteristics of Ellis-van Creveld syndrome are ectodermal dysplasia, postaxial or axial polydactyly of the hands (constant feature) and sometimes feet, severe hypoplasia of fingers, slanting proximal tibial metaphyses, abnormal shape and size of the carpal bones, and heart defects in up to 50% of cases.⁴ Our case did not have polydactyly or heart defects. The radiographic findings of Jeune syndrome are typical and distinction from the thoracolumbar dysplasia (Barnes syndrome) and short rib polydactyly syndrome is not difficult.⁴ The Jeune syndrome is distinguished from the Barnes syndrome by the different thoracic configuration, the absence of laryngeal stenosis, the presence of iliac spurs in infancy.⁵ Short rib polydactyly syndromes nearly always are associated with polydactyly. In addition, this group of syndromes may be associated with anal atresia, laryngeal and epiglottic anomalies and cleft lip or palate.¹

The small narrow thorax often leads to respiratory distress and recurrent respiratory infections in the neonatal period and infancy. Our patient also showed serious respiratory insufficiency. Respiratory and renal problems are mostly encountered pathologies of the syndrome.⁶ The outcome of Jeune syndrome is reported to be fatal in early childhood.⁴ Patients surviving infancy may develop progressive renal failure later in life.⁴ Hepatic, cardiac, pancreatic and retinal abnormalities and corpus callosum agenesis have also been described.^{1,4} We did not find renal, cardiac, pancreatic or retinal abnormalities in our case. We also did not find any hepatic anomalies but periportal lymphatic dilatation.

At present there is no biochemical or genetic marker, which could be used for prenatal diagnosis of Jeune Syndrome.⁶ Ultrasonography may be used for prenatal diagnosis. Prenatal diagnosis of the Jeune syndrome may be done by ultrasonographic identification of the characteristic skeletal abnormalities during the 14th gestational week of the high risk and 16th gestational week of the low risk pregnant. But the precise prenatal diagnosis is very difficult or impossible.⁴ The thorax circumference/abdominal circumference ratio being less than 0.85 after 18th gestational week is found to be an important marker.¹ In addition, Socolov et al. emphasized that the earliest identifiable change, the shortened long bones is often difficult to notice before 20 weeks, fact which favors a detailed genetic sonogram done after this limit.⁷ Our patient was perinatally suspected to be having achondroplasia due to the relative shortness of the extremities and directed to the perinatal center but during the follow up the thoracic anomaly of the patient was not emphasized and no dysplasia other than achondroplasia was suspected.

Celiloglu ve ark.

The treatment of Jeune syndrome is symptomatic. Children suffering from this syndrome often need serious respiratory support during their first years, but the respiratory problems decrease with age. Serious respiratory insufficiency may necessitate surgical intervention. Several thoracic surgery techniques including lateral thoracic expansion and chest reconstruction were performed but no successful surgical techniques have been described in the literature for neonates.⁸ Renal failure may necessitate renal transplantation or dialysis therapies. Genetical counseling should be given to the parents of the patients.

In conclusion, Jeune syndrome is a rare disease with skeletal anomalies and narrow thoracic cavity presenting mainly with respiratory distress. Jeune syndrome should be kept in mind in patients presenting persistent pulmonary symptoms, thorax deformities and dwarfism.

References

1. Uçar Ş, Zorlu P, Şahin G et al. Jeune sendromu (asfiktik torasik displazi): Olgu sunumu. *Tüberküloz ve Toraks Dergisi* 2009;57(4):413-6.
2. Jeune M, Beraud C, Carron R. Asphyxiating thoracic dystrophy with familial characteristics. *Arch Fr Pediatr* 1955;12(8):886-91.
3. Torbus O, Jachimowicz M, Grzybek H et al. Asphyxiating thoracic dysplasia (Jeune's Syndrome) in 15-years-old boy 6 years of observation. *Wiad Lek* 2002;55:635-43.
4. de Vries J, Yntema JL, van DIE C E, et al. Jeune syndrome: description of 13 cases and a proposal for follow-up protocol. *Eur J Pediatr* 2010;169(1):77-88.
5. Burn J, Hall C, Marsden D et al. Autosomal dominant thoracolyngopelvic dysplasia: Barnes syndrome. *J Med Genet* 1986;23(4):345-9.
6. Verma A. Jeune syndrome. *Indian Pediatr* 2004;41:954-5.
7. Socolov R, Rusu C, Socolov D et al. The prenatal detection of Jeune syndrome (asphyxiating thoracic dystrophy) Case report. *Rev Med Chir Soc Med Nat Iasi* 2006;110(1):144-7.
8. Conroy E, Eustace N, McCormack D. Sternoplasty and rib distraction in neonatal Jeune syndrome. *J Pediatr Orthop* 2010;30(6):527-30.

Corresponding Author: Ahmet KARADAG, M.D

Inonu University School of Medicine,
Division of Neonatology, Department of Pediatrics
44100, MALATYA,
Tel: +904223410660
e-mail: ahmetkaradag@gmail.com