



## Research Article

### Spinal Arachnoiditis and The Axonal Degeneration of The Spinal Nerve Roots Due to Ischemia Induced By Vasospasm: An Experimental Study

Arif ÖNDER<sup>1</sup>, Yurdal SERARSLAN<sup>2</sup>, M. Dumlu AYDIN<sup>3</sup>, Ayhan KANAT<sup>4</sup>, Nesrin GÜRSAN<sup>5</sup>, Coşkun YOLAŞ<sup>6</sup>

<sup>1</sup>Department of Neurosurgery, Avrasya Private Hospital, Zeytinburnu-İstanbul / Turkey

<sup>2</sup>Department of Neurosurgery, Tayfur Ata Sökmen Medical Faculty, Mustafa Kemal University, Hatay, Turkey <sup>3</sup>Department of Neurosurgery, Medical Faculty, Atatürk University, Erzurum, Turkey <sup>4</sup>Department of Neurosurgery, Medical Faculty, Rize University, Rize, Turkey <sup>5</sup>Department of Pathology, Medical Faculty, Ataturk University, Erzurum, Turkey <sup>6</sup>Department of Neurosurgery, Erzurum State Hospital, Erzurum, Turkey

## Summary

**Objective:** Various reasons have been ascribed to arachnoiditis development, among which subarachnoid hemorrhage (SAH) may be an important factor in this process. In this experimental study, we investigated the effect of SAH on histopathological findings. The volumetric changes of the radicular arteries and the density of spinal nerve root axons of a SAH model on C<sub>4</sub> roots in rabbits were measured.

**Materials and Methods:** In this study, 18 rabbits were used. The animals were randomly divided into three groups: subarachnoid hemorrhage (SAH; n = 10), physiologic serum (SF; n = 4) and control (n = 4) groups. SAH was performed by injecting 0.5 cc of blood into cisterna magna taken from their auricular veins. Cervical spinal nerve roots at the C<sub>4</sub> level were examined histopathologically.

**Results:** Meningeal thickening and adhesions, reddish spinal cord and radices were detected macroscopically. Histopathologically, leptomenigeal adhesions, intimal lesions of radicular arteries and axonal injury were detected at the nerve radices. The mean radicular artery volume was found to be low on the arachnoiditis developing animals. The mean alive axon density of the C<sub>4</sub> nerve root decreased and axonal degeneration was observed in the SAH group.

**Conclusion:** Our study suggests that SAH may be an important etiologic factor in spinal arachnoiditis.

**Key words:** Arachnoiditis, axon, nerve root, subarachnoid hemorrhage, vasospasm

### Vazospazmın İndüklediği İskemiye Bağlı Spinal Araknoidit ve Spinal Sinir Köklerinin Aksonal Dejenerasyonu: Deneysel Çalışma

## Özet

**Amaç:** Araknoidit gelişiminde çeşitli nedenler suçlanmaktadır, subaraknoid kanama (SAK) da bu süreçte önemli bir öge olabilir. Bu deneysel çalışmada (tavşan SAK modelinde) SAK'ın histopatolojik bulgular üzerine etkisini, radiküler arterlerin hacimsel değişikliklerini ve C<sub>4</sub> spinal sinir kök aksonlarının dansitesini araştırdık.

**Materyal ve Metot:** Bu çalışmada 18 tavşan kullanıldı. Tavşanlar rastgele üç gruba ayrıldı: subaraknoid kanama (SAK; n = 10), serum fizyolojik (SF; n = 4) ve kontrol (n = 4). SAK, kulak veninden alınan 0.5 ml kanın sisterna magnaya verilmesiyle oluşturuldu. C<sub>4</sub> servikal spinal sinir kökleri histopatolojik olarak incelendi.

**Sonuçlar:** Makroskopik olarak, meningeal kalınlaşma ve yapışıklıklar, kızılımsı spinal kord ve kökler saptandı. Histopatolojik olarak sinir köklerinde, leptomeningeal yapışıklıklar, radiküler arterlerde intimal lezyonlar ve aksonal hasar saptandı. SAK grubunda, radiküler arter ortalama hacmi araknoidit gelişen hayvanlarda düşük olarak bulundu. SAK grubunda, C4 kökünün ortalama canlı akson dansitesinde azalma ve aksonal harabiyet gözlemlendi.

**Yorum:** Çalışmamızın sonuçlarına göre SAK, spinal araknoiditte önemli bir etyolojik etken olabilir.

**Anahtar Kelimeler:** Araknoidit, akson, sinir kökü, subaraknoid kanama, vazospazm

## INTRODUCTION

Arachnoiditis is an inflammatory process resulting in fibrosis and thickening of the leptomeningeal membranes. Severity of the inflammation varies from meningeal adhesions to spinal cord compression. Sensitive and sensorimotor deficits together with neuropsychiatric complaints are the most common symptoms of arachnoiditis<sup>(1)</sup>. Arachnoiditis may lead to sphincter dysfunctions, spastic paresis, plegia, sensory loss and painful syndromes, and spinal cord and nerve root entrapment<sup>(1,16)</sup>.

Subarachnoid haemorrhage (SAH) results in bloody cerebrospinal fluid (CSF)<sup>(16)</sup> and bloody or highly proteinous CSF may lead to neural degeneration<sup>(11)</sup>. Although it has been reported that hemorrhagic arachnoiditis is an infrequent cause of spinal cord dysfunction, however, these findings are not well documented<sup>(9,15)</sup>. Spinal arachnoiditis may develop after trauma, spine surgery, intervertebral disc herniation, intrathecal drug applications, infections and tumors<sup>(5,10)</sup>. SAH is also a cause of spinal arachnoiditis and nerve root entrapment, however, the effect of SAH on radicular arteries and spinal nerve root axons has not been investigated to date. We aimed to investigate the effect of SAH on radicular arteries and spinal nerve root axons, and histopathological findings. The volumetric changes of the radicular arteries and the density of spinal nerve root axons of a SAH model on C<sub>4</sub> roots in rabbits were measured.

## MATERIAL AND METHODS

In the present study, 18 male rabbits were included. Animals were approximately one

year old and weighted 3 kg. The animal protocols were approved by the Ethics Committee of Atatürk University, Medical Faculty. Housing and handling of the animals were in strict accordance with the "Guide for the Care and Use of Laboratory Animals"<sup>(7)</sup>. The rabbits were housed in a room kept at 25±3 °C. The animals were randomly divided into three groups: SAH (n = 10), physiologic serum (SF; n = 4) and control (n = 4) groups. All procedures were carried out under aseptic conditions. The animals were anaesthetized by subcutaneous injection of a mixture of ketamine hydrochloride (25 mg/kg), lidocaine hydrochloride (15 mg/kg), and acepromazine (1 mg/kg). After the occipito-cervical region was prepared, autologous blood (0.5 mL) was taken from the auricular vein and injected into the cisterna magna of animals from the SAH and 0.5 mL SF injected into the cisterna magna of animals in the SF groups with a 22-Gauge needle. The animals in the control group were not subjected to this procedure.

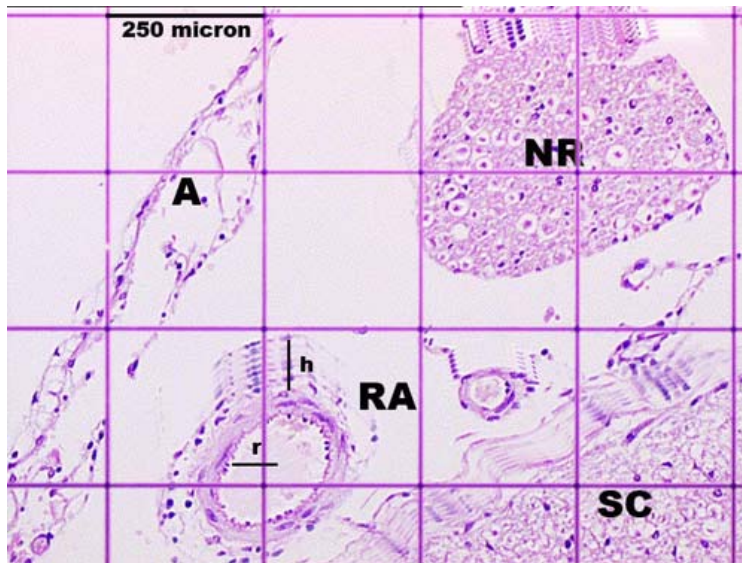
All animals were followed-up for two months and sacrificed. Their cervical nerve roots at the C<sub>4</sub> level were removed. For the light microscopic analysis, these materials were preserved in 10% formalin solution. The specimens were embedded in paraffin blocks and sections were stained with hematoxylin and eosin (H&E). Histopathological changes were observed and the density of axons was calculated in the spinal nerve roots. Axonal shrinkage, periaxonal halo formation and axonal loss were accepted as axonal degeneration.

To calculate the volumetric changes of the radicular arteries (RAs) due to vasospasm or vasodilatation factors, a three-dimensional cylindrical RA model was created by the reconstruction of seven consecutive histological sections of each RA (Figure 1). In the RA model, the luminal radius is represented by 'r', and the height is represented by 'h'. Geometrical volume calculation methods were used in

the reconstructed cylindrical RA sample. The standardized RA's volume was calculated with the following formula:

$$V = \Pi r^2 h$$

Statistical analysis was performed using a nonparametric Mann Whitney-U Test.



**Figure 1:** The three-dimensional demonstration of cylindrical shaped radicular artery (RA) model using for volume calculation (A: arachnoid membrane, NR: nerve root, r: luminal radius, h: height of imaginary RA, SC: spinal cord). (LM, H&E, x 200).

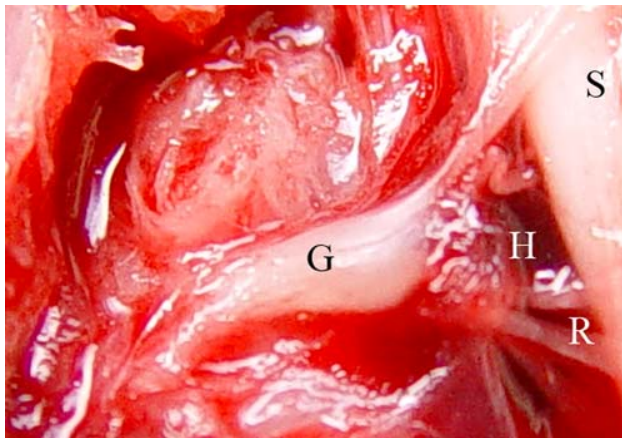
## RESULTS

In the SAH group, two animals died due to respiratory irregularities at the first week of operation and two animals were added to the study. The majority of the animals (n=7) displayed consciousness, muscle rigidity, extension posture to pain stimulation, and bowel and bladder dysfunctions. Sensitive and motor responses to cold-heat tests were negative at their extremities. Posture and gait disturbances were also observed in animals with severely enflamed nerve roots.

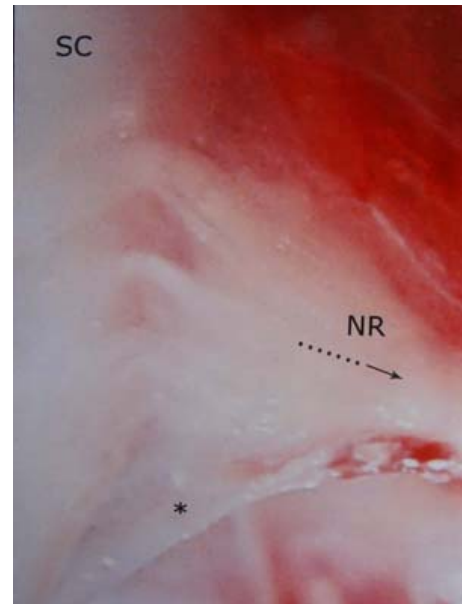
Macroscopic observation of the early appearance of spinal cord, C<sub>4</sub> nerve root, arachnoid membrane covering the spinal cord and blood content in the subarachnoid space at the C<sub>4</sub> region are presented (Figure 2A). Nerve root adhesions, reddish radices and spinal cord were detected (Figure 2B). Histopathological appearance of a normal C<sub>4</sub> radix is shown in Figure 3A. Histopathological examination revealed arachnoid thickening, pial adhesions and axonal changes at the C<sub>4</sub> root (Figure 3B). Demonstrable massive

arachnoiditis formations were detected in the seven animals of the SAH group after two months (Figure 4). The mean volume of imaginary RAs was estimated as  $4000 \pm 300 \mu\text{m}^3$  in the control group and  $2500 \pm 250 \mu\text{m}^3$  on the arachnoiditis developing animals in the SAH group (Figure 5A). This value was  $3600 \pm 230 \mu\text{m}^3$  for the SF group (Figure 5B). The difference in volume reduction of the RAs was significant between the SAH and other two groups ( $p < 0.05$ ). The mean alive axon

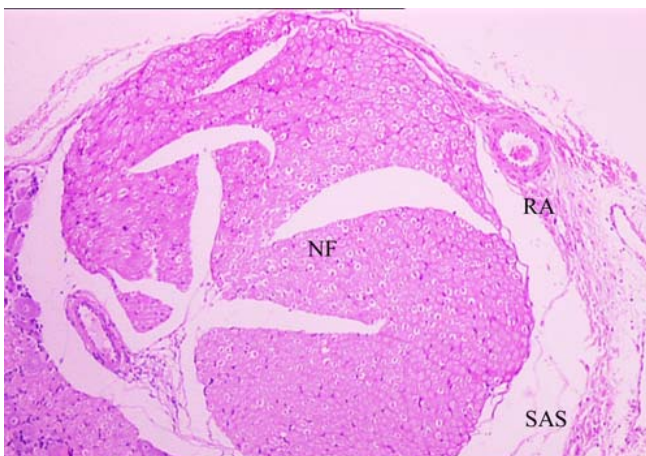
density of the  $C_4$  nerve root was  $17500 \pm 2350/\text{mm}^2$  in the control group (Figure 6). Whereas the density of living axons was  $16450 \pm 850/\text{mm}^2$  for the SF group and  $12850 \pm 1050/\text{mm}^2$  in the SAH group. Numerous axonal degenerations were observed in the SAH group (Figure 7), but not in SF and control groups. The density of living axons was reduced in the SAH group compared to the control and SF groups ( $p < 0.05$ ).



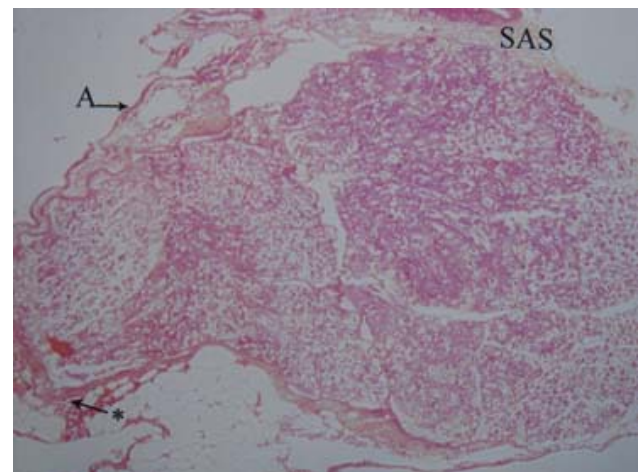
**Figure 2A:** Gross anatomic architecture of the  $C_4$  spinal root of a rabbit after SAH (S: Spinal cord, R: nerve root, G: spinal ganglion, H: hemorrhage).



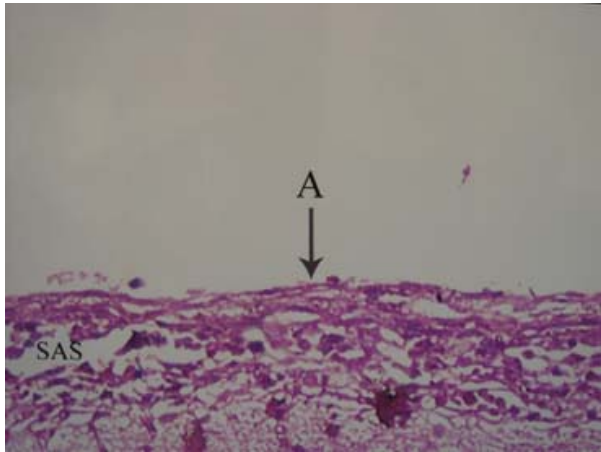
**Figure 2B:** Spinal cord (SC),  $C_4$  nerve root adhesions (NR), arachnoid membrane (\*) and arachnoiditis formation.



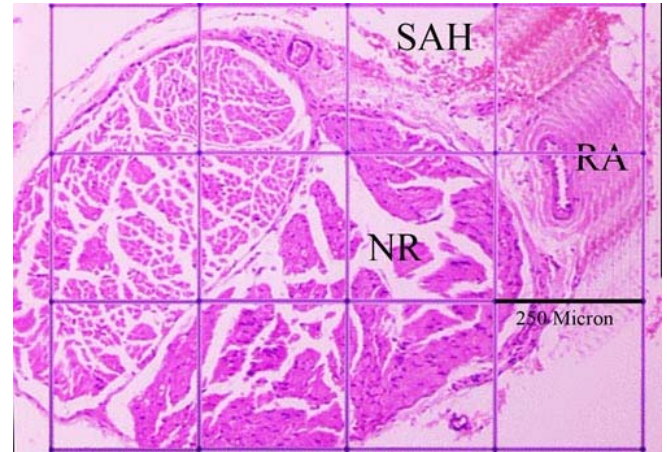
**Figure 3A:** Histopathological appearance of a nerve root of  $C_4$  (NF) is seen in a healthy rabbit (RA: Radicular artery, SAS: subarachnoid space) (H&E, x 40).



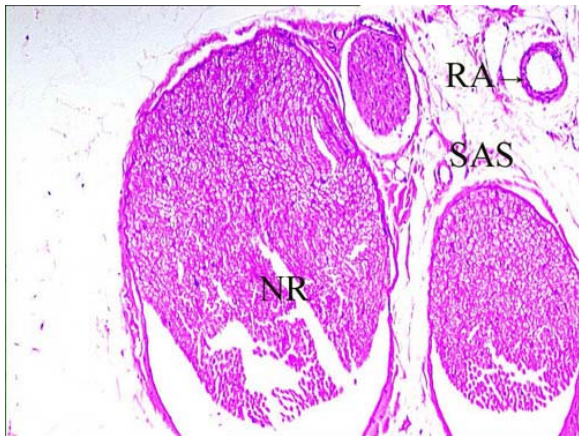
**Figure 3B:** Arachnoid thickening (A), adhesions and inflammatory material collections (\*) are seen in the SAS (LM, H&E, x 20).



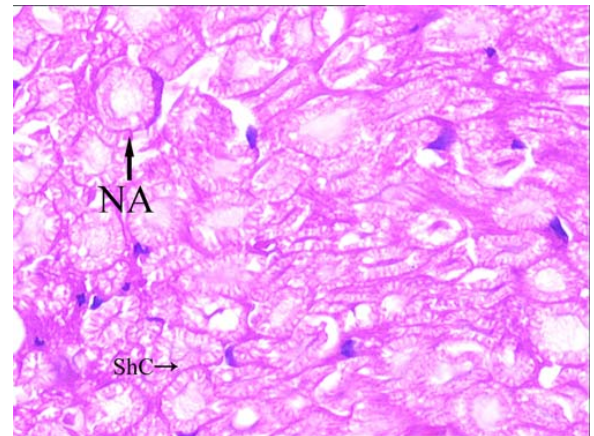
**Figure 4:** Demonstrable massive arachnoiditis formation (A: Arachnoid thickening, SAS: subarachnoid space) (LM, H&E, x 200)



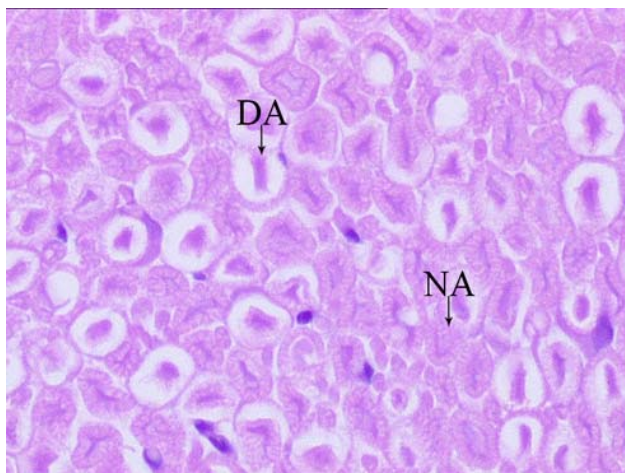
**Figure 5A:** The volume of imaginary RAs in the SAH group. Meningitis resembling arachnoiditis formation was observed in some animals (NR: nerve root, RA: Radicular artery, SAH: subarachnoid hemorrhage) (H&E, x100, LM).



**Figure 5B:** The volume of imaginary RAs in the SF group. Unimportant arachnoiditis formation and axonal injury were observed in some roots (NR: nerve root, RA: Radicular artery, SAS: subarachnoid space) (H&E, x100, LM).



**Figure 6:** Magnified histopathological appearance of normal axons of C<sub>4</sub> spinal nerve root (NA) and Schwann cells (ShC) in a normal rabbit (H&E, x200, LM).



**Figure 7:** Axonal injury and degeneration were observed in the C<sub>4</sub> root in rabbits with SAH (DA: degenerated axon, NA: normal axon) (H&E, x200, LM).

## DISCUSSION

Our study demonstrates that SAH produces arachnoiditis and degenerates the axons of the spinal nerve roots due to ischemia, which is induced by vasospasm.

After SAH, clinical deterioration is possible due to spinal arachnoiditis as a secondary complication of SAH. Arachnoiditis causes progressive gait imbalance and increased urinary frequency associated with unlocalized sensitive disturbances<sup>(2)</sup>. Arachnoiditis affects the spinal cord and nerve roots. Patients with this disease have severe lower back and leg pain, sweating and low grade fever<sup>(3)</sup>. Spinal arachnoiditis may have a place in the differential diagnosis of chronic back pain, discal hernia, spinal cord and spine disorders<sup>(8)</sup>.

The most common symptoms of arachnoiditis are burning, severe lower-back pain, dysesthesia and numbness but not the usual dermatome, bladder, bowel and/or sexual dysfunctions. Persistent neuropsychiatric complaints are present in the majority of patients with spinal arachnoiditis<sup>(1)</sup>. Chronic adhesive spinal arachnoiditis following SAH can progress to severe spinal cord dysfunctions and even paraplegia<sup>(2,6,16)</sup>.

CSF has an important role in the nutrition of the spinal cord. Blood in the CSF and the impairment of the CSF produces an inflammatory reaction in the leptomeninges resulting in spinal arachnoiditis<sup>(4,11,14,16)</sup>. Spinal arachnoiditis has been divided into two groups – circumscribed spinal and diffuse spinal involvements. Circumscribed arachnoiditis is a dense fibrotic reaction of the arachnoid localized to one or two spinal segments. The degree of reaction of the arachnoid varies in severity from trabecular thickening to obliteration of the subarachnoid space by a dense white fibrous band which attaches the cord to the dura. This localized reaction may completely obliterate a segment of the subarachnoid space and result in a complete block. Diffuse arachnoiditis is a diffuse obliterative fibrosis of the subarachnoid space and may compress the cord and nerve roots resulting in degeneration of the nerve roots. Intramedullary cystic cavitation can occur in both types of spinal arachnoiditis but is more often seen in the diffuse variety. The adhesive process leads to vascular changes with perivascular cuffing and obliterative thickening of the walls leading to the narrowing of the blood vessel lumen. The

constricting fibrosis further diminishes the blood supply to the cord with resulting areas of softening and cavitation. Some authors suggest that the venous drainage obstruction may be of greater importance in cavity formation than the vascular supply to the cord itself<sup>(16)</sup>. In our study, we observed that the volume of RA lowered in the SAH group when compared with the control and SF groups. We think that decreased volume of the RA due to vasospasm can impair the vascular supply of nerve roots.

Tjandra et al.<sup>(16)</sup> reported two cases of chronic adhesive spinal arachnoiditis following documented SAH. During the operation, there was a diffuse obliterative fibrosis of the subarachnoid space and the arachnoid was thickened and milky white in their macroscopic observation. The biopsy of the arachnoid showed a thickened fibrosed membrane with hemosiderin deposition. They suggested that intracranial SAH has a role in the pathogenesis of adhesive spinal arachnoiditis, presumably due to blood in the CSF. Sajanti et al.<sup>(12)</sup> reported an increase in type I and III collagen synthesis and deposition in the arachnoid and the dura following SAH in the rat, suggesting a fibroproliferative reaction and fibrosis. It has also been reported that the intrathecal compartment is a site for active collagen synthesis under normal conditions. The synthesis rate and collagen synthesis markers in the CSF are markedly increased in patients with a recent SAH, most prominent in weeks 1 and 2, suggesting a fibroproliferative reaction or fibrosis<sup>(13)</sup>.

We observed pia-arachnoid adhesions, inflammatory material collection in the subarachnoid space, meningeal thickening, cord edema, intimal lesions of radicular arteries and neuronal degenerations in the nerve roots and spinal cord. Tatara<sup>(15)</sup> found that histological examination shows obliteration or narrowing of the lumen of the small pial vessels, multiple spots of demyelination due to secondary ischemia,

proliferation of fibrous tissue, lymphocytic infiltration and obliterating processes of small pial vessels involved in rabbits and rats. These lesions may result in neural conduction deterioration in the affected neural structures and cause neuropsychiatric problems in the future. We found no study about the effects of SAH on the density of spinal nerve root axons. We showed that SAH degenerates the axons of the spinal nerve roots due to deprivation from the blood stream.

In conclusion, the results of our study demonstrate SAH may be an important factor in the development of arachnoiditis and reduces the density of living axons of the spinal nerve roots resulting from arterial vasospasm. These lesions may result in neural conduction deterioration in the affected neural structures and cause neuropsychiatric problems for patients in the future.

**Correspondence to:**

Yurdal Serarslan

E-mail: [yserarslan@yahoo.com](mailto:yserarslan@yahoo.com)

**Received by:** 13 February 2009

**Revised by:** 21 September 2009

**Accepted:** 14 October 2009

**The Online Journal of Neurological Sciences (Turkish) 1984-2009**

This e-journal is run by Ege University  
Faculty of Medicine,

Dept. of Neurological Surgery, Bornova,  
Izmir-35100TR

as part of the Ege Neurological Surgery  
World Wide Web service.

Comments and feedback:

E-mail: [editor@jns.dergisi.org](mailto:editor@jns.dergisi.org)

URL: <http://www.jns.dergisi.org>

Journal of Neurological Sciences (Turkish)

Abbr: J. Neurol. Sci.[Turk]

ISSNe 1302-1664

## REFERENCES

1. Aldrete JA. Neurologic deficits and arachnoiditis following neuroaxial anesthesia. *Acta Anaesthesiol Scand* 2003; 47: 3-12.
2. Augustijn P, Vanneste J, Davies G. Chronic spinal arachnoiditis following intracranial subarachnoid haemorrhage. *Clin Neurol Neurosurg* 1989; 91: 347-50.
3. Couto da Silva JM, Couto da Silva JM Jr, Antonio Aldrete J. Body temperature and diaphoresis disturbances in a patient with arachnoiditis. *Anesth Analg* 2001; 93: 1578-9.
4. De Bruyne J, Sieben G, De Reuck J, VanderEecken H. Radicular lesions in tuberculous meningitis. A clinicopathological study. *Acta neurol Belg* 1983; 83: 117-25.
5. Dolan RA. Spinal adhesive arachnoiditis. *Surg Neurol* 1993; 39: 479-84.
6. Faure A, Khalfallah M, Perrouin-Verbe B, Caillon F, Deschamps C, Bord E, Mathe JF, Robert R. Arachnoiditis ossificans of the cauda equina. Case report and review of the literature. *J Neurosurg* 2002; 97: 239-43.
7. *Guide for the Care and Use of Laboratory Animals*. NIH Publication No.85-23, revised 1996: New York
8. Hoffman GS. Spinal arachnoiditis. What is the clinical spectrum? I. *Spine* 1983; 8:538-40.
9. Kok AJ, Verhagen WI, Bartels RH, van Dijk R, Prick MJ. Spinal arachnoiditis following subarachnoid haemorrhage: report of two cases and review of the literature. *Acta Neurochir (Wien)* 2000; 142: 795-8.
10. Martin RJ, Yuan HA. Neurosurgical care of spinal epidural, subdural, intramedullary abscess and arachnoiditis. *Orthop Clin North Am* 1996; 27: 125-36.
11. Miaki K, Matsui H, Nakano M, Tsuji H. Nutritional supply to the cauda equina in lumbar adhesive arachnoiditis in rats. *Eur Spine J* 1999; 8: 310-6.
12. Sajanti J, Björkstrand AS, Finnila S, Heikkinen E, Peltonen J, Majamaa K. Increase of collagen synthesis and deposition in the arachnoid and the dura following subarachnoid hemorrhage in the rat. *Biochim Biophys Acta* 1999; 1454: 209-16.
13. Sajanti J, Majamaa K. Detection of meningeal fibrosis after subarachnoid haemorrhage by assaying procollagen propeptides in cerebrospinal fluid. *J Neurol Neurosurg Psychiatry* 1999; 67: 185-8.
14. Srivastava T, Kochar DK. Asymptomatic spinal arachnoiditis in patients with tuberculous meningitis. *Neuroradiology* 2003; 45: 727-9.
15. Tataru N. Experimental syringomyelia in rabbits and rats after localized spinal arachnoiditis. *No To Shinkei* 1992; 44: 1115-25. (Abstract)
16. Tjandra JJ, Varma TR, Weeks RD. Spinal arachnoiditis following subarachnoid hemorrhage. *Aust N Z J Surg* 1989; 59: 84-7.