

## *Original Articles*

# Transabdominal Approach in the Surgical Management of Morgagni Hernia

MEHMET YILMAZ, BURAK ISIK, SACIT COBAN, GOKHAN SOGUTLU, CENGIZ ARA, VEDAT KIRIMLIOGLU, SEZAI YILMAZ, and CUNEYT KAYAALP

Department of General Surgery, School of Medicine, Inonu University, Turgut Ozal Medical Center, 44069 Malatya, Turkey

### Abstract

**Purpose.** Morgagni hernias are uncommon diaphragmatic hernias that are generally asymptomatic, and so far only limited data have been reported. The objective of this retrospective study was to evaluate the outcome of patients presenting with a complicated Morgagni hernia and who undergo a transabdominal repair.

**Methods.** Between September 1999 and October 2005, 11 patients with Morgagni hernia were operated on in our department. Eight of them had acute presentations because of a complicated Morgagni hernia. The patient demographics, presenting symptoms, operative approach, and complications were collected. The postoperative course was evaluated for morbidity and mortality.

**Results.** The patients' ages ranged from 42 to 85 years (mean 69.4). Two (18.2%) patients were male and nine (81.8%) patients were female. Chest roentgenograms, computed tomography, and contrast meal studies were used as diagnostic utilities. A transabdominal approach was used for all patients. One patient died due to pulmonary failure. The mean follow-up was 2.8 years. There was no recurrence or symptoms regarding the operation in the remaining patients.

**Conclusion.** We recommend the transabdominal approach in patients with Morgagni hernia as it makes it easy to reduce the hernia contents and repair of the hernia sac. Moreover, when complicated with strangulation, incarceration or perforation, a surgical repair through a transabdominal approach is mandatory.

**Key words** Morgagni hernia · Diaphragmatic hernia · Surgery · Laparotomy · Complication

### Introduction

Morgagni hernia is a congenital herniation of the abdominal contents through the retrosternal defect into the thoracic cavity. In 1769 Morgagni first described a diaphragmatic hernia that originated from the sternocostal trigone.<sup>1</sup> In 1828 Larrey described a surgical approach to the pericardial cavity through an anterior diaphragmatic defect.<sup>2</sup> This triangular space is located between the muscular fibers of xiphosternum and costal margin fibers protruding into the central tendon. The lack of fusion in the anterior part of the pleuroperitoneal membrane and deficiency in the muscularization result in a hernia in this space. The herniation of abdominal contents is typically caused by an increase in intra-abdominal pressure secondary to trauma, pregnancy, and obesity.<sup>3</sup> We herein report our experience and the suitability of a transabdominal approach as a surgical procedure in 11 patients with Morgagni hernia.

### Patients and Methods

Eleven patients underwent a surgical repair of a Morgagni hernia in the Department of General Surgery, School of Medicine, Inonu University between September 1999 and October 2005. The medical records of the patients were retrospectively reviewed for age, sex, preoperative diagnosis, site of herniation, presenting symptoms, surgical procedure, and operative and radiological findings. The postoperative courses were evaluated for morbidity and mortality.

### Results

The patients' ages ranged from 42 to 85 with an average age of 69.4 years. The relevant demographic clinical and

**Table 1.** Patient characteristics

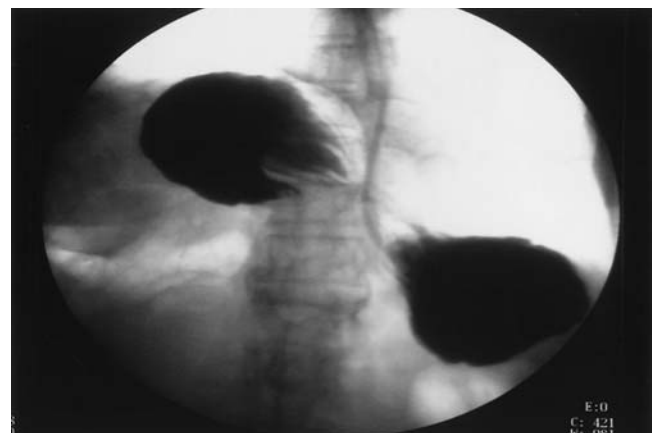
Patient	Age (years)/ Sex	Symptoms	Preoperative diagnosis	Content of hernia sac	Location	Operation method for the hernia
1	68/F	Asymptomatic	Gallbladder tumor	Omentum	Right	PR
2	78/M	Abdominal pain, vomiting	Colonic obstruction, Morgagni hernia	Omentum, colon	Right	PR
3	69/F	Chest and abdominal pain, vomiting	Colonic obstruction, perforation, Morgagni hernia	Omentum, colon	Right	PR
4	85/F	Dyspnea, hematemesis, abdominal pain	Morgagni hernia, acute gastric obstruction	Stomach, colon, omentum	Right	PR
5	85/M	Vomiting, dyspnea, abdominal pain	Morgagni hernia, paraesophageal hernia, colonic obstruction	Omentum, colon	Left	PR
6	42/F	Dyspnea, hypermenorrhea	Morgagni hernia, myoma uteri	Omentum, colon	Right	PR
7	70/F	Dyspnea, chest and abdominal pain	Pneumonia, Morgagni hernia, colonic obstruction	Omentum, colon	Right	PR
8	75/F	Vomiting, abdominal pain	Morgagni hernia, colonic obstruction	Omentum, colon	Right	PR
9	76/F	Dyspnea, chest pain	Morgagni hernia, incisional hernia	Omentum, colon	Right	PR
10	56/F	Dyspnea, chest pain	Morgagni hernia, restrictive pulmonary disease	Omentum, colon, small bowel	Left	Polypropylene mesh repair
11	60/F	Vomiting, abdominal pain	Morgagni hernia, colonic obstruction	Omentum, colon, small bowel	Left	PR

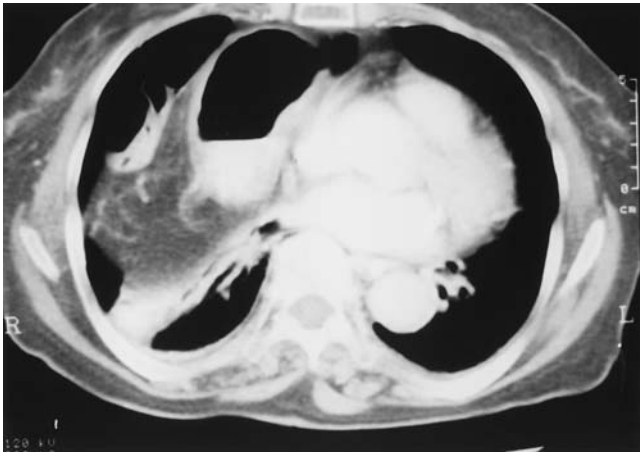PR, Primary repair

operative findings are summarized in Table 1. Two patients (18.2%) were male, and nine patients (81.8%) were female. On physical examination two patients were obese with body mass indexes of 32.4kg/m<sup>2</sup> and 34.7kg/m<sup>2</sup>. Two patients had a past history of trauma. Eight patients (72.7%) had an acute presentation. Six of the eight patients had a similar clinical presentation with acute colonic obstruction causing vomiting, abdominal distention, and dyspnea. In all of these six patients, plain radiography of the abdomen showed multiple air fluid levels in the intestines. The case of patient #3 was complicated with a perforation of cecum and that of patient #11 was complicated with ischemia of transverse colon. Followed by a reduction of the hernia, cecal resection, ileocolostomy, and loop ileostomy in the first patient and segmental colon resection in the other were performed.

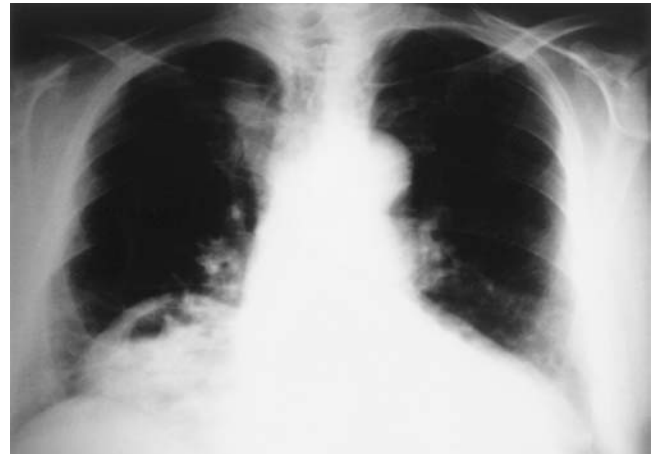
The other two patients with acute presentation were patient #4 and patient #10. Patient #4 presented with acute gastric outlet obstruction causing dyspnea and vomiting. She had a past medical history of upper gastrointestinal bleeding that had been treated medically about 1 week before presentation. Acute gastric outlet obstruction was found in a contrast meal study (Fig. 1). A computed tomography (CT) scan confirmed the stomach and a large bowel segment in the right hemithorax (Fig. 2). She required mechanical ventilation for 3 days in the early postoperative period and was followed at an intensive care unit for 7 days. She was reoperated on for complete wound dehiscence due to a surgical site infection.

Patient #10, with a past medical history of restrictive pulmonary disease and cor pulmonale, was admitted to the emergency department with shortness of breath, cyanosis, and productive cough. Morgagni hernia had been diagnosed 3 years previously at another hospital. She had suffered a fracture of her thoracic vertebra in

**Fig. 1.** Contrast meal study of a patient revealing gastric outlet obstruction



**Fig. 2.** Computed tomography scan of a patient revealing the stomach and large bowel segment in the right hemithorax



**Fig. 3.** Chest X-ray of a patient demonstrates a pouch, containing air suggestive of intrathoracic intestinal gas

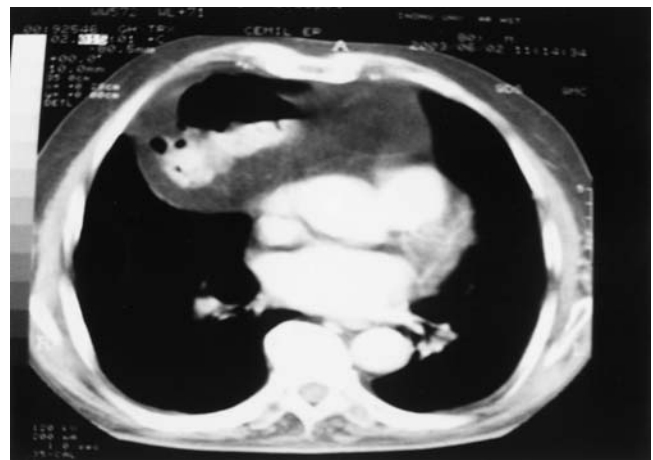
an accident 45 years earlier, which subsequently resulted in severe kyphoscoliosis. She immediately required mechanical ventilation. An emergency laparotomy revealed omentum, transverse colon, ascending colon, cecum, and ileum in the left diaphragmatic hernia. Because of difficulty in reduction, abdomino-mediastinal approach including an upper midline laparotomy with extended lower median sternotomy was performed. She required additional mechanical ventilation in the postoperative period but died of pulmonary failure.

Patient #5 presented with acute colonic obstruction. He had a past history of long-term treatment for iron deficiency anemia. A CT scan demonstrated paraesophageal hernia and concomitant Morgagni hernia with a large bowel segment in the sac in the left hemithorax. Because of a surgical site infection, he was hospitalized for 15 days.

Abdominal pain was the most common symptom (63.6%), followed by dyspnea (54.6%) and chest pain (36.4%). Ten patients (90.9%) were symptomatic. Eight of the 11 patients had right-sided hernia and three had left-sided hernia. Hernia sac was present in all cases. The most common contents of the hernias were the omentum (100%), followed by the colon (90.9%), small bowel (18.2%), and stomach (9.1%).

Chest X-rays (Fig. 3), CT scans (Fig. 4), and contrast meal were used as diagnostic modalities. The preoperative diagnosis was a Morgagni hernia in 10 of the 11 cases, while patient #1 was diagnosed incidentally during a laparotomy for gallbladder carcinoma.

All patients were operated upon via an abdominal approach (nine upper midline and one upper transverse) except for patient #10, who had a laparotomy with an extended lower median sternotomy. Primary repairs of a diaphragmatic defect with interrupted non-



**Fig. 4.** Computed tomography image of a patient with Morgagni hernia containing omental fat and the colon

absorbable sutures were feasible in 10 patients while polypropylene mesh was used in patient #10 who had a huge defect in the diaphragm. The duration of hospitalization ranged from 7 to 18 days (mean 13). Patient #10 died of pulmonary failure. All other patients have shown a postoperative course with no recurrence, with a mean follow-up period of 2.8 years (range from 2 months to 6 years).

## Discussion

Morgagni-type diaphragmatic hernias account for 2%–4% of nontraumatic hernias in adults.<sup>4</sup> The majority are discovered in children who usually present with pneumonia or sepsis.<sup>5</sup> Morgagni hernia is a relatively uncommon diaphragmatic hernia with a potential onset of

morbidity if the diagnosis is delayed or missed. These hernias are usually discovered incidentally when the patient has reached adulthood, or when they become symptomatic owing to intestinal involvement (occlusive symptoms) or when respiratory dysfunction occurs. Nevertheless, it can cause severe disturbances when it occurs.

Kilic et al.<sup>6</sup> described 16 patients with Morgagni hernias that were repaired through transthoracic approaches. They reported that 88% of the patients were symptomatic and none of them were complicated with strangulation or incarceration. Minneci et al.<sup>7</sup> described 12 adult patients with Morgagni hernia. Fifty percent of the patients were symptomatic, and one patient in their series was complicated with acute colonic incarceration and obstruction. One of the largest series published previously is from the Mayo Clinic in 1966 in which 50 patients were treated for Morgagni hernias.<sup>8</sup> Only 28% of these patients were symptomatic, and the symptoms included upper abdominal discomfort, fullness, bloating, vomiting, and bouts of large bowel obstruction.

There have been several reported cases of incarceration or strangulation of hollow viscus<sup>9-11</sup> but there has been no reported series of Morgagni hernia complicated with strangulation, incarceration, or perforation. In our series 90.9% of the patients were symptomatic and 72.7% of the patients presented with acute symptoms that required urgent surgical treatment because of complicated Morgagni hernias.

Morgagni hernia occurs more commonly in males than in females among children.<sup>12</sup> The incidence of Morgagni hernia is higher in patients over the age of 50 years than in younger patients. In younger patients the condition occurs predominantly in males. However, in the older age group the majority of patients are female.<sup>13</sup> Comer and Clagett<sup>8</sup> reported that 70% of the patients were female. In our series 81.8% of the patients were female and the mean age was 69.4 years. The high incidence in the female sex of the older age group in comparison to the young patients and pediatric age group can be explained by the predisposing role of pregnancy. Multiparity, obesity, and trauma, which lead to an increase in intra-abdominal pressure, have been previously reported to be precipitating factors of herniation of the intra-abdominal contents.<sup>3</sup> Two patients were obese and two had a past history of trauma. The majority of Morgagni hernias are right-sided with only rare left-sided occurrences because of the protection provided by the pericardial sac.<sup>7</sup> However, hernias of traumatic origin are more frequently situated on the left side because of the sealing effect of the liver.<sup>9</sup> In the Mayo Clinic series, 90% of the hernias were right sided. In the presented series 72.7% of the hernias were right sided. Three patients had left-sided hernias, one of whom had a past history of trauma.

A Morgagni hernia usually contains the transverse colon, omentum, liver, and sometimes small bowel or stomach.<sup>8</sup> The most common contents of the hernias were the omentum, followed by the colon, small bowel, and stomach. A well-formed hernia sac formed by peritoneum differentiates the Morgagni hernia from a Bochdalek hernia.<sup>14</sup> All our cases had a hernia sac.

One of our patients who had both a paraesophageal hernia and Morgagni hernia had a past history of iron deficiency anemia. A paraesophageal hernia is associated with chronic iron deficiency anemia but it seldom causes respiratory distress.<sup>15</sup> The combination of a Morgagni hernia with a paraesophageal hernia in adults is very rarely encountered. The occurrence of a large diaphragmatic hernia could protect against a second diaphragmatic hernia by reducing the increased intra-abdominal pressure.<sup>16</sup> However, the obesity in this patient probably played a major role in precipitating this rare combination of diaphragmatic hernia.

A gastric obstruction secondary to volvulus or incarceration is one of the rare presentations of Morgagni hernias in adults.<sup>11,17,18</sup> One patient in our series who had a past history of hematemesis was immediately referred for a surgical repair because of acute gastric outlet obstruction. Acute gastric obstruction in patients with Morgagni hernia has been previously reported as a cause of hematemesis and vomiting.<sup>11,18</sup>

Acute respiratory distress secondary to a Morgagni hernia may also be an urgent surgical indication.<sup>19</sup> One of our patients presented with acute respiratory distress and an abdominomediastinal approach was selected as described by Moghissi<sup>20</sup> because of difficulty in performing reduction.

The optimal management consists of early recognition and prompt repair of the diaphragmatic defect to avoid strangulation of the herniated organ. Chest X-rays, contrast meal studies, and CT scans are useful in making a diagnosis. Plain radiographs of the chest and the abdomen are the first choice for radiological evaluations of the diaphragmatic hernias despite their limited findings in most cases. A CT scan is the most effective technique due to its short time duration, and it can be performed easily and effectively in the emergency situations. In our series 90.9% of the patients were correctly diagnosed as Morgagni hernias preoperatively compared with 70% of the patients in the Mayo Clinic series. Differential diagnosis should be made between pleuropericardial cysts, lipomas, liposarcoma, mesothelioma, pericardial fat mass, diaphragmatic cysts, and tumors; thymoma, anterior chest wall tumors.<sup>8,21,22</sup> A radiographic diagnosis of a Morgagni hernia with a CT scan is defined by a large pericardial fat density with linear densities consistent with omental blood vessels and an abnormally high location of the transverse colon.<sup>23</sup> A CT scan can differentiate a cardiophrenic



mass from the heart and can also identify loops of the transverse colon.<sup>24</sup>

Both transabdominal and transthoracic approaches are recommended in the surgical repair of Morgagni hernia. Kilic et al.<sup>6</sup> reported that five of 16 patients required an omental resection because of the unreduced omentum in their transthoracic series. No omental resection was required in our series. We believe that a surgical repair should be performed through the preferred transabdominal approach, especially in the acute settings of the complicated cases. Avoidance of the potentially more morbid transthoracic approach may be another reliable indication for the transabdominal approach.<sup>7</sup>

Video-assisted endoscopic surgery has been claimed to be safe and effective method to fix a Morgagni hernia.<sup>25,26</sup> A laparoscopic hernia repair is feasible in most uncomplicated cases. Patients with complicated hernia and with a past history of prior upper abdominal surgery are candidates for open hernia surgery.<sup>11</sup> We believe that both transthoracic or thoracoscopic approaches have the disadvantages of an abdominal exploration that is mandatory, especially when there is incarcerated or strangulated abdominal viscera. Between 1999 and 2004 we had limited experience in performing an advanced laparoscopy and we did not intend to perform a laparoscopy in any of the present cases. Nowadays, we perform laparoscopic repairs in most ventral or incisional hernias. For incarcerated or strangulated cases we observed higher complication rates, so we cannot now recommend a laparoscopic reduction of the hernial sacs in those complicated cases even for the such diaphragmatic hernias such as Morgagni hernia.

In conclusion, Morgagni hernia is a rare surgical disease. The risk of strangulation or the incarceration of abdominal organs is a strong indication for a prompt repair of the diaphragmatic defect once the diagnosis is established. The preoperative diagnosis is best aided by the use of a CT scan. We recommend the transabdominal approach in patients with Morgagni hernia, especially in complicated cases, as it makes it easy to reduce the hernia contents and repair the hernia sac and the complicated viscera.

## References

- Morgagni G. Seats and causes of disease. London: Candell; 1769. p. 205.
- Larrey D. De plaies du pericarde et du coeur clinique chirurgicale. Paris: Gubon; 1828. p. 284.
- Thomas TV. Subcostosternal diaphragmatic hernia. *J Thorac Cardiovasc Surg* 1972;63:279–83.
- Cullen ML, Klein MD, Philippart AI. Congenital diaphragmatic hernia. *Surg Clin North Am* 1985;65:1115–38.
- Berman L, Stringer D, Ein SH, Shandling B. The late-presenting pediatric Morgagni hernia: a benign condition. *J Pediatr Surg* 1989;24:970–2.
- Kilic D, Nadir A, Doner E, Kavukcu S, Akal M, Ozdemir N, et al. Transthoracic approach in surgical management of Morgagni hernia. *Eur J Cardiothorac Surg* 2001;20:1016–9.
- Minneci PC, Deans KJ, Kim P, Mathisen DJ. Foramen of Morgagni hernia: changes in diagnosis and treatment. *Ann Thorac Surg* 2004;77:1956–9.
- Comer TP, Clagett OT. Surgical treatment of hernia of the foramen of Morgagni. *J Thorac Cardiovasc Surg* 1966;52:461–8.
- Machtelinckx C, De Man R, De Coster M, Ghillebert G, Provoost V. Acute torsion and necrosis of the greater omentum herniated into a foramen of Morgagni. *Abdom Imaging* 2001;26:83–5.
- Gray FJ. Strangulated hernia of the foramen of Morgagni: introducing a principle for the reduction of obstructed intraabdominal hernias. *Aust N Z J Surg* 1981;51:314–7.
- Güven H, Malazgirt Z, Dervisoğlu A, Danacı M, Özkan K. Morgagni hernia: rare presentations in elderly patients. *Acta Chir Belg* 2002;102:266–9.
- Al-Salem AH, Nawaz A, Matta H, Jacobsz A. Herniation through the foramen of Morgagni: early diagnosis and treatment. *Pediatr Surg Int* 2002;18:93–7.
- Schneidau A, Baron HJ, Rosin RD. Morgagni revisited: a case of intermittent chest pain. *Br J Radiol* 1982;55:238–40.
- Kelly KA, Bassett DL. An anatomic reappraisal of the hernia of Morgagni. *Surgery* 1964;55:495–9.
- Bortul M, Calligaris L, Gheller P. Laparoscopic repair of a Morgagni-Larrey hernia. *J Laparoendosc Adv Surg Tech A* 1998;8:309–13.
- Ngaage DL, Young RA, Cowen ME. An unusual combination of diaphragmatic hernias in a patient presenting with the clinical features of restrictive pulmonary disease: report of a case. *Surg Today* 2001;31:1079–81.
- Bhasin DK, Nagi B, Gupta NM, Singh K. Chronic intermittent gastric volvulus within the foramen of Morgagni. *Am J Gastroenterol* 1989;84:1106–8.
- Estevao-Costa J, Soares-Oliveira M, Correia-Pinto J, Mariz C, Carvalho JL, da Costa JE. Acute gastric volvulus secondary to a Morgagni hernia. *Pediatr Surg Int* 2000;16:107–8.
- Wong NA, Dayan CM, Virjee J, Heaton KW. Acute respiratory distress secondary to Morgagni diaphragmatic herniation in an adult. *Postgrad Med J* 1995;71:39–41.
- Moghissi K. Operation for repair of obstructed substernocostal (Morgagni) hernia. *Thorax* 1981;36:392–4.
- Gossios KJ, Tatsis CK, Lykouri A, Constantopoulos SH. Omental herniation through the foramen of Morgagni. Diagnosis with chest computed tomography. *Chest* 1991;100:1469–70.
- Kamiya N, Yokoi K, Miyazawa N, Hishinuma S, Ogata Y, Katayama N. Morgagni hernia diagnosed by MRI. *Surg Today* 1996;26:446–8.
- Fagelman D, Caridi JG. CT diagnosis of hernia of Morgagni. *Gastrointest Radiol* 1984;9:153–5.
- Yildirim B, Ozaras R, Tahan V, Artis T. Diaphragmatic Morgagni hernia in adulthood: correct preoperative diagnosis is possible with newer imaging techniques. *Acta Chir Belg* 2000;100:31–3.
- Hussong RL Jr, Landreneau RJ, Cole FH Jr. Diagnosis and repair of a Morgagni hernia with video-assisted thoracic surgery. *Ann Thorac Surg* 1997;63:1474
- van der Zee DC, Bax NM. Laparoscopic repair of congenital diaphragmatic hernia in a 6-month-old child. *Surg Endosc* 1995;9:1001–3.