

Tuberculosis of the Thyroid Gland: An Uncommon Cause of Thyroid Nodules

Tiroid Bezi Tüberkülozu: Tiroid Nodülünün Nadir Görülen Bir Nedeni

Gökhan Söğütü*
Electron Kebebew**

Burak Işık*
Vedat Kırımlıoğlu*

Mehmet Yılmaz*

Neşe Karadağ*

Aydemir Ölmez*

* Inonu University, General Surgery, Malatya, Turkey

** University of California San Francisco, Endocrine Surgery, San Francisco, USA

We present the case of a 33-year-old woman with tuberculosis of the thyroid. She presented with a thyroid mass, weakness and palpitation for two years. The diagnosis was established on histological examination after thyroid lobectomy. She had an uneventful recovery and received antituberculous medications.

Keywords: Tuberculosis, thyroid gland, thyroid nodule

Biz bu yazıda, son iki yıldır, troid bezinde şişlik, çarpıntı ve halsizlik şikayetleri ile kliniğimize başvuran bir troid tüberkülozu olgusunu sunmayı amaçladık. Hastaya, sağ troid lobundaki nodüle yönelik troid lobektomi yapıldı ve histopatolojik tanı tüberküloz ile uyumlu geldi. Postoperatif dönemi sorunsuz olan hastaya daha sonra antitüberküloz tedavi verildi.

Anahtar kelimeler: tüberküloz, troid bezi, troid nodülü

Introduction

The prevalence of extrapulmonary tuberculosis has increased but involvement of the thyroid gland is rare (1). The rarity of this entity may causes misdiagnosis and mimics a range of thyroid disorders. Although seldom observed, tuberculosis should kept in mind in the differential diagnosis of nodular lesions of thyroid in areas with a high incidence and prevalence of tuberculosis. We present a case of thyroid tuberculosis which presented as a painless solitary nodule of thyroid.

Case Report

A 33 year-old woman presented with a thyroid mass, weakness and palpitation for two years. Examination revealed a diffusely enlarged thyroid gland and a nodule in the right lobe. Her serum T3, T4 and thyroid stimulating hormone levels were normal. Thyroid ultrasound showed diffuse enlargement of both thyroid lobes and an iso to hyperechoic solid nodule measuring 19x34 mm in the right lobe with foci of calcifications.

Fine needle aspiration cytology (FNAC) of the thyroid nodule was a bloody aspirate and cytologic examination revealed groups of follicular cells, on a clean background without any evidence of granulomatous patterns at pathology. A right hemithyroidectomy was performed under general anesthesia and the patient recovered uneventfully.

Correspondence address:

Gökhan Söğütü
Inonu University, General Surgery
Malatya, Turkey
Tel : 0904223241878
E-mail : gsogutlu@inonu.edu.tr

CASE REPORT

Histopathological examination of the thyroid showed multiple nodules consisting of variable sized follicles filled with colloid and a few epithelioid cells and a granulomatous caseification necrosis was present in a few granulomas. (fig.1) Ziehl Nielsen staining was negative for Acid Fast Bacilli (AFB). There was no evidence of disease outside the cervical region. Her chest x-ray was normal. The patient improved with antituberculous therapy consisting of isoniazid 5 mg/kg/d, rifampicin 10 mg/kg/d, pyrazinamide 25/kg/d, and ethambutol 15 mg/kg/d. Pyrazinamide and ethambutol were stopped after 2 months; isoniazid and rifampicin were continued for 4 more months.

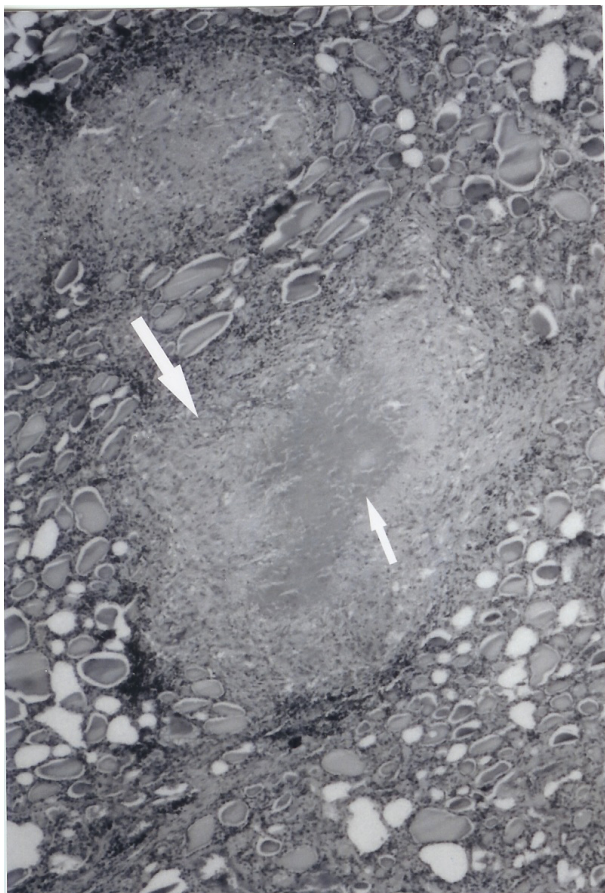


Figure 1 Histopathological examination of the thyroid showing epithelioid cell granuloma (big arrow) and caseification necrosis (small arrow) (H&E; x10)

Discussion

Tuberculosis of the thyroid gland is an extremely rare condition even in endemic areas (2). Although some hypotheses have been attributed to the reason for the rarity of this entity, the exact reason is unknown (3). Possible explanations in the literature

are as follows: colloid material in the thyroid gland possessing bactericidal action; high blood flow and an excess of iodine; enhanced destruction of tubercle bacilli due to increased physiological activity of phagocytes in hyperthyroidism; possible anti-tbc roles of thyroid hormones (3-5).

The signs and symptoms of tuberculosis in the thyroid gland are variable, and are most commonly associated with the enlargement of the gland (4). Thyroid dysfunction is rare (3,4). Thyrotoxicosis has been documented in only a few cases (3).

Two main types of thyroid involvement by tuberculosis are documented: diffuse miliary type and focal caseous tuberculosis (6). It is also possible for tuberculosis of cervical lymph nodes or larynx to involve thyroid gland by direct extension (7).

Thyroid tuberculosis is commonly confused with a primary thyroid neoplasm (8). It could also present as sub-acute thyroiditis (9), thyroid abscess (10) or euthyroid nodular goiter (3). Our case presented with a mass in the thyroid lobe. She had painless solitary nodule of the right thyroid lobe. It was confirmed by thyroid ultrasound. This patient did not have constitutional symptoms such as fever, night sweats, weight loss, and fatigue. There was no evidence of disease outside of the thyroid.

Diagnosis is made by histological examination and the presence of AFB. Histological examination without microbiological confirmation may be taken as diagnostic of tuberculosis of the thyroid in areas where tuberculosis is a common disease (11). The prevalence of tuberculosis is moderately high in our region. Therefore the diagnosis of tuberculosis is likely even though no microbiological isolation of tubercle bacilli from the thyroid tissue was present.

FNAC is useful but may be a false negative. Das et al. reveal that fine needle aspirates from thyroid in 8 cases were found to have cytological features consistent with tuberculosis thyroiditis (11). Also, Mondal et al. reported that FNAC is a useful way to detect tuberculosis of thyroid gland (2). On the other hand other reports suggest that FNAC may not be diagnostic before surgical intervention (9). In our case, FNAC was not diagnostic. We did not repeat the FNAC because of there was no suspicious findings in favor of tuberculosis.

Treatment of thyroid tuberculosis is complex. Administration of antituberculosis drugs combined with surgical removal of the affected part of thyroid gland has been recognized as the preferred method (12). Medical treatment is based on a 6-month course of bactericidal chemotherapy (13). In the light of literatures, we administered antituberculosis therapy for 6 months after the surgical removal of right thyroid lobe.

In summary, tuberculosis should be kept in mind in the differential diagnosis of nodular lesions of the thyroid gland. Patients should receive antituberculosis therapy consisting of isoniazid, rifampicin, pyrazinamide and ethambutol after surgery.

References

1. Orlandi F, Fiorini S, Gonzotto I. Tubercular involment of the thyroid gland: a report of two cases. *Horm Res* **52**: 291-294, 1999.
2. Mondal A, Patra DK. Efficacy of fine needle aspiration cytology in the diagnosis of tuberculosis of the thyroid gland: a study of 18 cases. *J Laryngol Otol* **109**: 36-38, 1995.
3. Khan EM, Haque I, Pandey R, Mishra SK, Sharma AK. Tuberculosis of the thyroid gland: a clinicopathological profile of four cases and review of the literature. *Aust N Z J Surg* **63**: 807-810, 1993.
4. Tan KK. Tuberculosis of the thyroid gland –a review. *Ann Acad Med Singapore* **22**: 580-2, 1993.
5. Bulbuloglu E, Ciralik H, Okur E, Ozdemir G, Ezberci F, Cetinkaya A. Tuberculosis of the Thyroid Gland: Review of the Literature. *World J Surg.* **30**: 149-155, 2006.
6. Barnes P, Weatherstone R. Tuberculosis of the thyroid: two case reports. *Br J Dis Chest* **73**:187-191, 1979.
7. Rosai J. Thyroid gland. In: Rosai J (ed) *Ackerman's Surgical Pathology*. Von Hoffman Press, St. Louis, Missouri,; 497, 1996.
8. Crompton GK, Cameron SJ. Tuberculosis of the thyroid gland mimicking carcinoma. *Tubercle* **50**: 61-64, 1969.
9. Sachs MK, Dickinson G, Amazon K. Tuberculous adenitis of the thyroid mimicking subacute thyroiditis. *Am J Med* 1988; **85**: 573 –575.
10. Bahadur P, Bhatnagar BNS, Aurora AL, Seetharaman ML. Tuberculous abscess of thyroid gland. *Indian J Tuberculosis* **30**: 33-35, 1983.
11. Das DK, Pant CS, Chachra KL, Gupta AK. Fine needle aspiration cytology diagnosis of tuberculous thyroiditis: a report of eight cases. *Acta Cytologica* **36**: 517-522, 1992.
12. Simkus A. Thyroid tuberculosis. *Medicina* **40**: 201-204, 2004.
13. Oidid A, Cherkaoui A, Zaki Z, Hachimi H, El Alami MN. Thyroid tuberculosis. *Ann Otolaryngol Chir Cervicofac* **122**: 150-153, 2005.