



FDG uptake in sarcoidosis mimicking malignant disease on F-18 FDG PET/CT: an analysis of 7 patients

F-18 FDG PET/BT'de malign hastalığı taklit eden sarkoidoza bağlı FDG tutulumları: 7 hastanın değerlendirilmesi

Selin Soyluoglu Demir¹, Gul Ege Aktas¹, Gundeniz Altıay², Ali Sarıkaya¹

¹Nuclear Medicine Department, Trakya University, Edirne, Turkey

²Pulmonary and Respiratory Diseases Department, Trakya University, Edirne, Turkey

Abstract

Objectives: We evaluated general and common characteristics of patients that were referred to Positron Emission Tomography / Computed Tomography (PET/CT) with suspicious lung lesions, then diagnosed as sarcoidosis, in order to determine the contribution of PET/CT to differential diagnosis.

Material and Methods: 7 patients who underwent PET/CT examinations for lung lesions between January 2010 and June 2014, then pathologically diagnosed as sarcoidosis were analyzed retrospectively.

Results: All seven patients had bilateral mediastinal lymph node positivity, six patients had multiple pulmonary parenchymal lesions. Extrathoracic lymph node involvement was determined in three patients. Two patients had hepatic involvement, one had focal nodular and the other one had diffuse hepatic involvement. Three patients had splenic involvement, one with appearance of multiple nodules, diffuse uptake pattern was determined in the other two. Bone involvement was found in two patients. SUVmax range was 3.2 to 20.7 (median: 6.9) for thoracic or extrathoracic lesions of the whole seven patients.

Conclusion: Granulomatous diseases should be kept in mind in case of existence of extrathoracic lymphadenopathy, liver and spleen involvement in addition to lung lesions. PET/CT is helpful in identifying easily accessible biopsy sites, especially for patients with extensive disease. With whole body imaging, metabolic activity and the extent of the disease can be determined with high accuracy. Despite the adoption of many advantages such as post treatment follow-up, determining activation in chronic disease and biopsy site, PET/CT is not placed yet in routine practice. In order to replace algorithms well-organized, prospective clinical trials are needed.

Keywords: Sarcoidosis; FDG; PET; Lymphoma; Lung.

Öz

Giriş: Bu çalışmada akciğerde şüpheli lezyon ve mediastinal lenfadenopati nedeniyle kliniğimize Pozitron Emisyon Tomografisi / Bilgisayarlı Tomografi (PET/BT) ünitesine refere edilen ve biyopsi sonucunda sarkoidoz tanısı alan hastaların genel ve ortak özellikleri değerlendirilerek, PET/BT'nin sarkoidoz tanısına katkısının belirlenmesi ve bulguların literatürle karşılaştırılması amaçlandı.

Gereç ve Yöntemler: Ocak 2010 ile Haziran 2014 tarihleri arasında akciğerde kitle araştırması nedeniyle kliniğimize refere edilmiş ve PET/BT'si çekilmiş daha sonra son tanıları sarkoidoz olarak belirlenmiş yedi hastanın özellikleri retrospektif olarak incelendi.

Bulgular: İncelenen yedi hastanın tümünde bilateral mediastinal lenf nodu pozitifliği, altı hastada multipl pulmoner parankim lezyonu saptandı. Üç hastada ekstratorasik lenf nodu tutulumu izlendi. Karaciğer tutulumu görülen iki hastadan birinde fokal nodüler, diğerinde diffüz tutulum saptandı. Dalak tutulumu izlenen üç hastanın birinde multipl nodüler görünüm, diğer ikisinde diffüz tutulum paterni mevcuttu. İki hastada kemik tutulumu saptandı. İncelenen yedi hastanın torasik veya ekstratorasik tüm vücuttaki lezyonlarına bakıldığında SUVmaks aralığı 3,2-20,7 (median: 6,9) idi.

Sonuç: Akciğerle beraber ekstratorasik lenfadenopati bulguları, karaciğer ve dalak tutulumu, öncelikle akciğer malignitesi şüphesi ile gönderilmiş olan olgularda granülatöz hastalık ayrıcı tanısı aklı gelmesi açısından FDG PET/BT'nin tanı aşamasındaki yararları. PET/BT kolay ulaşılabilir biyopsi yeri belirlenmesi açısından özellikle yaygın hastalık olgularında oldukça yararlıdır. Hastalığın tanı anındaki metabolik aktivitesi ve yaygınlığı tüm vücut değerlendirme ile yüksek doğrulukla belirlenebilmektedir. PET/BT'nin sarkoidozda tedavi takibi, kronik hastalıkta aktifleşen odakların belirlenmesi ve biyopsi yeri tayini gibi pek çok avantajının kabul edilmesine rağmen rutin uygulamada henüz yeri kesinleşmemiştir. Algoritmalarda yerini alabilmesi için iyi düzenlenmiş, prospektif klinik çalışmalara ihtiyaç vardır.

Anahtar Kelimeler: Sarkoidoz; Fdg; Pet; Lenfoma; Akciğer.

Received/Başvuru: 19.12.2015
Accepted/Kabul: 28.01.2016

Correspondence/İletişim

Selin Soyluoglu Demir
Nuclear Medicine Department,
Trakya University, Edirne,
Turkey
E-mail: dr.selina@gmail.com

For citing/Atf için

Demir SS, Aktas GE, Altıay G, Sarıkaya A. FDG uptake in sarcoidosis mimicking malignant disease on F-18 FDG PET/CT: an analysis of 7 patients. J Turgut Ozal Med Cent 2016;23(2):196-201.

INTRODUCTION

Sarcoidosis is a multisystemic disease, characterized by noncaseating granulomatous lesions of unknown etiology. The most common locations of involvement are the lungs. Other than lung, lymph nodes, eyes, skin, liver, spleen, heart, nervous system, bones and joints may be involved. During the clinical process spontaneous regression or progression of chronic disease may occur. The most effective treatment is still systemic steroid administration (1,2).

The gold standard for the diagnosis of sarcoidosis is the histopathological appearance of noncaseating granulomas in tissue biopsy. The most common biopsy sites are skin, peripheral nodules, lacrimal gland and conjunctiva. In case of patients have pulmonary involvement, endobronchial or transbronchial biopsies can be obtained by bronchoscopy. High resolution computed tomography (HRCT) is useful for evaluating interstitial involvement of lung parenchyma, while magnetic resonance imaging (MRI) is useful for diagnosis of the cardiac and neurological involvement. Although Gallium 67 (Ga-67) scintigraphy has been used for detection of complex disease and monitoring response to therapy in sarcoidosis, recently Fluorine-18 Fluorodeoxyglucose Positron Emission Tomography / Computed Tomography (F-18 FDG PET/CT) has superseded it (3,4).

The aim of this study was to evaluate general and common characteristics of patients that were referred to F-18 FDG PET/CT unit with suspicious lung lesions and lymph nodes, then pathologically diagnosed as sarcoidosis, in order to determine the contribution of PET/CT to differential diagnosis of sarcoidosis, malignant lymphoma or lung cancer.

MATERIALS and METHODS

In this study, we evaluated seven patients, six patients with nodular lesions in the lungs and one patient who

had atypical cells in pleural effusion. The patients were referred to PET/CT between January 2010 and June 2014 for suspicion of malignancy. None of the patients had previously diagnosed or treated. PET/CT scans were performed using PET-CT equipment manufactured by G.E. Discovery STE in our department. Each patient was fasted for 4 hours prior to imaging. Blood glucose levels were measured before the procedure by glucometer (One Touch Select. China) in all patients. 296-555 MBq (8-15 mCi) FDG was injected intravenously to the patients with glucose values lower than 200 mg/ml. Each patient was advised to stay idle for 45 to 60 minutes to accurately monitor the radiopharmaceutical agent bio-dispersion. Subsequent to bladder drainage, each patient was positioned onto supine on a PET-CT monitoring bed. 3D emission and transmission scanning were completed in 30 minutes with average 7-8 bed positions from vertex to thigh. The scope of the monitored regions covered axial, coronal and sagittal plans and 0.6 cm thick sequential cross-section were prepared.

Results were evaluated by three experienced nuclear medicine specialist. The standardized uptake value (SUV) in the lesion was calculated based on the activity concentration measured at the end of the scan and corrected for patient's body weight and dose injected.

One patient was diagnosed with clinical and radiological findings; the other six were confirmed histologically by biopsy or operation.

RESULTS

Two females and five males, a total of seven patients, aged between 28-69 (mean 50.7 ± 18.6) were examined retrospectively. Patients' age, gender, thoracic and extrathoracic involvement areas determined by PET/CT, and SUVmax values of these areas were evaluated. The demographic characteristics of the patients, involvement areas and SUVmax values were presented in Tables 1 and 2.

Table 1. The demographic characteristics, SUVmax values, involvement areas and diagnostic methods of the patients.

P	Age	Gender	SUVmaxG	SUVmaxMLN	MLN	Lung	Extrathoracic	Diag
1	69	F	10,1	3,5	bilateral	Mult	Lv+Bone	TBB
2	34	F	6,1	7,7	bilateral	---	Extrathoracic LN +Spleen	Clin
3	65	M	6,9	6,9	bilateral	Mult	---	MS
4	28	M	13,5	10,1	bilateral	Mult	Extrathoracic LN + Spleen	Segm
5	64	M	5,2	5,2	bilateral	Mult	---	TBB
6	31	M	20,7	20,7	bilateral	Mult	---	MS
7	64	M	6,5	3,2	bilateral	Mult	Lv+Bone+Extrathoracic LN+Spleen	LNB

P: Patient, F: Female; M: Male, G: General, MLN: Mediastinal lymph nodes, LN: Lymph nodes, Mult: Multiple, TBB: Transbronchial biopsy, Clin: Clinical diagnosis, MS: Mediastinoscopy, Segm: Segmentectomy, Lv: Liver, LNB: Lymph node biopsy.

Table 2. Number of PET/CT positive patients according to localization of lesions.

Localization of PET/CT positive lesions	Number of patients	Percentage of patients (%)
Mediastinal lymph nodes	7	100
Extrathoracic Lesion	4	57
Lung	6	86
Spleen	3	43
Liver	2	29
Bone	2	29

When the patients' thoracic or extrathoracic lesions throughout the whole body were analyzed, SUVmax range was determined as 3.2 to 20.7 (median: 6.9). SUVmax value was significantly higher than the others in one patient (20.7). All of the patients had bilateral mediastinal lymph node positivity. CT features of lymph nodes were malignant. Six of the patients had multiple pulmonary parenchymal lesions. One patient had no pulmonary parenchymal lesion but had bilateral mediastinal lymph node positivity, and also spleen and extrathoracic lymph node involvement. Extrathoracic lymph node involvement was observed in three patients

(Figure 1). Two patients had hepatic involvement, with focal nodular FDG uptake in one and with diffusely increased FDG uptake and hepatomegaly of the other. Three patients had splenic involvement, one of them had multiple nodules, the other two had diffuse involvement with diffusely increased FDG uptake and splenomegaly (Figure 2). Bone involvement was detected in two patients. While one patient had bone lesions limited to the vertebral column, the other one had iliac bone involvement in addition to vertebral column.

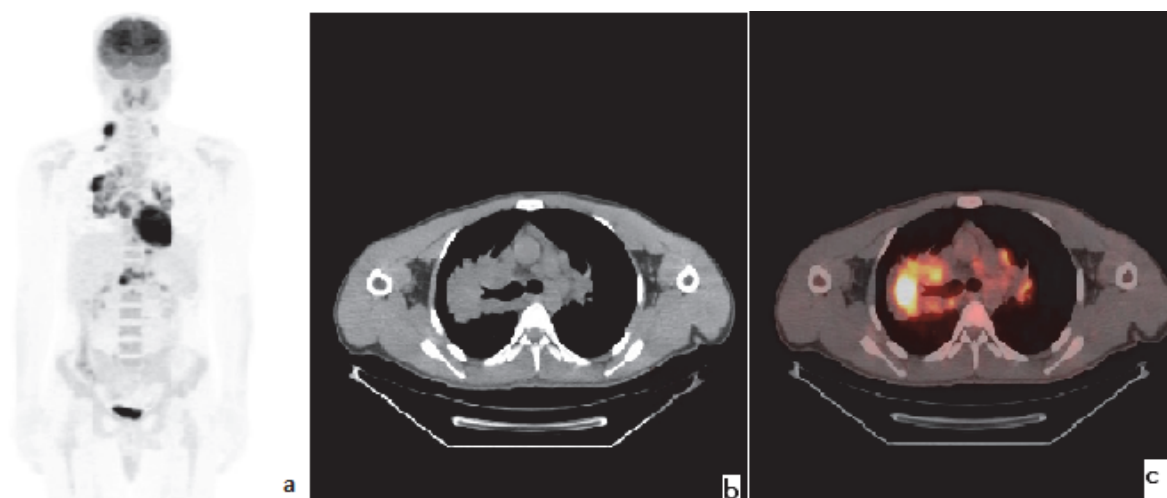


Figure 1. FDG PET of a 28-year-old male patient with diagnosis of sarcoidosis, demonstrates widespread involvement of right supraclavicular, bilateral mediastinal and abdominal multiple lymph nodes that mimicking lymphoma on Maximum Intensity Projection (MIP) images (a). Thoracic axial CT (b) and PET/CT fusion (c) images of same patient shows parenchymal lung lesion located in the central area of right lung, that can lead to false-positive results in terms of lung cancer.

Final diagnoses were made by clinical and radiological findings in one patient, by transbronchial biopsies in two patients. Mediastinoscopy was performed in two

patients and one patient had undergone segmentectomy. Finally, one patient was diagnosed with liver and inguinal lymph node biopsies.

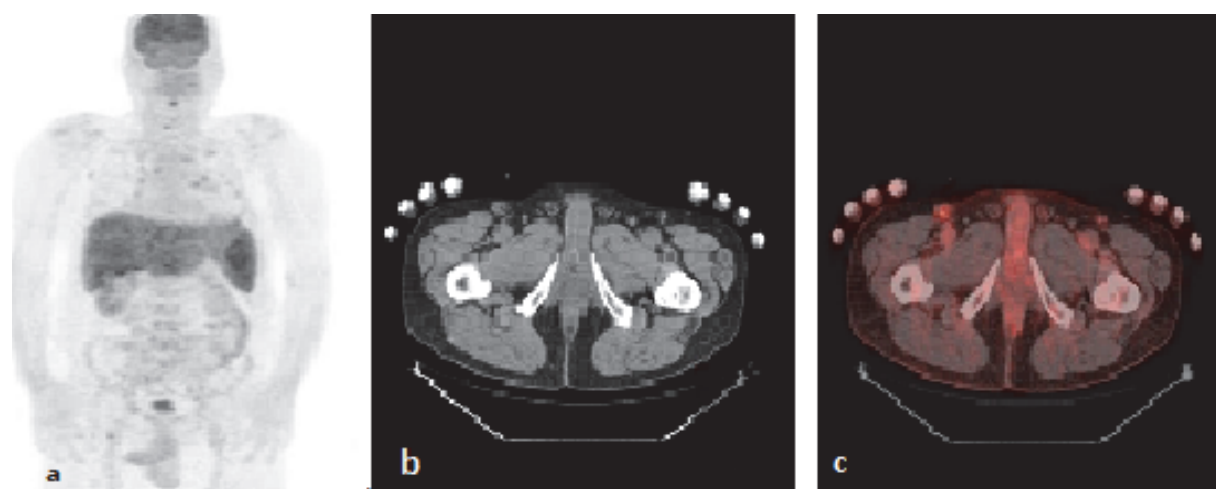


Figure 2. FDG PET of a 64-year-old male patient with diagnosis of sarcoidosis, demonstrates intense diffuse liver and spleen involvement, and vertebral bone involvement more prominent in the cervical area on MIP images (a). Right inguinal lymph node involvement shown on axial CT (b) and PET/CT fusion (c) images of the same patient helped to diagnose as an easy biopsy site.

DISCUSSIONS

Diagnosis of sarcoidosis is based upon clinical, radiological and histopathological features by excluding similar diseases. For clinically suspected patients, first step is to choose a suitable site for biopsy. If patients have pulmonary involvement, endobronchial or transbronchial biopsies can be obtained by bronchoscopy. The diagnostic rate of biopsy, ranges between 40% and 90%, depending on the experience of implementing person and also the number of biopsies. In cases that can not be diagnosed by bronchoscopic biopsy, other procedures such as mediastinoscopy or, if there is no other organ involvement, more invasive procedures such as transthoracic lung biopsy with video (VATS) or open lung biopsy may be considered (5-7). In all other cases, a biopsy should be obtained from the involved organ that is most easily accessible. If there is peripheral lymphadenopathy, skin involvement, lacrimal or parotid gland growth, the biopsy should be done primarily on these sites. PET/CT has an important role with great success in identifying potential active sites for obtaining histologically diagnostic samples. In our study, one patient that have liver, spleen, bone and inguinal lymph node involvement in addition to thoracic findings, was diagnosed by inguinal lymph node biopsy (Figure 2). Luh et al reported the benefits of PET/CT combined with VATS in the diagnosis of Stage 1 sarcoidosis. They suggested that PET/CT can provide more accurate information about the characteristics and localization of the lesions before biopsy and can provide more accurate and earlier diagnosis of patients with suspicious intrathoracic lesions, including the sarcoidosis (8).

ACCP (American College of Chest Physicians) recommends PET, for undiagnosed solitary pulmonary nodules larger than 8mm in diameter with low to moderate expectations of malignancy. F-18 FDG PET imaging is a safe method for the evaluation of lung lesions, with high-sensitivity, good spatial and contrast resolution (4). Integrated PET/CT systems are available of determining the metabolic activity together with the correct anatomic localization, providing a more accurate interpretation of parenchymal lesions and mediastinal lymph nodes. Nevertheless, sarcoidosis, Wegener granulomatosis, aspergilosis and tuberculosis can mimic malignancies with their SUVmax higher than 2.5. Sarcoidosis and lymphomas both effect the lymphoid system and have nonspecific PET features which complicates the differential diagnosis of these two diseases. Similarly, sarcoidosis can mimic pulmonary malignancies because of parenchymal lesions and concomitant lymphadenopathies with high SUVmax values (9). In this study, patients had suspicious lung lesions and concomitant enlarged mediastinal lymph nodes with SUVmax: 3,2-20,7 and the differentiation of lung malignancy was not possible.

The recent literature has defined the contribution of FDG PET/CT as; determining intrathoracic and extrathoracic disease spread in patient that had been diagnosed as sarcoidosis, showing the active inflammatory disease in patients with chronic sarcoidosis

that are symptomatic but serologically negative, evaluation of stage 4 sarcoidosis with pulmonary fibrosis, determining the newly involved areas and reevaluation of the treatment plan and more importantly diagnostic biopsy site identification. Especially evaluation of cardiac sarcoidosis in patient with cardiac pacemaker is another aspect of PET/CT's contribution. Chronic refractory sarcoidosis can also be followed-up with FDG PET/CT in order to evaluate response to therapy (10-13). In our study unfortunately follow-up FDG PET/CT examinations were not available so that we could not evaluate the response to therapy. However the stage and activity of the disease were determined correctly with whole-body PET/CT examination at initial diagnosis.

Although, FDG PET/CT contributes to determination of the spread of metabolic active disease and evaluation of response to therapy, cost-effective use of the diagnostic tools is a very important particular point in developing countries. The subgroup of patients that will mostly benefit from this diagnostic tool should be defined carefully. Therefore, there is a need for well-controlled prospective studies evaluating the contribution of FDG PET/CT in sarcoidosis especially in the name of prognosis and follow-up.

The most common sites involved in sarcoidosis are the lungs. Lymph nodes, eyes, skin, liver, spleen, heart, nervous system, bones and joints can be involved concomitant to the lungs. Hepatic involvement is also common (50%-79%) following lymph node and lung involvement (14). Despite the high percentage of hepatic involvement, only 35% of patients have abnormality in hepatic function tests (15). Few patients (lesser than 5%) are symptomatic. The final diagnosis could be made by biopsy (16). Common finding in hepatic sarcoidosis is hepatomegaly (more than 50%), usually with accompanying splenomegaly. Focal nodular involvement is reported to be 0-19% (17-20). In this study, one of the two cases demonstrated focal nodular hepatic involvement and the other had diffuse involvement with concomitant hepatomegaly.

Splenic involvement in sarcoidosis is reported to be 24-53% in literature (21). Involvement pattern can be homogeneous or multiple nodular patterns can be observed (22-23). Splenic nodules (15%) are more common than the hepatic ones. Tuberculosis, lymphoma, metastasis and abscess should be kept in mind in differential diagnosis, in existence of hepatic and splenic nodular involvement. Candidiasis should be taken in to consideration if the patient is immunosuppressive. Hypoechoic, hypointense nodular lesions on CT with hypermetabolic multiple nodules on FDG PET/CT is the common finding. Diffuse high FDG uptake with splenomegaly was observed in two patients and multiple nodular involvement was detected in the other one, in this study.

Skeletal involvement in sarcoidosis is reported to be 3-39 %, depending on the study population and the imaging modality. It is detected in a low percentage on plane radiographs (3-13%), while it is determined in a higher percentage on bone scintigraphy (39%) and

PET/CT examinations (24). Most common effected sites are bilateral phalangeal bones of the hands and feet. However, any site of the skeleton can be involved. Involvement of long bones, cranium, ribs and vertebral column were reported. PET/CT gives information about the spread of bone involvement concomitantly with the information of bone marrow involvement. However, differential diagnosis of sarcoidosis can not be made by just imaging modalities even it is MRI. The final diagnosis can be made only by biopsy. Bone involvement was determined in two patients in our study. One patient had lesions restricted to the vertebral column, other had iliac bone involvement additionally. There was no need to confirm with biopsy, because it would not change the therapy protocol.

The known incidence of cardiac involvement in sarcoidosis is 5-10%. Mostly effected part is the ventricular septum by a percentage of 31,5%. Inferior wall, anterior wall and lateral walls are the other effected parts respectively. Sarcoid granulomas and fibrosis can induct complete atrioventricular block, systolic and diastolic dysfunction and ventricular tachycardia. Syncope, heart failure and even sudden death can develop. Cardiac MRI is the most specific modality in diagnosis. However, FDG PET/CT is the most sensitive examination, with a sensitivity of 71-100% (25). None of the patients had cardiac involvement in this study.

The common characteristics of cases were lung lesions and mediastinal lymph node involvement. 6 patients with multiple lung lesions and bilateral mediastinal lymph node involvement were seen primarily compatible with lung malignancies. 4 patients had extrathoracic lesions in addition. Spleen and liver involvement was suggestive of a differential diagnosis of granulomatous disease in 4 patients. Bone lesions, had not contribute to the differential diagnosis, because of they could be metastasis of any primary malignancy. SUVmax values and appearance pattern of the lesions did not have a feature that could exclude other malignancies. Especially the liver and spleen involvements were unexpected findings because the patients were asymptomatic. The spread and activity of the disease and appropriate biopsy site for the diagnosis could be evaluated by PET/CT.

CONCLUSION

FDG PET/CT contributes initial diagnosis of granulomatous diseases in patients with suspicion of lung malignancies, by the determination of extrathoracic lymphadenopathy, liver and spleen involvement in addition to lung lesions.

PET/CT is very helpful in identifying the easily attainable biopsy site with active disease.

Whole-body evaluation contributes determining the spread and metabolically active disease at initial diagnosis with high accuracy.

Although PET/CT is known for many advantages as post treatment follow-up, determination activated sites of chronic disease and identifying biopsy site, the routine algorithms do not cover it yet. Therefore, well-controlled prospective studies are needed.

This work was presented as a poster presentation in 27. Annual National Nuclear Medicine Congress; 01-04 April 2015, Adana.

REFERENCES

1. Iannuzzi MC, Rybicki BA, Teirstein AS. Sarcoidosis. *N Engl J Med* 2007;357(21):2153-65.
2. Dempsey OJ, Paterson EW, Kerr KM, Denison AR. Sarcoidosis. *BMJ* 2009;339:b3206.
3. Prabhakar HB, Rabinowitz CB, Gibbons FK, O'Donnell WJ, Shepard JA, Aquino SL. Imaging features of sarcoidosis on MDCT, FDG PET, and PET/CT. *AJR Am J Roentgenol* 2008;190(3 Suppl):S1-6.
4. Basu S, Saboury B, Werner T, Alavi A. Clinical Utility of FDG-PET and PET/CT in Non-malignant Thoracic Disorders. *Mol Imaging Biol* 2011;13(6):1051-60.
5. Shorr AF, Torrington KG, Hnatiuk OW. Endobronchial biopsy for sarcoidosis: a prospective study. *Chest* 2001;120(1):109-14.
6. Trisolini R, Agli L, Cancellieri A, Poletti V, Tinelli C, Baruzzi G, et al. The value of flexible transbronchial needle aspiration in the diagnosis of stage I sarcoidosis. *Chest* 2003;124(6):2126-30.
7. Reich JM, Brouns MC, O'Conner EA, Edwards MJ. Mediastinoscopy in patients with presumptive stage I sarcoidosis: a risk/benefit, cost/benefit analysis. *Chest* 1998;113:147-53.
8. Luh SP, Wu TC, Wang YT, Tsao TC, Chen JY. Experiences and benefits of positron emitted tomography-computed tomography (PET-CT) combined with video-assisted thoracoscopic surgery (VATS) in the diagnosis of Stage 1 sarcoidosis. *J Zhejiang Univ Sci B* 2007;8:410-5.
9. Krüger S, Buck AK, Mottaghy FM, Pauls S, Schelzig H, Hombach V, et al. Use of integrated FDG-PET/CT in sarcoidosis. *Clin Imaging* 2008;32:269-73.
10. Saranovic DS, Grozdic I, Ivanov JV, Vucinic-Mihailovic V, Artiko V, Saranovic D, et al. The Utility of 18F-FDG PET/CT for Diagnosis and Adjustment of Therapy in Patients with Active Chronic Sarcoidosis. *J Nucl Med* 2012;53:1543-9.
11. Saranovic DS, Artiko V, Obradovic V. FDG PET Imaging in Sarcoidosis. *Semin Nucl Med* 2013;43:404-11.
12. Guleria R, Jyothidasan A, Madan K, Mohan A, Kumar R, Bhalla AS, et al. Utility of FDG-PET-CT scanning in assessing the extent of disease activity and response to treatment in sarcoidosis. *Lung India* 2014;31:323-30.
13. Rubini G, Cappabianca S, Altini C, Notaristefano A, Fanelli M, Stabile Ianora AA, et al. Current clinical use of 18FDG-PET/CT in patients with thoracic and systemic sarcoidosis. *Radiol med* 2014;119:64-74.
14. Hercules HD, Bethlem NM. Value of liver biopsy in sarcoidosis. *Arch Pathol Lab Med* 1984;108:831-4.
15. Judson MA. Hepatic, splenic, and gastrointestinal involvement with sarcoidosis. *Semin Respir Crit Care Med* 2002;23(6):529-41.
16. MacArthur KL, Forouhar F, Wu GY. Intra-abdominal complications of sarcoidosis. *J Formos Med Assoc* 2010;109:484-92.

17. Warshauer DM, Molina PL, Hamman SM, Koehler RE, Paulson EK, Bechtold RE, et al. Nodular sarcoidosis of the liver and spleen: Analysis of 32 cases. *Radiology* 1995;195:757-62.
18. Deutch SJ, Sandler MA, Tankanow LB. Abdominal lymphadenopathy in sarcoidosis. *J Ultrasound Med* 1987;6:237-42.
19. Britt AR, Francis IR, Glazer GM, Ellis JH. Sarcoidosis: abdominal manifestations at CT. *Radiology* 1991;178(1):91-4.
20. Folz SJ, Johnson CD, Swensen SJ. Abdominal manifestations of sarcoidosis in CT studies. *J Comput Assist Tomogr* 1995;19(4):573-9.
21. Taavitsainen M, Koivuniemi A, Helminen J, Bondestam S, Kivisaari L, Pamilo M, et al. Aspiration biopsy of the spleen in patients with sarcoidosis. *Acta Radiologica* 1987;28:723-5.
22. Penna C, Deroide GA. Images in clinical medicine. Splenic sarcoidosis. *N Engl J Med* 2003;349:16.
23. Warshauer DM. Splenic sarcoidosis. *Semin Ultrasound CT MR* 2007;28(1):21-7.
24. Kuzyshyn H, Feinstein D, Kolasinski SL, Eid H. Osseous sarcoidosis: a case series. *Rheumatol Int* 2014;296:3170-4.
25. Orii M, Imanishi T, Akasaka T. Assessment of Cardiac Sarcoidosis with Advanced Imaging Modalities. *Biomed Res Int* 2014;2014:897956.