



Variation of axillopectoral muscle and surgical importance: a case report

Musculus axillopectoralis'in varyasyonu ve cerrahi önemi: bir vaka raporu

Mahmut Cay, Songul Cuglan, Deniz Senol, Davut Ozbag, Evren Kose

İnönü University, Faculty of Medicine, Department of Anatomy, Malatya, Turkey

Abstract

M. axillopectoralis (MAP) has been examined under different names and variations in different studies. In routinely conducted dissection studies, an arch holding onto great pectoral muscle originating from latissimus dorsi muscle was detected in the left fossa axillaris of a male cadaver aged 35-40. It was determined that the end branches of a. axillaris, v. axillaris, and plexus brachialis existing in that area passed through the underneath of that arch. MAP has a clinical and morphological importance for those surgeons that are to make surgical interventions in the fossa axillaris area. Thus, surgeons are required to consider the probability of such muscle structures in this area.

Keywords: Fossa Axillaris; Variation; Latissimus Dorsi Muscle; MAP; Cadaver.

Öz

M. axillopectoralis (MAP) farklı çalışmalarda, farklı isimlerle incelenen ve varyasyonu görülen bir kastır. Rutin olarak gerçekleştirilen diseksiyon çalışmalarında, 35-40 yaşlarındaki erkek kadavranın sol fossa axillaris'de, m. latissimus dorsi kasından orjin almış m. pectoralis major'e tutunan bir ark tespit edildi. Bu bölgede bulunan a. axillaris, v. axillaris ve plexus brachialis'in uç dallarının bu arkin altından geçtiği belirlendi. MAP, fossa axillaris bölgesinde cerrahi müdahale yapacak olan cerrahlar için klinik ve morfolojik öneme sahiptir. Bu yüzden cerrahlar bu kas yapısının bu bölgede olma ihtimalini göz önünde bulundurması gerekmektedir.

Anahtar Kelimeler: Fossa axillari; Varyasyon; Musculus Latissimus Dorsi; MAP; Kadavra

Received/Başvuru: 04.05.2016
Accepted/Kabul: 05.05.2016

Correspondence/İletişim

Deniz Senol
İnönü University, Faculty of Medicine,
Department of Anatomy, Malatya,
Turkey
E-mail: deniz.senol@inonu.edu.tr

How to cite this article/Atf için

Cay M, Cuglan S, Senol D, Ozbag D, Kose E. Variation of axillopectoral muscle and surgical importance: a case report. J Turgut Ozal Med Cent 2016;23(4):451-3.

INTRODUCTION

Latissimus dorsi muscle is a platy, wide, and fine muscle that covers the lower half of the thoracic region and the whole lumbar region (1). This muscle, through fascia thoracolumbalis, starts from the 6th to 12th thoracic vertebrae, the processus spinosus of all lumbar and sacral vertebra, the exterior medial part crista iliaca, the angulus inferior of scapula, and the back side of the last four costas. The point of termination is the sulcus intertubercularis of the humerus (2). Latissimus dorsi muscle is a muscle that is frequently used in reconstructive and plastic surgery such as cardiomyopathy and mastectomy as a flap (3).

Among the structures of man's axillary components that have a variant structure, the most well-known one is a muscular or fibro-muscular slip which extends from the latissimus dorsi muscle to the tendons, muscles or fasciae of the superior part of the humerus (4).

There are several terminological varieties. This variant can be called "Achselbogen", "musculus axillopectoralis (MAP)", "axillary arch", "Langer's axillary arch", or "muscularaxillary arch" (5-9). The name "MAP" is used in the present study.

MAP was defined by Ramsay first in 1795. Its complete true definition was made by Langer in 1846. After that, the muscle was called "Langer's axillary arch" (9). This variation was named as MAP in 1977 by Sachatello. Though it differs from community to community, rate of incidence of m. axillopectoralis or Langer's arch in the general population is 7% (10). Langer's arch refers to a situation where certain fibers of latissimus dorsi muscle have an abnormal course through axilla and end in great pectoral muscle. This variation may contain more than one band, and the points of termination may differ (5, 6, 11).

It is known that variations of MAP occupy an important place for physicians and surgeons that carry out axillary examination or surgery. Crossing the artery and vein axillaris just above the area, MAP may widely be chosen for the practice of a ligature. Also, it can cause surgeons make mistakes in the course of the operation.

CASE REPORT

Unilateral m. axillopectoralis extending from latissimus dorsi muscle to great pectoral muscle as a single band in the left fossa axillaris was detected during the dissection of a male a cadaver aged 35-40 in the Anatomy Dissection Lab of İnönü University Faculty of Medicine Department of Anatomy. It had a length of 8.05 cm and a maximum width of 0.93. The end points of plexus brachialis, a. axillaris and v. axillaris passed below MAP (Figure 1). No variation was observed in the right fossa axillaris.

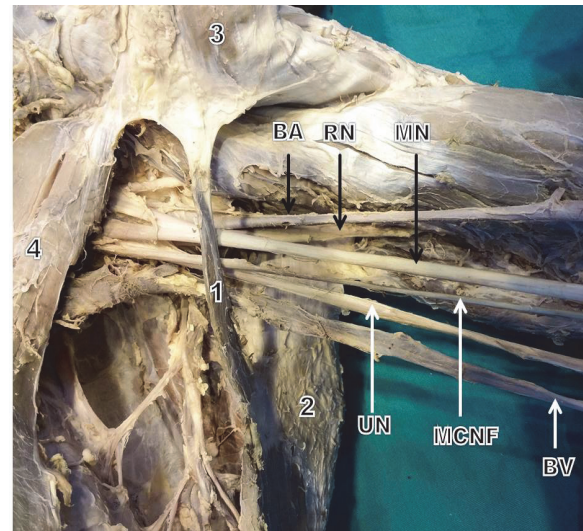


Figure 1. Axillopectoral muscle appearance in axilla and related structures. **1:** Axillopectoral muscle; **2:** latissimus dorsi muscle; **3:** great pectoral muscle; **4:** lesser pectoral muscle; **BA:** brachial artery; **RN:** radial nerve; **MN:** median nerve; **UN:** ulnar nerve; **MCNF:** medial cutaneous nerve of forearm; **BV:** brachial vein

DISCUSSION

Fossa axillaris is a complex structure that contains important neurovascular structures and lymph nodes. The most frequently observed variation in this area is MAP (9, 12).

MAP may lead to complications such as thoracic outlet syndrome and deep venous thrombosis by extending on neurovascular structures like an arch. Therefore, it is clinically important to know that MAP exists in this area (13-17). Testut (1884) classified these differences into two: complete and incomplete (6). In the complete form, it ends in the tendon of great pectoral muscle rather than on the humerus. In the incomplete form, MAP may start from latissimus dorsi muscle and extend to fascia axilla, m. biceps brachii, m. coracobrachialis, lesser pectoral muscle, sulcus intertubercularis' distal end or proc. coracoideus (11, 18). The complete form of the variation was observed in this case presentation. Though MAP was observed unilateral in this case, it is generally reported to be bilateral (9, 13, 18). This variation is reported to be observed on the left part in the case studies in the literature, and this is true for our case, too (11, 16, 17, 19-21).

Turgut *et al.* conducted a study on 26 cadavers and found one MAP variation. This muscle was found to have a length of 9.6 cm and a width of 1.4 cm (11). In their case presentation, Yüksel *et al.* reported a MAP having a length of 11 cm and a width of 1 cm (20). The values found in our case are similar to the cases in the literature.

The variation was found to have different frequencies in different races. Table 1 shows the frequency of variation based on populations

Turgut *et al.* stated that MAP can be innervated from different nerves, and this innervation can be made by n. pectoralis minor due to its embryological development. It is also reported that this muscle can be innervated

from the perforating branches of n. thoracodorsalis, n. intercostalis secunda or n. intercostalis tertia (9, 13). In the present study, the nerve innervating could not be detected.

Table 1. The incidence of the MAP reported in the literature

Author (year)	No. of arches	No. of subjects	%	Population
Clarys (1996)	16	183	8,7	Caucasian
Georgiev (2006)	2	56	3,6	Caucasian
Kasai (1977)	10	88	11,4	Japanese
Kalaycioglu (1998)	1	60	1,7	Caucasian
Merida-Velasco (2003)	3	32	9,4	Caucasian
Miguel (2001)	3	50	6	Caucasian
Schramm (1984)	9	60	15	Caucasian
Serpell and Baum (1991)	4	2000	0,2	Caucasian
Takafuji (1991)	3	47	6,4	Japanese
Turgut (2005)	1	26	3,8	Caucasian

CONCLUSIONS

This study presents a muscular variation in the axilla. Information on this variation can bring benefits to operators for the use of latissimus dorsi muscle in a lot of plastic and reconstructive surgeries.

Conflict of interests

The authors hereby declare that they have no competing interests.

REFERENCES

- Taner D. Fonksiyonel Anatomi Ekstremiteler ve Sirt Bölgesi. Ankara: HYB Basın Yayın;2013.
- Arıncı, K., Elhan, A. Anatomi (I. Cilt). Ankara: Güneş Kitabevi;2006.
- Del Sol M, Olave E. Elevator Muscle of the Tendon of Latissimus Dorsi Muscle. *Clinical Anatomy*. 2005;18(2):112-4.
- Bakirci S, Kafa IM, Uysal M, Sendemir E. Langer's axillary arch (axillopectoral muscle): a variation of latissimus dorsi muscle. *International Journal of Anatomical Variations*. 2010; 3:91-2.
- Bergman RA, Thompson SA, Afifi AK, Saadeh FA. *Compendium of Human Anatomic Variation: Catalog, Atlas and World Literature*. Urban & Schwarzenberg. Baltimore and Munich; 1988.
- Testut L. *Les Anomalies Muscularies chez l'Homme Expliqués par l'Anatomie Comparée*. Paris: Masson;1892.
- Jelev L, Georgiev GP, Surchev L. Axillary arch in human: common morphology and variety. Definition of "clinical" axillary arch and its classification. *Ann Anat*. 2007;189(5):473-81.
- Georgiev GP, Jelev L, Surchev L. Axillary arch in Bulgarian population: clinical significance of the arches. *Clin Anat*. 2007; 20(3):286-91.
- Besana-Ciani I, Greenall MJ. Langer's axillary arch: anatomy, embryological features and surgical implications. *Surgeon* 2005; 3:325-7.
- Loukas M, Noordeh N, Tubbs RS, Jordan R. Variation of the axillary arch muscle with multiple insertions. *Singapore Med J*. 2009;50(2):e88-90.
- Turgut HB, Peker T, Gulekon N, Anil A, Karakose M., Axillo pectoral muscle (Langer's muscle). *Clin Anat*. 2005;18: 220-3.
- Daniels IR, dellaRovere GO. The axillary arch of Langer: the most common muscular variation in the axilla. *Breast Cancer Res Treat*. 2000;59:77-80.
- Clarys JP, Barbaix E, Van Rompaey H, Caboor D, Van Roy P. The muscular arch of the axilla revisited: its possible role in the thoracic outlet and shoulder instability syndromes. *Man Ther*. 1996;1(3):133-9.
- Van Hoof T, Vangestel C, Forward M, Verhaeghe B, Van Thilborgh L, Plasschaert F et al. The impact of muscular variation on the neurodynamic test for the median nerve in a healthy population with Langer's axillary arch. *J Manipulative Physiol Ther*. 2008;31(6):474-83.
- Lama P, Potu B. K., Bhat KMR. Chondrohumeralis and axillary arch of Langer: a rare combination of variant muscles with unique insertion. *Romanian Journal of Morphology and Embryology*. 2010;51(2):395-7.
- Magee C, Jones C, McIntosh S, Harkin DW. Upper limb deep vein thrombosis due to Langer's axillary arch. *J Vasc Surg*. 2012;55(1):234-6.
- Hafner F, Seinost G, Gary T, Tomka M, Szolar D, Brodmann M. Axillary vein compression by Langer's axillary arch, an aberrant muscle bundle of the latissimus dorsi. *Cardiovasc Pathol*. 2010;19(3):e89-90.
- Merida-Velasco JR, Rodriguez Vazquez JF, Merida Velasco JA, Sobrado Perez J, Jimenez Collado J. Axillary arch: potential cause of neurovascular compression syndrome. *Clin Anat*. 2003;16(6):514-9.
- Üçerler H, İkiz ZA, Pinan Y. Clinical Importance of the Muscular Arch of the Axilla (Axillopectoral muscle, Langer's Axillary Arch). *Acta Chir Belg*. 2005;105(3):326-8.
- 20-Yüksel M, Yüksel E, Sürücü S. An axillary arch. *Clin Anat*. 1996;9(4):252-4.
- Drahap A. An unusually medial axillary arch muscle. *J Anat*. 1994;184(Pt 3):639-41.