

Tuberculous liver abscess in an immunocompetent child with pulmonary tuberculosis as a cause of fever of unknown origin

Bahar Çalışkan¹, Ayper Somer¹, Nevin Hatipoğlu¹, Melike Keser¹, Ensar Yekeler², Feryal Gün³, Mine Güllüoğlu⁴, Tansu Salman³, Nuran Salman¹

¹Division of Pediatric Infectious Diseases, Department of Pediatrics, and Departments of ²Radiodiagnostics, ³Pediatric Surgery and ⁴Pathology, İstanbul University, İstanbul Faculty of Medicine, İstanbul, Turkey. E-mail: drbaharbudan@gmail.com

Received: 22 April 2014, Revised: 5 May 2014, Accepted: 6 June 2014

SUMMARY: Çalışkan B, Somer A, Hatipoğlu N, Keser M, Yekeler E, Gün F, Güllüoğlu M, Salman T, Salman N. Tuberculous liver abscess in an immunocompetent child with pulmonary tuberculosis as a cause of fever of unknown origin. Turk J Pediatr 2015; 57: 85-89.

Infectious diseases are the leading cause of FUO. A case of prolonged fever with hepatic and pulmonary tuberculosis as a final diagnosis is herein presented.

A 4-year-old, otherwise healthy boy presented with an axillary temperature of up to 39.5°C for the previous 3 weeks. His medical history revealed an occasional increase in body temperature up to 38.5°C for the last 6 months. Physical examination revealed coarse breath sounds on the basal lung area. Chest X-ray showed mediastinal lymphadenomegaly and computed tomography revealed paratracheal conglomerated lymph nodes and a ground-glass appearance on the right lung. There were multiple contrast-enhanced, hypoechoic nodules with central necrosis in the liver parenchyma on abdominal magnetic resonance imaging. Open liver biopsy yielded chronic granulomatous inflammation compatible with pathological findings of tuberculosis infection. The culture specimen was positive for *Mycobacterium tuberculosis*. The patient improved rapidly after antituberculous therapy was initiated.

Tuberculosis, especially in its disseminated form, poses a distinct diagnostic challenge in cases of prolonged fever with unproven etiology, and thus persistence should be exercised in disclosing the cause of such fevers.

Key words: tuberculous infection, hepatic abscess, prolonged fever.

The term “fever of unknown origin” (FUO) is applied to a single illness of at least 3 weeks’ duration in which fever >38.3°C is present on most days, and diagnosis remains uncertain after 1 week of intense evaluation that includes a careful history and physical examination and an initial laboratory assessment. The list of infectious and noninfectious etiologies of FUO in children is extensive. The three most common etiological categories are infectious diseases, connective tissue disorders and neoplasms¹⁻⁵. In many cases a definitive diagnosis is established with difficulty.

Infectious diseases are the leading cause of FUO, and among these tuberculosis is prominent. However, tuberculous liver abscess is not encountered that often^{6,7}. When present, it is usually associated with a focus of infection

in the lung or gastrointestinal tract, or with an immunocompromised state⁸. Diagnosis is difficult in most instances due to confusion with hepatoma and pyogenic and amoebic liver abscess^{8,9}. Therefore, tuberculous abscess should be excluded in cases of suspected pyemic abscess before starting antibiotics to avoid delay in treatment. Here we report a 4-year-old immunocompetent patient with prolonged fever and metastatic hepatic tuberculous abscesses as a final diagnosis.

Case Report

A 4-year-old boy with an axillary temperature of up to 39.5°C, which had been evident at least 3 or 4 days a week for the past 3 weeks, but with no other serious complaints during that time, was admitted to our outpatient clinic.

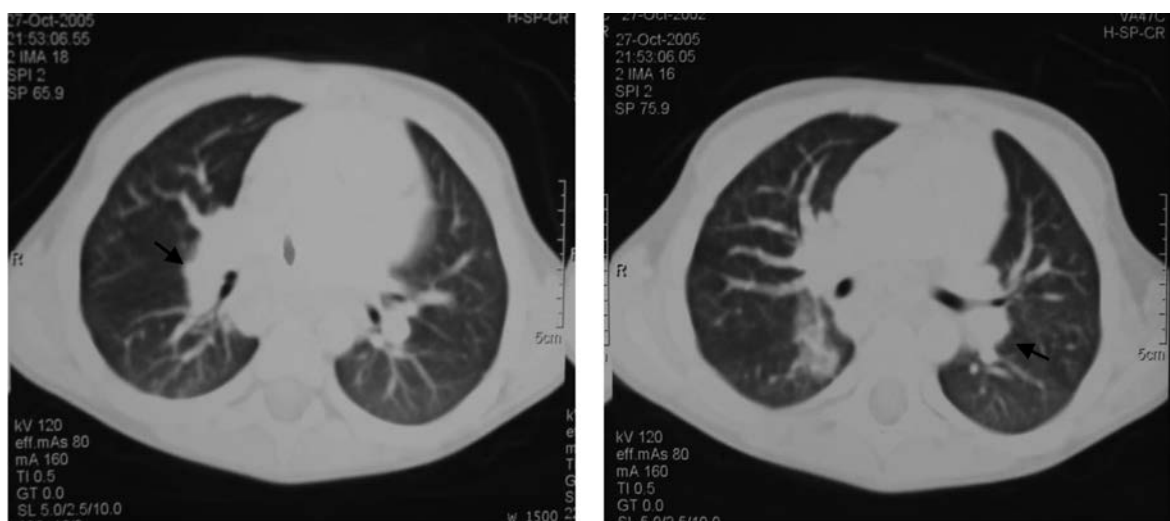


Fig. 1. CT of the thorax with paratracheal conglomerated lymph nodes.

His medical history revealed an increase in body temperature up to 38.5°C once or twice a week, usually during the night and lasting for a few hours, for the last 6 months. He had previously visited several outpatient clinics and had generally been diagnosed as having an acute upper respiratory tract infection. He had recently been treated with ampicillin-sulbactam.

The patient was well-grown, with appropriate physical and neuromotor development for his age. On examination, his body temperature was 39.5°C, blood pressure 110/65 mmHg and heart rate 130 beats per minute. His skin was a bit pale. Breath sounds were coarse on the basal lung area. The remainder of the physical examination was unremarkable. Routine laboratory tests showed marked evidence of inflammation:

erythrocyte sedimentation rate 75 mm/h and sCRP 93.9mg/L (N: 0 to 5 mg/L). Peripheral blood showed a leukocyte count of 18400/ μ l and normocytic anemia, with hemoglobin of 9.6 g/dl. Blood chemistry was normal. Blood and urine cultures were negative. Serologic tests for Epstein-Barr virus, *Cytomegalovirus*, parvovirus, HIV, *Brucella* and *Salmonella typhi* were negative; markers for autoimmune diseases revealed no abnormalities. Immunoglobulin levels and lymphocyte subgroups were also within normal levels (Table 1). The patient was 2 months old when he had his BCG vaccination (the BCG scar was observed), and his tuberculin skin test resulted in an induration of 12 mm. Mediastinal lymphadenomegaly was detected on chest X-ray, with no distinct parenchymal

Table I. Laboratory assessment of patient with FUO

Complete blood count	Leucocytosis and normocytic anemia
Acute phase reactants	Elevated ESR and CRP
Blood chemistry	Normal
Peripheral blood smear	No sign of malignancy or malaria
Blood, urine cultures	Sterile
Throat and stool culture	Normal flora bacteria were cultured
Chest X-ray	Mediastinal lymphadenomegaly
Serology for EBV, CMV, Parvovirus, HIV, <i>Brucella</i> , <i>S. typhi</i>	(-)
RF, ANA, dsDNA, pANCA, cANCA	(-)
Immunoglobulin levels & lymphocyte subgroups	Normal
Bone marrow aspiration	No sign of malignancy or specific infections

ANA: antinuclear antibody, cANCA: cytoplasmic anti-neutrophil cytoplasmic antibodies, CMV: cytomegalovirus, CRP: C-reactive protein, EBV: epstein barr virus, ESR: erythrocyte sedimentation rate, dsDNA: double stranded DNA, HIV: human immunodeficiency virus, pANCA: perinuclear anti-neutrophil cytoplasmic antibodies, RF: rheumatoid factor

pathology. Computed tomography (CT) of the thorax showed enlarged paratracheal lymph nodes, with the largest one 25 mm in diameter. A ground-glass appearance on the base of the right lung was interpreted as a sequelae lesion from past infections (Fig. 1). Abdominal magnetic resonance imaging (MRI) was performed upon detection of a suspicious lesion visualized in the upper hepatic area on CT of the thorax. Multiple contrast-enhanced, hypoechoic nodules with central necrosis were observed in the liver on abdominal MRI (Fig. 2). Chronic inflammation was seen in liver specimens taken with fine-needle aspiration biopsy, although cultures were negative for bacterial infection and fungus. The patient was put on teicoplanin and piperacillin-tazobactam therapy because of presumed bacterial hepatic abscesses. There was no clinical improvement after 3 weeks of therapy; the fever still continued, and the patient's acute phase reactant levels grew worse. Open liver biopsy revealed chronic granulomatous inflammation with some granulomas exhibiting central caseation, which was compatible with pathological findings of tuberculosis infection (Fig. 3). Gram stains of the tissue specimen and Ziehl-Neelsen staining for acid-fast bacteria were negative. Isoniazid, rifampin, pirazinamide and streptomycin therapy was initiated immediately after the diagnosis of pulmonary and abdominal tuberculosis infection had been established on the basis of the biopsy specimen. Culture in Löwenstein-Jensen medium revealed *Mycobacterium tuberculosis*.

The patient had no history of close contact with a person having active tuberculosis. A nitroblue-tetrazolium test performed for chronic granulomatous disease yielded a normal result. Screening of family members for tuberculosis was negative. The patient improved both clinically and radiologically within a few months of the initiation of therapy, which lasted for 12 months. He was periodically examined with ultrasonography. A repeat MRI of the abdomen obtained at the end of therapy showed complete resolution of the liver lesions. To date, over the course of a follow-up period of more than 2 years, the patient has shown no signs of relapse and remains in good condition.

Discussion

The three most common etiological categories of FUO in children are, in order of frequency, infectious diseases, connective tissue diseases and neoplasms^{2,5}. In many cases, a definitive diagnosis is never established and the fever resolves. According to a recently published meta-analysis summarizing the literature describing 1638 children with FUO, infection was by far the most commonly identified etiology¹⁰. In total, 832 patients (51%) had a final diagnosis of infection; within this category, bacterial infections followed by infectious syndromes were the most common etiologies. There were 491 bacterial infections (59% of all infections), with common diagnoses in developing countries being brucellosis, tuberculosis, and typhoid fever, and, in developed countries,

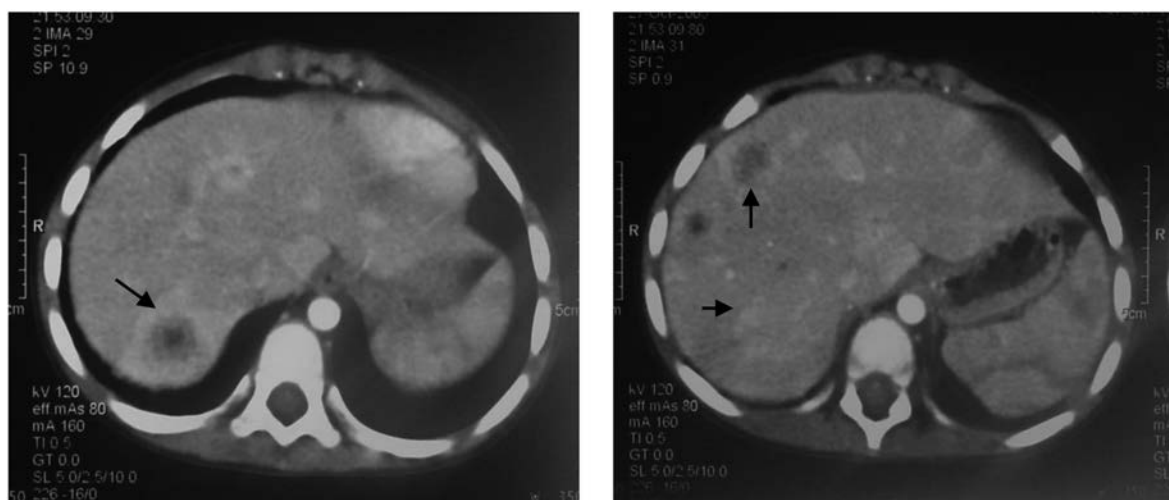


Fig. 2. MRI of the abdomen with hypoechoic, necrotic nodules in the liver.

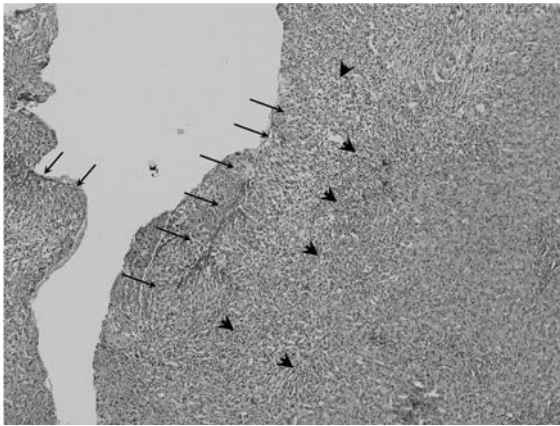


Fig.3. Liver biopsy showing epithelioid histiocytes organizing into a granuloma (arrows), surrounded by mononuclear inflammatory cells (arrowheads) in the liver parenchyma (on the right) (H&E stain, original magnification 100x).

osteomyelitis, tuberculosis, and Bartonellosis, with urinary tract infections common in both. When comparing data between developed and developing nations, infection was consistently the most common cause of FUO, but the types of infections varied. In the other categories, diagnosis at the time of publication was malignancy for 93 children (6%), collagen vascular disease for 150 (9%) and miscellaneous noninfectious conditions for 179 (11%), with no diagnosis for 384 (23%).

Tuberculosis (TB) is an important cause of FUO, especially in countries where the infection occurs endemically. Extrapulmonary TB is more likely to cause FUO than is pulmonary TB, which is usually evident on chest radiography. Active disseminated TB can occur in children with negative chest radiography and tuberculin skin tests^{11,12}. A high index of suspicion for the disease must be maintained, and a careful history of possible contacts obtained. The diagnosis is established by culturing the organism from sputum, gastric aspirates, liver tissue or bone marrow, or by identifying specific histopathologic findings in a biopsy sample.

Hepatic tuberculosis was first described in 1858 in a series of 167 patients with intestinal tuberculous ulceration¹³. Isolated tuberculous liver abscess without active pulmonary or miliary tuberculosis, or other clinical evidence of tuberculosis, is distinctly rare in children, and only a few cases have been reported in the literature^{14,15}. Primary involvement

of the liver in tuberculosis is rare due to the low tissue oxygen level, which makes the liver inhospitable for the bacilli. Cases reported in the literature are often associated with severe extrahepatic involvement, either pulmonary or miliary tuberculosis; however, liver abscess due to *Mycobacterium tuberculosis* associated with pulmonary tuberculosis is also an uncommon diagnosis, particularly in individuals without an underlying inherited or acquired immune deficiency disorder such as chronic granulomatous disease or AIDS, as was the case in our patient, who had no inherited or acquired immunological abnormalities.

Researchers have described three morphological types of hepatic tuberculosis: diffuse involvement associated with miliary or pulmonary tuberculosis; diffuse parenchymal involvement without any evidence of existing tuberculosis anywhere (primary miliary tuberculosis of the liver); and a focal or nodular lesion in the liver, which may be multiple or solitary and present as tuberculoma or abscess, usually secondary to primary pulmonary or gastrointestinal involvement¹⁶. The case we report here shows multiple focal nodules in the liver, presenting as either tuberculoma or abscess secondary to primary pulmonary tuberculosis. The pulmonary involvement of the patient is apparently limited to enlargement of the mediastinal lymph nodes, without any marked evidence of parenchymal lesions.

Signs and symptoms of hepatic involvement may include diffuse abdominal pain or pain localizing to the right upper quadrant, swelling in the right hypochondrium, nausea, vomiting and diarrhea¹⁷. Liver function test abnormalities and cholestatic jaundice may be seen, especially in miliary tuberculosis. Rarely, fulminant hepatic failure can occur¹⁸; however, a majority of granulomas are located near the portal tract, and there is only mild perturbation of hepatic function, so most patients are minimally symptomatic or asymptomatic, as was the case with our patient, who did not demonstrate any such signs or symptoms¹⁹.

There are similar pediatric cases presented in the literature, most of them describing liver abscess due to *M. tuberculosis* associated with pulmonary tuberculosis as a rare diagnosis, particularly in patients without AIDS^{20,21}. Granulomatous hepatitis and tubercular

liver abscesses are treated like any other extrapulmonary tubercular lesions, without any extra risk of hepatotoxicity by antituberculous drugs. Systemic antituberculous therapy alone may be sufficient for the improvement of lesions in the liver without necessitating surgery or percutaneous drainage, as in our case²². The role of corticosteroid therapy in addition to antituberculous agents in the treatment of hepatic tuberculosis is unclear²³. With early diagnosis and prompt effective treatment, the prognosis of hepatic tuberculosis is usually good. However, if there are indications for their use, surgical procedures along with antitubercular drug therapy may be employed¹⁹. Treatment with percutaneous aspiration followed by systemic antituberculous drugs can work successfully in selected cases²⁴.

REFERENCES

1. Cogulu O, Koturoglu G, Kurugol Z, Ozkinay F, Vardar F, Ozkinay C. Evaluation of 80 children with prolonged fever. *Pediatr Int* 2003; 45: 564-569.
2. Pasic S, Minic A, Djuric F, et al. Fever of unknown origin in 185 paediatric patients: a single-centre experience. *Acta Paediatr* 2006; 95: 463-466.
3. Bourrillon A. [Management of prolonged fever in infants]. [Article in French] *Arch Pediatr* 1999; 6: 330-335.
4. Akpede GO, Akenzua GI. Management of children with prolonged fever of unknown origin and difficulties in the management of fever of unknown origin in children in developing countries. *Paediatr Drugs* 2001; 3: 247-262.
5. Schneider T, Loddenkemper C, Rudwaleit M, Lode H, Zeitz M. [Fever of unknown origin in the 21st century: infectious diseases]. [Article in German] *Dtsch Med Wochenschr* 2005; 130: 2708-2712.
6. Kansal AP, Chopra V, Singh H, Singh U. Tubercular hepatic abscess—a rare presentation. *Indian J Tuberc* 2008; 55: 217-220.
7. Kanagaraj A, Marthandam LR, Sriramakrishnan V, Rajesh A, Meenakumari P. Tuberculous liver abscess. *J Assoc Physicians India* 2008; 56: 647-648.
8. Balsarkar D, Joshi MA: Isolated tuberculous hepatic abscess in a non-immunocompromised patient. *J Postgrad Med* 2000; 46: 108-109.
9. Nampoory MR, Halim MM, Sreedharan R, et al. Liver abscess and disseminated intravascular coagulation in tuberculosis. *Postgrad Med J* 1995; 71: 490-492.
10. Chow A, Robinson JL. Fever of unknown origin in children: a systematic review. *World J Pediatr* 2011; 7: 5-10.
11. Tuberculin negative tuberculosis. *Am Rev Respir Dis* 1973; 107: 882-884.
12. Steiner P, Portugaleza C. Tuberculous meningitis in children. A review of 25 cases observed between the years 1965 and 1970 at the Kings County Medical Center of Brooklyn with special reference to the problem of infection with primary drug-resistant strains of *M. tuberculosis*. *Am Rev Respir Dis* 1973; 107: 22-29.
13. Kok KY, Yapp SK. Isolated hepatic tuberculosis: report of five cases and review of the literature. *J Hepatobiliary Pancreat Surg* 1999; 6: 195-198.
14. Debnath PR, Tripathi R, Kandpall D, Kumar B, Malik E, Sharma SB. Isolated tubercular liver abscess in children treated with percutaneous isoniazid infusion. *Indian J Tuberc* 2007; 54: 149-151.
15. Bhatt GC, Nandan D, Singh S. Isolated tuberculous liver abscess in immunocompetent children—report of two cases. *Pathog Glob Health* 2013; 107: 35-37.
16. Wilde CC, Kueh YK. Case report: tuberculous hepatic and splenic abscess. *Clin Radiol* 1991; 43: 215-216.
17. Ramesh J, Banait GS, Ormerod LP. Abdominal tuberculosis in a district general hospital: a retrospective review of 86 cases. *QJM* 2008; 101: 189-195.
18. Hussain W, Mutimer D, Harrison R, Hubscher S, Neuberger J. Fulminant hepatic failure caused by tuberculosis. *Gut* 1995; 36: 792-794.
19. Wu Z, Wang WL, Zhu Y, et al. Diagnosis and treatment of hepatic tuberculosis: report of five cases and review of literature. *Int J Clin Exp Med* 2013; 6: 845-850.
20. Consunji-Araneta R, Higgins R, Qing G, Bouhasan L. Tuberculous damaged lung in a child. *Pediatr Pulmonol* 2011; 46: 1247-1250.
21. Bernabeu Mora R, Paredes Reyes P, Latour Pérez J, Méndez Martínez P, Lorenzo Cruz M, Sánchez Gascón F. [Tuberculous liver abscess in an immigrant patient with pulmonary tuberculosis]. [Article in Spanish] *Arch Bronconeumol* 2002; 38: 246-248.
22. Nandan D, Bhatt GC, Dewan V, Yadav TP, Singh S. Isolated tuberculous liver abscess in a 3-year-old immunocompetent child. *Paediatr Int Child Health* 2013; 33: 187-189.
23. Luther VP, Bookstaver PB, Ohl CA. Corticosteroids in the treatment of hepatic tuberculosis: case report and review of the literature. *Scand J Infect Dis* 2010; 42: 315-317.