



Medical Therapy in Acute Myocardial Infarction: A Case Report

Abdulmecit Afşin, Jülide Yağmur, Mehmet Cansel

İnönü University, Faculty of Medicine, Department of Cardiology, Malatya, Turkey

Abstract

Acute ST elevation myocardial infarction is among the most important causes of cardiac mortality and morbidity. An 80-year-old female patient was referred to our emergency department with chest pain. The patient, who had been diagnosed with ST elevation inferior and right myocardial infarction, received coronary angiography under primary conditions. There was an intense and long thrombus in the right coronary artery. Therefore, the patient was not considered for percutaneous coronary intervention. Glycoprotein IIb/IIIa receptor blockers and tirofiban were added to antiaggregant and anticoagulant therapy. 2 days later, control coronary angiography did not show any signs of residual thrombus and lesions. Coronary reperfusion was achieved successfully with pharmacological treatment without the requirement of mechanical reperfusion. The patient was discharged without complications with further instructions to regulate the medical treatment. In this paper, we aim to present a case which we successfully treated through pharmacological treatment without the need for an invasive intervention.

Key Words: Acute Myocardial Infarction; Thrombus; Tirofiban.

Akut Miyokard Enfarktüsünde Medikal Tedavi: Olgu Sunumu

Özet

Akut ST elevasyonlu miyokard enfarktüsü kardiyak nedenli mortalitenin ve morbiditenin en önemli nedenleri arasında yer almaktadır. 80 yaşında kadın hasta göğüs ağrısı ile acil servisimize sevk edilmişti. Akut ST elevasyonlu inferior ve sağ miyokard enfarktüsü tanısıyla hasta primer şartlarda koroner anjiyografiye alındı. Sağ koroner arterde yoğun ve uzun trombus vardı. Bu nedenle hastaya perkütan koroner girişim düşünülmeydi. Rutin antiagregan ve antikoagülan tedaviye bir glikoprotein IIb/IIIa reseptör blokleri olan tirofiban eklendi. 2 gün sonra yapılan kontrol koroner anjiyografide rezidü trombus ve lezyon izlenmedi. Mekanik reperfüzyona gereksinim olmadan, başarılı bir şekilde farmakolojik tedavi ile koroner reperfüzyon sağlandı. Hasta komplikasyonsuz bir şekilde medikal tedavisi düzenlenerek taburcu edildi. İnaziv girişim yapmadan farmakolojik tedavi ile başarılı şekilde tedavi edilen bir olguyu sunmayı amaçladık.

Anahtar Kelimeler: Akut Miyokard Enfarktüsü; Trombus; Tirofiban.

INTRODUCTION

Acute coronary syndrome (ACS) is one of the leading causes of cardiac mortality and morbidity (1). ST-elevated ACS results from thromboses that entirely obstruct the coronary artery lumen (2). Mechanical reperfusion is the preferred method of treatment for such patients. However, especially in patients with high thrombus load, stent treatment and distal embolization therapy are associated with impaired microvascular circulation and an increased rate of complications during the process (3). Nonetheless, pharmacological reperfusion reduces costs and the number of potential unnecessary coronary interventions while it prevents future coronary intervention related complications such as restenosis and stent thrombosis.

Glycoprotein (GP) IIb/IIIa receptor blockers are antiplatelet agents used in interventional cardiology for ACS and thrombus resolution (4). GP IIb/IIIa receptor blockers have been proved to be successful in terminating thromboses in patients who previously had multiple coronary artery thrombosis (5). In this article, we aim to present a case in which we were able to dissolve an intensive intra-coronary thrombus with antiplatelet

therapy including GP IIb/IIIa receptor blockers without the need for an invasive intervention.

CASE REPORT

An 80-year-old woman, who was referred to our clinic due to chest pain, was admitted with a diagnosis of acute inferior and right myocardial infarction. The chest pain had started 14 hours ago. Apart from hypertension, the medical history of the patient was unremarkable. On physical examination, blood pressure was 100/60 mmHg and pulse was 110 beats/min. Cardiac examination and other system examinations were normal. The patient's electrocardiogram (ECG) results were normal though we detected ST elevation in sinus rhythm, D2, D3, aVF, and V4-5-6 leads. The derivations on the right chest also showed an ST elevation of 0.1 mV. The chest pain continued meanwhile and we performed coronary angiography under primary conditions. The coronary angiography showed dominant right coronary artery and there was massive thrombus and TIMI-2 current (Thrombolysis in Myocardial Infarction) starting from the right ventricular branch reaching out to the distal portion (Figure 1); we also detected insignificant stenoses in other coronary arteries. We did not consider an intervention due to intensive intra-coronary thrombus

and decided to apply tirofiban infusion. The patient was taken to the coronary care unit. We added acetylsalicylic acid, clopidogrel, heparin, and tirofiban infusion (0,15 µg/kg/min) to the medical treatment. Echocardiography showed left ventricular ejection fraction to be 55%. We applied another coronary angiography after 48 hours. This time, we did not observe residual thrombus or lesions in the right coronary artery (Figure 2). After arranging future medical treatment, we discharged the patient on the 6th day of her hospitalisation.

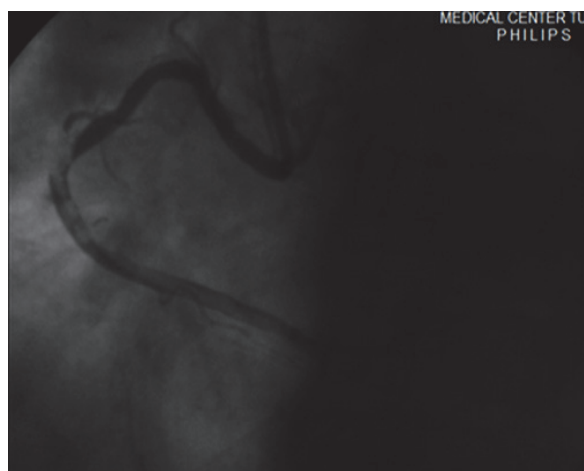


Figure 1. The coronary angiography image of the left oblique pause showing the thrombus-filled right coronary artery.

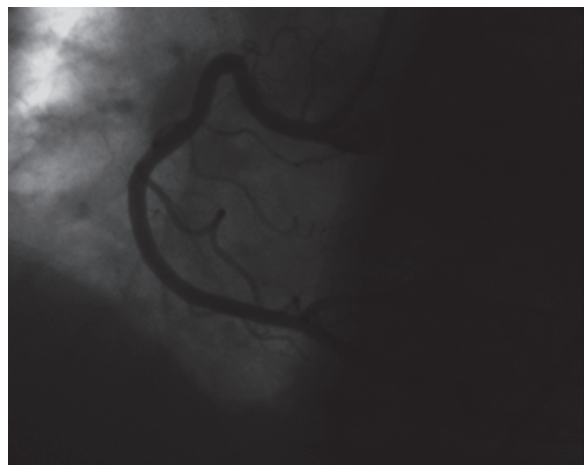


Figure 2. The coronary angiography image of the left oblique pause showing no signs of thromboses or lesions following the tirofiban infusion.

DISCUSSION

Because thrombosis plays the major role in the pathogenesis of ST-elevated myocardial infarction, it has the highest mortality rate among all ACSs (1). Today, researchers work on pharmacological and mechanical treatments that may eliminate intracoronary thromboses. These studies show that 2/3 of the occlusions that lead

to acute myocardial infarction occur in plaque regions that cause stenoses up to 50% (6).

Inducing a conformational change, platelet activation leads to platelet aggregation by allowing circulating fibrinogens to bind with GP IIb/IIIa receptors (4). The discovery of these receptors has led to the use of GP IIb/IIIa receptor blockers in ACS.

There was a massive thrombus and TIMI-2 stream in the right coronary artery of our patient. The intervention for intensive coronary thrombosis lesion increases the risk of no-reflow development (7). Most recent guidelines suggest that practitioners should consider thrombus aspiration in patients with ST-elevated myocardial infarction who have higher clot burden and shorter ischemic time (8). Because our patient had long ischemic time, we deprecated thrombus aspiration. There are some studies that recommend a control coronary angiography following the use of GP IIb/IIIa receptor inhibitors before a percutaneous coronary intervention is carried out for patients with intensive intra-coronary thromboses (9).

Although primary percutaneous intervention to the lumen of the epicardial coronary arteries with balloon or stent seems successful in angiography in the recanalization of heavily clogged epicardial coronary arteries, myocardial reperfusion and microcirculation may not improve at expected levels due to embolisation of the disintegrated thrombus and plaque content to the distal vascular bed with antegrade flow (10). Among successful myocardial tissue perfusion criteria, we can count ST-segment resolution and myocardial blush grade (MBG) in ECG. After the start of treatment, we observed an ST-segment resolution of up to 70% in the ECG of our patient. Besides, the control coronary angiography showed MBG-3 (regular enhancement).

Despite the fact that mechanical revascularization is regarded as the most viable and effective treatment method in myocardial infarction, ACS patients with high intra-coronary thrombus burden may be treated with GP IIb/IIIa receptor inhibitors without the need for angioplasty or coronary stent implementation. In our case, without the need for mechanical reperfusion, we were able to treat our patient with pharmacological reperfusion.

REFERENCES

1. Fuster V, Badimon L, Badimon JJ, Chesebro JH. The pathogenesis of coronary artery disease and the acute coronary syndromes. *N Engl J Med.* 1992;326:242-50.
2. Malek AM, Alper SL, Izumo S. Hemodynamic shear stress and its role in atherosclerosis. *Jama* 1999;282:2035-42.
3. De Luca G, Dudek D, Sardella G, Marino P, Chevalier B, Zijlstra F. Adjunctive manual thrombectomy improves myocardial perfusion and mortality in patients undergoing primary percutaneous coronary intervention for ST-elevation myocardial infarction: a meta-analysis of randomized trials. *Eur Heart J.* 2008;29:3002-10.
4. Boersma E, Harrington EA, Moliterno DJ, White H, Simoons ML. Platelet glycoprotein IIb/IIIa inhibitors in acute coronary

- syndromes: a metaanalysis of all major randomised clinical trials. *Lancet* 2002;359(9302):189-98.
5. Yagmur J, Cansel M, Acikgoz N, Yagmur M, Eyupkoca F, Ermis N, et al. Multivessel coronary thrombosis in a patient with idiopathic thrombocytopenic purpura. *Tex Heart Inst J.* 2012;39(6):881-3.
 6. Falk E, Shah PK, Fuster V. Coronary plaque disruption. *Circulation* 1995;92(3):657-71.
 7. Kotani J, Nanto S, Mintz GS, Kitakaze M, Ohara T, Morozumi T, et al. Plaque gruel of atheromatous coronary lesion may contribute to the no-reflow phenomenon in patients with acute coronary syndrome. *Circulation* 2002;106:1672-7.
 8. Steg PG, James SK, Atar D, Badano LP, Blömstrom-Lundquist C, Borger MA, et al. ESC Guidelines for the management of acute myocardial infarction in patients presenting with ST-segment elevation. *Euro Heart J.* 2012;33:2569-619.
 9. Echavarría-Pinto M, Loges R, Gorqadze T, Gonzalo N, Hemendez R, Jimenez Quevedo P, et al. Safety and Efficacy of Intense Antithrombotic Treatment and Percutaneous Coronary Intervention Deferral in Patients With Large Intracoronary Thrombus. *Am J Cardiol* 2013;111(12):1745-50.
 10. Gibson CM, Cannon CP, Murphy SA, Ryan KA, Mesley R, Marble SJ, et al. Relationship of TIMI myocardial perfusion grade to mortality after administration of thrombolytic drugs. *Circulation* 2000;101(2):125-30.

Received/Başvuru: 16.11.2014, Accepted/Kabul: 19.12.2014

Correspondence/İletişim

Abdulmecit AFŞİN
İnönü Üniversitesi Tıp Fakültesi, Kardiyoloji Anabilim Dalı,
MALATYA, TÜRKİYE
E-mail: abdulmecitafsin@mynet.com

For citing/Atf için

Afsin A, Yagmur J, Cansel M. Medical therapy in acute myocardial infarction: a case report. *J Turgut Ozal Med Cent* 2015;22:207-9 DOI:10.7247/jtomc.2014.2523