

A Right Atrial Myxoma Mimicking Pulmonary Embolism: A Case Report

Ömer Kaya¹, Hilal Ermiş¹, Sinan Türkkkan¹, Zeynep Ayfer Aytemur¹,
Tamer Baysal², Nusret Açıkgöz³

¹Department of Chest Diseases, İnönü University Faculty of Medicine, Malatya

²Department of Radiology, İnönü University Faculty of Medicine, Malatya

³Department of Cardiology, İnönü University Faculty of Medicine, Malatya

Abstract

Myxoma is the most common primary tumour of the heart. Approximately 75% of primary cardiac myxomas are located in the left atrium and tend to be sporadic. Myxomas are rarely asymptomatic and presenting symptoms may sometimes be confused with respiratory diseases.

A 29-year-old male patient was admitted to our outpatient clinic with shortness of breath and chest pain. In the thoracic computed tomography, which was performed for the pre-diagnosis of pulmonary embolism, a hypodense space-occupying lesion, approximately 8X4 cm in size, with irregular margins that did not show contrast enhancement in the right atrium and right ventricle, was identified. The patient, whose diagnosis of myxoma was confirmed by echocardiographic examination, underwent excision of the intracardiac mass.

The present case was deemed to be suitable for presentation since the myxoma was located in the right atrium and right ventricle, as well as to remind that an underlying cardiac pathology should be considered in patients presenting with respiratory symptoms.

Keywords: Right atrial myxoma, cardiac tumour, pulmonary embolism

INTRODUCTION

Myxomas are the most common type of primary cardiac tumours, with a prevalence of 30-50% among all cardiac tumours (1). Of the cardiac myxomas, approximately 80-90% are located in the left atrium at the fossa ovalis (2). Approximately 18% of the cases are located in the right side of the heart. This atypical localization leads to a delay in diagnosis and the majority of patients are diagnosed while investigating pulmonary embolism (3). Embolism is encountered by 10% among right-sided cardiac tumours and these patients may develop massive pulmonary embolism (4). Therefore, care must be taken in embolic pathologies considering the probability of intracardiac tumours. Myxomas are more prevalent among females. Although they can be seen in all age groups, they are most often encountered between the third and sixth decades. Symptoms and clinical findings vary according to the location of the tumour. Left atrial myxomas may be confused with mitral stenosis and left atrial thrombus, whereas right atrial myxomas may be confused with tricuspid valve diseases (4,5).

CASE PRESENTATION

A 29-year-old male patient was admitted with squeezing sensation in his chest, chest pain and shortness of breath which began 3 months ago with effort and enhanced gradually. His anamnesis revealed that he had consulted a physician with the same complaints once before and received nonspecific treatment; however, as his complaints persisted, he was admitted to our clinic. On admission, he stated that he had experienced haemoptysis, approximately a tea spoonful, mixed with sputum for once 3 days ago. His medical history was unremarkable except for 5 pack.year history of smoking. On his physical examination, BP was 120/75 mmHg, pulse rate was 72/min, body temperature was 36.6°C,



Received date: 15.08.2011

Accepted date: 18.02.2012

Address for correspondence
Hilal Ermiş, Department of Chest Diseases,
İnönü University, Malatya, Turkey
E-mail: hilalermis@yahoo.com

© Copyright 2014 Turkish Respiratory Society (TRS)
DOI: 10.5152/ejp.2014.89410

• Available online at www.eurasianj pulmonol.com

respiratory rate was 22/min, and peripheral oxygen saturation (SpO_2) was 97%. Breath sounds were normal on auscultation and cardiac examination revealed normal findings.

At the time of admission to the outpatient clinic, his chest x-ray revealed an increased cardiothoracic ratio, costophrenic angle blunting, and a homogenous density obscuring the borders of the heart and cardiophrenic sinus in the lower zone of the left lung (Figure 1). The patient was hospitalized with a pre-diagnosis of pulmonary embolism and pneumonia based on radiological and clinical findings. Laboratory findings were as follows: D-dimer: 1.15 $\mu\text{g}/\text{mL}$, erythrocyte sedimentation rate: 55 mm/hour, leukocyte count: 12.100/ mm^3 , and C-reactive protein (CRP): 60.7 mg/L. On his arterial blood gas analysis, pH was 7.37, PaCO_2 was 33.4 mmHg, PaO_2 was 67.2 mmHg,

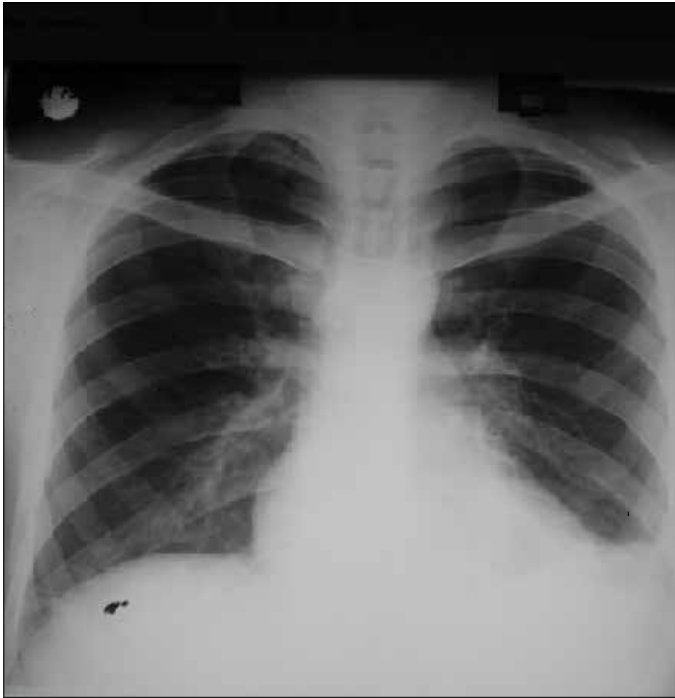


Figure 1. Postero-anterior chest x-ray

HCO_3 was 19.2 mEq/L, and SaO_2 was 93.2%. His electrocardiogram was normal.

Primarily chronic thromboembolic disease was considered based on the complaints of dyspnoea and chest pain lasting for three months, which were not expected at his age, and the presence of hypocapnia and hypoxemia in blood gas analysis, and peripheral infiltrative changes detected on chest x-ray, and on non-contrast-enhanced computed tomography (CT) of the chest performed in another hospital before admitting to our outpatient clinic. There was no evidence in favour of embolism in pulmonary arteries on thoracic CT angiography; on the contrary, a hypodense space-occupying lesion, approximately 8x4 cm in size, with irregular margins, which showed no contrast enhancement, was identified in the right atrium and right ventricle (Figure 2). Primarily cardiac myxoma was considered in the patient, in whom the diagnosis of pulmonary embolism was excluded, and echocardiography (ECHO) was performed. Echocardiographic examination demonstrated a pedunculated, nodular, mobile giant mass, 8x5 cm in diameter, consisting of at least two lobes, which was considered to arise from interatrial septum and prolapsed towards the right ventricle from the tricuspid valve (Figure 3). The lesion was considered to be a myxoma. Since the mass was extremely mobile and had a relatively large size, resection of the intracardiac mass was planned as soon as possible. Pericardium was opened via median sternotomy under general anaesthesia. Right femoral vein and vena cava superior were cannulated. Subsequently, cardiopulmonary bypass was performed via aortic cannulation and then right atriotomy was performed. The mass, which appeared as pedunculated myxoma and completely filled the atrium, was excised. Histopathological diagnosis of the excised mass was consistent with myxoma (Figure 4). All complaints of the patient, who came for control 15 days after surgery, have been improved and control echocardiography was normal.

DISCUSSION

This paper presented a myxoma case, which could not be diagnosed in previous admissions despite its extremely large size, and was not considered among differential diagnosis because of absence of complaints that could be associated with a cardiac pathology. Another

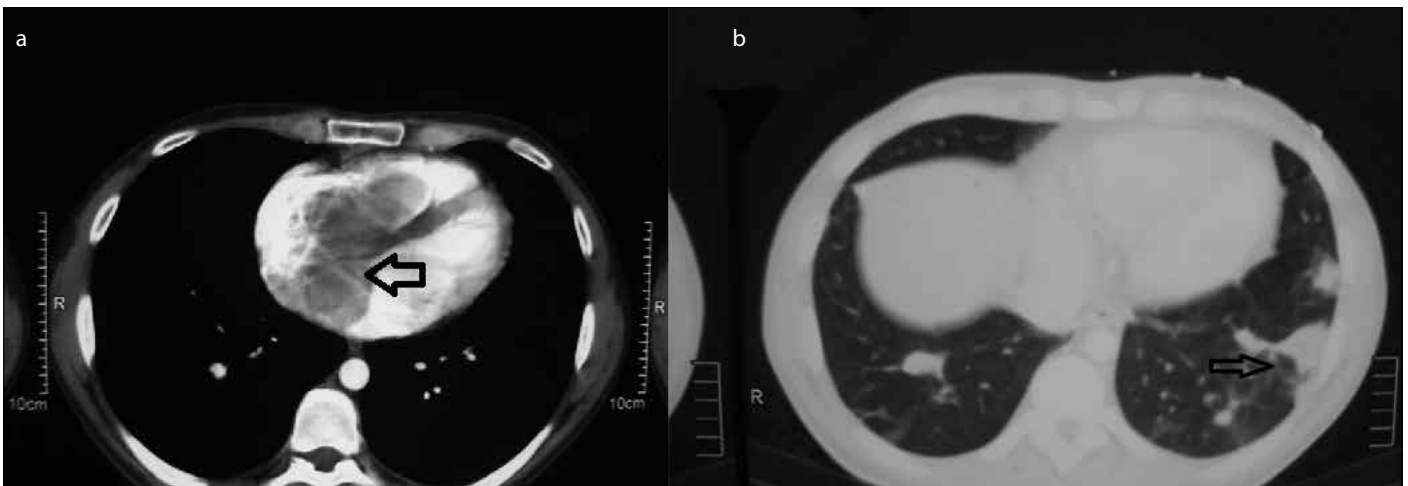
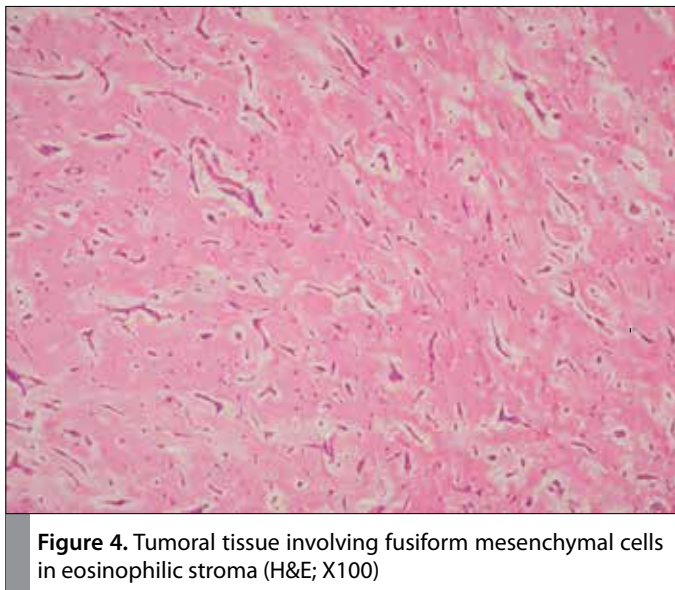
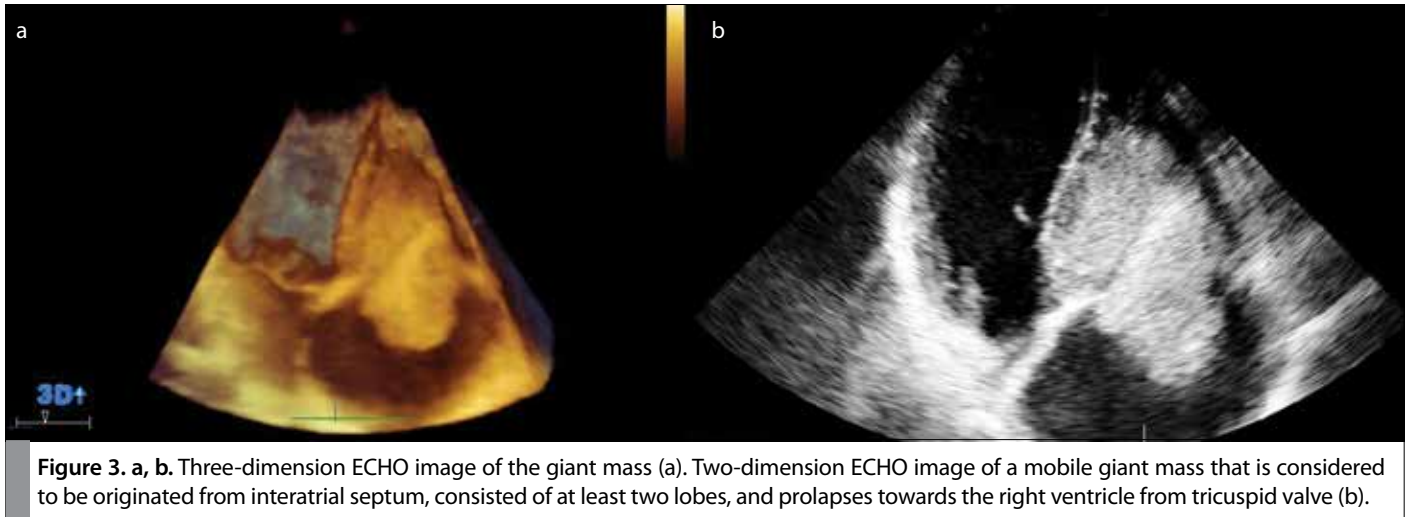


Figure 2. a, b. A hypodense, space-occupying lesion, approximately 8x4 cm in size, with irregular margins that does not show contrast in the right atrium and right ventricle on Thoracic CT (a). Consolidation areas involving pleural-based infiltrations and air bronchograms in the baseline segments of both lower lobes that primarily suggest pulmonary infarction (b).



characteristic of the present case is the fact that it is a myxoma located on the right side of the heart, which is less common than classical forms. This may explain why the patient did not primarily have cardiac symptoms.

Approximately 75% of myxomas are localized in the left atrium, in fossa ovalis, which is in the interatrial septum, and they tend to be sporadic. They usually lead to embolism, intracardiac obstruction and constitutional symptoms (6). Whilst myxomas located on the right side of the heart are rare, right ventricular location is much more uncommon (5%) (7).

The theory that myxomas arise from thrombus is no longer valid and these tumours are thought to be originated from embryonic mesenchymal cells (8). Myxomas can be divided into two subtypes, as sporadic and familial. Although sporadic form is more common, the prevalence of familial form has been reported to be 7% (9).

Clinical symptoms of the patients vary based on the size and location (the heart chamber) of the tumour (10). Nonspecific symptoms such as hemodynamic disorders, cerebral, peripheral and coronary

embolism, fever and fatigue, as well as symptoms mimicking mitral stenosis such as dyspnoea and haemoptysis are encountered in cases of left atrial myxoma (11). Although the myxoma in the present case was located in the right side of the heart, the complaints that led him to consult a physician were shortness of breath, chest pain and haemoptysis. Therefore, the existing complaints of the patient, when evaluated together with the radiological and laboratory findings, were primarily considered to result from pulmonary embolism. Myxoma may cause syncopal attacks and rapidly progressing congestive heart failure. Signs of venous congestion (hepatomegaly, ascites and peripheral oedema, etc.) may be detected particularly in right atrial myxomas and these patients may present with proteinuria (12). Signs of right heart failure were not present in the present case. This can be explained by the fact that the patient was diagnosed before the development of heart failure.

Murmur is the characteristics auscultation finding of myxoma. Diastolic murmur, indistinguishable from mitral stenosis, is heard in the presence of left atrial myxoma (8). A strong systolic murmur is heard in the presence of mobile tumours moving between the left atrium and left ventricle. In the present case, cardiac examination findings were normal with no additional sounds or murmur.

Echocardiography has an important place in the diagnosis and follow-up of myxoma patients after treatment (13). CT and magnetic resonance imaging techniques may also be used for diagnosis. The size, localization and morphology of cardiac myxoma can be investigated by computed tomography. Magnetic resonance imaging helps to evaluate the mobility of the tumour during cardiac cycle (14). Surgical therapy is the standard approach in the treatment of myxoma. Short- and long-term life expectancy is nearly perfect with surgery (15). Recurrence is usually observed in case of inadequate resection and in case the tumour is multicentric, familial and metastatic (5). Post-resection recurrence rate is higher in familial myxoma cases (21%-67%) as compared to sporadic myxomas (1%-4.7%). This rate is higher in "complex myxoma" syndrome, in which other pathological conditions (Adrenocortical nodular dysplasia, Sertoli cell tumours of the testis, pituitary tumours, multiple myxoid breast fibroadenoma, cutaneous myxoma and facial and labial pigmented foci) accompany familial myxoma (4). Metastasis of myxomas is quite rare. Brain (16-18), bone and soft tissue metastasis are more common (19). The time from surgical resection to the occurrence of metastasis

is not clear, but metastasis usually occurs within the first 5 years of resection. Therefore, postoperative periodic follow-up is necessary not only for monitoring recurrence but also for distant metastasis (20,21). Surgical treatment must be performed just after diagnosis because of risks such as acute valve obstruction and massive embolism with high mortality (22). The present case underwent excision of the intracardiac mass in the cardiovascular surgery clinic just after diagnosis. Recurrence was not detected in the first follow-up after surgery.

CONCLUSION

Differential diagnosis of patients that present to the chest diseases outpatient clinic with respiratory symptoms should include primarily cardiac pathologies and organ or system diseases other than respiratory system. In addition, along with the present case, the necessity of careful evaluation of other configurations in the thoracic space while interpreting thoracic computed tomography is once more remembered.

Informed Consent: Written informed consent was obtained from patient who participated in this case.

Peer-review: Externally peer-reviewed.

Author contributions: Concept – H.E., Z.A.A.; Design - Ö.K., H.E.; Supervision - Z.A.A., H.E.; Resource - Ö.K., H.E.; Materials - Ö.K., H.E.; Data Collection&/or Processing - Ö.K., H.E.; Analysis&/or Interpretation - H.E., Z.A.A.; Literature Search - H.E., Ö.K.; Writing - Ö.K., H.E.; Critical Reviews - Z.A.A., T.B., Other - S.T., T.B., N.E.

Conflict of Interest: No conflict of interest was declared by the authors.

Financial Disclosure: The authors declared that this study has received no financial support.

REFERENCES

- Braunwald E. Heart Disease, A textbook of cardiovascular medicine. Philadelphia: W.B. Saunders Company; 1984.
- Bhan A, Mehrotra R, Choudhary SK, Sharma R, Prabhakar D, Airan B, et al. Surgical experience with intracardiac myxomas: long-term follow up. *Ann Thorac Surg* 1998; 66: 810-3. [\[CrossRef\]](#)
- McCoskey EH, Mehta JB, Krishnan K, Roy TM. Right atrial myxoma with extracardiac manifestations. *Chest* 2000; 118: 547-9. [\[CrossRef\]](#)
- Keçeciğil HT, Demir Z, Kolbakır F, Demirağ MK, Akar H. Surgical treatment of cardiac Myxomas. *Turkish Journal of Thoracic and Cardiovascular Surgery* 1999; 7: 210-6.
- Kaplan M, Demirtaş MM, Çimen S, Gerçekoğlu H, Yapıcı F, Özler A. Cardiac Myxomas: surgical experience with 45 Cases. *Turkish Journal of Thoracic and Cardiovascular Surgery* 2002; 10: 11-14.
- Reynen K. Cardiac myxomas. *N Engl J Med* 1995; 333: 1610-7. [\[CrossRef\]](#)
- Meng Q, Lai H, Lima J, Tong W, Qian Y, Lai S. Echocardiographic and pathologic characteristics of primary cardiac tumors: a study of 149 cases. *Int J Cardiol* 2002; 84: 69-75. [\[CrossRef\]](#)
- Thiene G, Valente M, Lombardi M et al. Tumours of the heart In: Camm JA, Lüscher, FT, Serruys PW. *The ESC Textbook of Cardiovascular Medicine 2nd edition* New York: 2009; 735-61.
- Roberts WC. Primary and secondary neoplasms of the heart. *Am J Cardiol* 1997; 80: 671-82. [\[CrossRef\]](#)
- Duran NE, Özkan M. Left atrial myxoma with atypical localization. *Türk Kardiyol Dern Arş - Arch Turk Soc Cardiol* 2008; 36: 256-8.
- Yuehua L, Jing G, Kai F, Hongwei W, Jingjing L. Left atrial myxoma presenting with erythematous macules and loss of memory. *Clin Exp Dermatol* 2003; 28: 383-6. [\[CrossRef\]](#)
- Kalra PA, Raghavan C, Hassan R, Lawson R, Waldek S. Nephrotic-range proteinuria associated with right atrial myxoma. *Clin Nephrol* 1992; 37: 294-6.
- Fykel FE 3rd, Seqard JB, Edwards WD, Miller FA Jr, Reeder GS, Schattenberg TT, et al. Primary cardiac tumors: experience with 30 consecutive patients since the introduction of two-dimensional echocardiography. *J Am Coll Cardiol* 1985; 5: 1465-73. [\[CrossRef\]](#)
- Vincent B, Ho, MAJ Jeffrey D, Hirsch MC. Left atrial myxoma. *Mil Med* 2006; 171: iv-vi.
- Hanson EC, Gill CC, Razavi M, Loop FD. The surgical treatment of atrial myxomas: clinical experience and late results in 33 patients. *J Thorac Cardiovasc Surg* 1985; 89: 298-303.
- Rankin LI, DeSousa AL. Metastatic atrial myxoma presenting as intracranial mass. *Chest* 1978; 74: 451-2. [\[CrossRef\]](#)
- Budzilovich G, Aleksie S, Greco A, Fernandes J, Harris J, Finegold M. Malignant cardiac myxoma with cerebral metastases. *Surg Neurol* 1979; 11: 461-9.
- Chen HJ, Liou CW, Chen L. Metastatic atrial myxoma presenting as intracranial aneurysms with hemorrhage: case report. *Surg Neurol* 1993; 40: 61-4. [\[CrossRef\]](#)
- Read RC, White HJ, Murphy ML, Williams D, Sun CN, Flanagan WH. The malignant potentiality of left atrial myxoma. *J Thorac Cardiovasc Surg* 1974; 68: 857-68.
- Terada Y, Wanibuchi Y, Noguchi M, Mitsui T. Metastatic atrial myxoma to the skin at 15 years after surgical resection. *Ann Thorac Surg* 2000; 69: 283-4. [\[CrossRef\]](#)
- Ng HK, Poon WS. Cardiac myxoma metastasizing to the brain. Case report. *J Neurosurg* 1990; 72: 295-8. [\[CrossRef\]](#)
- Gersak B, Mikek M, Smrkolj V, Gabrijelcic T. Results of treatment of 17 patients with heart tumour. *Eur J Surg Oncol* 1999; 25: 302-5. [\[CrossRef\]](#)