

# Pancreatic pseudocyst development due to organophosphate poisoning

Organofosfat zehirlenmesine bađlı pankreatik psödokist gelişimi

M. M. Murat HARPUTLUOĐLU, Ulvi DEMİREL, Hakan ALAN, Fehmi ATEŞ, Murat ALADAĐ, Melih KARINCAOĐLU, Fatih HİLMİOĐLU

Department of Gastroenterology, İnönü University, Medical School, Malatya

**Background/aims:** Acute pancreatitis is a serious complication of organophosphate poisoning. There is no report in the literature dealing with the development of a pancreatic pseudocyst after complication of organophosphate-induced acute pancreatitis. Therefore, we present a case who developed pancreatic pseudocyst after complication of organophosphate-induced acute pancreatitis. **Methods:** A 17-year-old female patient with a history of ingestion of complication of organophosphate insecticide (DDVP EC 550, dichlorvos) was admitted with cholinergic symptoms. On admission, serum amylase and lipase levels were high and abdominal ultrasonography showed an edematous pancreas. No etiological factor for acute pancreatitis was evident. **Results:** We diagnosed complication of organophosphate-induced acute pancreatitis. After four weeks, abdominal abdominal ultrasonography and computerized tomography revealed a pancreatic pseudocyst of 6 cm diameter. During follow-up, the pancreatic pseudocyst size regressed to 4 cm. **Conclusion:** Complication of organophosphate poisoning can cause acute pancreatitis and its complications. Early diagnosis and appropriate treatment may reduce morbidity and mortality.

**Key words:** Organophosphate poisoning, acute pancreatitis, pancreatic pseudocyst, dichlorvos

**Amaç:** Akut pankreatit, organofosfat zehirlenmesinin ciddi bir komplikasyonudur. Literatürde organofosfat ile oluşan akut pankreatit sonrası pankreatik psödokist gelişimiyle ilgili yayın bulunmamaktadır. Bu nedenle, organofosfat ile oluşan akut pankreatit sonrası pankreatik psödokist gelişen bir vakayı sunuyoruz. **Yöntem:** Organofosfat insektisit (DDVP EC 550, diklorvos) alım öyküsü olan 17 yaşında bir kadın hasta kolinerjik semptomlarla başvurdu. Başvuruda, serum amilaz ve lipaz düzeyleri yüksekti ve abdominal ultrasonografi incelemesinde ödematöz pankreas izlendi. Akut pankreatit için herhangi bir etyolojik faktör yoktu. **Bulgular:** Organofosfat ile oluşan akut pankreatit teşhis ettik. Dört hafta sonra, abdominal ultrasonografi ve bilgisayarlı tomografide 6 cm çapında pankreatik psödokist izlendi. Takip sırasında pankreatik psödokist çapı 4 cm'ye geriledi. **Sonuç:** Sonuçta organofosfat zehirlenmesi, akut pankreatit ve komplikasyonlarına yol açabilir. Erken teşhis ve uygun tedavi morbidite ve mortaliteyi azaltabilir.

**Anahtar kelimeler:** Organofosfat zehirlenmesi, akut pankreatit, pankreatik psödokist, diklorvos

## INTRODUCTION

Organophosphate (OP) insecticides are potent inhibitors of acetylcholinesterase enzyme. This inhibition leads to an increase in acetylcholine activity, which is responsible for symptoms seen in OP poisoning such as abdominal pain, diarrhea, hyper-sialorrhea, tight myosis and vomiting (1, 2). OP poisonings are frequently seen in agricultural regions. Exposure to OP insecticides may be accidental or as a suicide attempt. In adults, the frequency of acute pancreatitis related to OP poisoning is 12.7% (3, 4).

Although it has been reported that pancreatic pseudocysts (PP) develop after pancreatitis due to carbamate insecticides (4, 5), there is no report in the literature dealing with this complication after OP poisoning. Therefore, we present a case who developed a PP after acute pancreatitis related to OP poisoning.

## CASE REPORT

A 17-year-old female patient with a history of OP poisoning by ingestion of two spoonfuls of insecti-

cide (DDVP EC 550, dichlorvos, Bayer® Germany) 4 h earlier in a suicide attempt was admitted to the emergency department of our hospital with blurred vision, abdominal pain, nausea and hypersialorrhea. She had undergone cardiac surgery for a ventricular septal defect. She had no history of alcohol, medication, or hematological or biliary disease. On physical examination, she was conscious, and her vital findings were as follows: Temperature 38.5°C, blood pressure 120/80 mmHg, and heart rate 59/min. She had bilateral pinpoint pupils and hypersalivation. Diffuse tenderness in all quadrants was noted in her abdominal examination. Other physical examination findings were normal. Activated charcoal treatment and 1 mg of atropine sulphate (Drogsan İlaçları, Turkey) were given promptly and the patient was transferred to the intensive care unit (ICU).

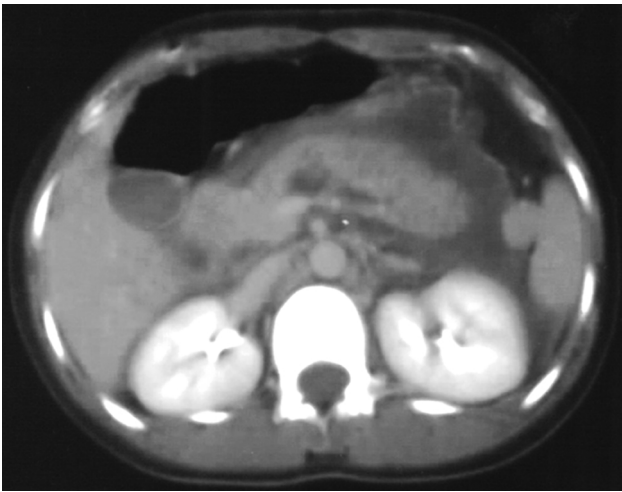
The laboratory tests revealed the following results: Hematocrit 50%, white blood cell count (WBC) 35100/mm<sup>3</sup>, platelet count (PLT) 334000/mm<sup>3</sup>, prothrombin time (PT) 20.4 s, erythrocyte sedimentation rate (ESR) 43 mm/h, blood glucose 192 mg/dl, blood urea nitrogen (BUN) 15 mg/dl, serum creatinine 0.7 mg/dl, calcium (Ca) 8.9 mmol/L, alanine aminotransferase (ALT) 8 IU/L, aspartate aminotransferase (AST) 25 IU/L, alkaline phosphatase 212 IU/L, indirect bilirubin 0.6 mg/dl, direct bilirubin 0.2 mg/dl, lactate

dehydrogenase (LDH) 1310 IU/L, total protein 6.9 g/dl, albumin 3.8 g/dl, amylase 1466 IU/L, lipase 1213 IU/L, and C-reactive protein (CRP) 156 mg/L (Table 1). There were no electrocardiographic abnormalities and her chest X-ray was normal. Abdominal ultrasonography (USG) was performed for high amylase and lipase levels and demonstrated edema in the body and tail regions of the pancreas and ascites in the pelvis. Ascitic fluid analysis was done after paracentesis. The serum ascites albumin gradient was 0.9 and ascites amylase level was 1529 IU/L.

Oral intake was stopped and supportive treatment (proton pump inhibitors, analgesic, fluids and total parenteral nutrition) was started. A total of 8 mg of atropine was given according to cholinergic symptoms and findings on the first day. Atropine sulphate was not required after the first day. In the ICU, the patient's blood gas analysis was evaluated and found to be within normal limits. Intravenous 2 mg/day ceftriaxone was started after her cultures were taken because of high WBC count and fever (38.5°C). On admission, Ranson's criteria score was 2. On the second day, abdominal computerized tomography (CT) was performed for severe abdominal pain. This showed intrapancreatic fluid collection at the tail of the pancreas (Figure 1), blurring of the peripancreatic fat planes, mesenteric inflammation, pleural fluid in the left

**Table 1.** Patient's laboratory values on admission and during the follow-up period

	On admission	2 <sup>nd</sup> day	4 <sup>th</sup> day	15 <sup>th</sup> day	4 <sup>th</sup> week
pH	7.34	7.39	7.48	7.38	-
PaO <sub>2</sub> (mmHg)	85	80	86	91	-
PaCO <sub>2</sub> (mmHg)	30.6	27.4	33.6	29	-
HCO <sub>3</sub> (mmol/L)	16.5	16.7	25.3	23	-
WBC (/mm <sup>3</sup> )	35100	25700	15700	9500	7600
Hematocrit (%)	50	39.8	28.6	32.3	38.1
PLT (/mm <sup>3</sup> )	334000	246000	236000	446000	332000
Blood glucose (mg/dl)	192	91	139	139	97
BUN (mg/dl)	15	11	4	5	10
Creatinine (mg/dl)	0.7	0.73	0.6	0.6	0.6
ALT (IU/L)	25	30	17	14	84
AST (IU/L)	8	11	9	9	250
ALP (IU/L)	212	226	237	268	228
Total bilirubin (mg/dl)	0.8	0.8	0.44	0.3	0.4
LDH (IU/L)	1310	1250	1019	822	423
Amylase (IU/L)	1466	935	214	182	105
Lipase (IU/L)	1213	635	208	172	46
Calcium (mmol/L)	8.9	7.9	8.1	9.3	-
ESR (mm/h)	43	-	-	25	20
CRP (mg/L)	156	94.7	78	15	8

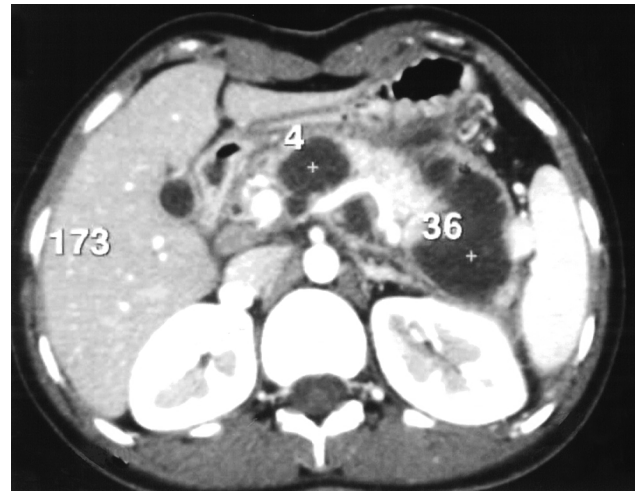


**Figure 1.** Intrapaneatic fluid collection at the tail of the pancreas

hemithorax and ascites. Transdermal fentanyl (Durosegi<sup>®</sup>) 25 µg/h was started. During the first 48 h, Ranson's criteria score remained at 2. No microorganism was grown in her cultures.

On the fourth day, the laboratory values were as follows: WBC 15700/mm<sup>3</sup>, amylase 214 IU/L, lipase 208 IU/L, and CRP 78 mg/L. Because she had persistent severe abdominal pain, analgesic and total parenteral nutrition treatment were continued. After the first week, her abdominal pain decreased gradually. She could tolerate oral nutrition, had no fever, and was in good health. The laboratory findings were as follows: WBC 9500/mm<sup>3</sup>, amylase 182 IU/L, lipase 172 IU/L, CRP 15 mg/L, and ESR 25 mm/h. The last abdominal USG revealed edematous and heterogeneous pancreas, and peripancreatic fluid collection with non-definable borders. She was discharged from hospital with oral ciprofloxacin (500 mg twice a day) and proton pump inhibitors at the end of the second week.

In her outpatient control after four weeks, she had no complaints and was in good health. The laboratory values were: WBC 7600/mm<sup>3</sup>, amylase 105 IU/L, lipase 46 IU/L, CRP 8 mg/L, and ESR 20 mm/h. Abdominal USG showed mild edema in the caput and body regions of the pancreas, and a well-demarcated hypoechoic cyst with a diameter of 6 x 3.6 cm in the partial tail of the pancreas. These USG findings are consistent with a PP. Therefore, dynamic pancreas CT was performed, which confirmed the PP (Figure 2). This pseudocyst was in the tail region of the pancreas and with lobular contour. The fatty tissues neighboring this lesion were dirty in appearance. Clinical



**Figure 2.** Pancreatic pseudocyst in the tail region of the pancreas

observation was planned for this PP. In her outpatient follow-up after eight weeks, she had no complaints and was in good health. The last abdominal USG revealed that the PP size had regressed to 4 cm. We still follow her clinical course as an outpatient.

## DISCUSSION

Carbamate and OP compounds are commonly used worldwide as agricultural insecticides. Exposure to the hazardous effects of these compounds can be accidental or voluntary. Acute pancreatitis is a rare complication of OP poisoning. This complication generally shows a subclinical course. Acute pancreatitis as a complication of OP insecticide poisoning is a result of acetylcholine release from pancreatic nerves and prolonged hyperstimulation of pancreatic acinar cells. This hyperstimulation is thought to be the mechanism of acute pancreatitis after poisoning by OP insecticide (1, 6, 7). Although it has been reported that carbamate poisoning leads to PP (4, 5), there has been no report of PP after pancreatitis due to OP poisoning until now. Our case is the first patient in the literature who developed a PP after pancreatitis due to OP (dichlorvos) poisoning.

A PP develops as a result of pancreatic enzymes, debris, fluid, tissue and blood collection in a period of 1–4 weeks from the beginning of acute pancreatitis. The incidence of pseudocyst development in acute pancreatitis is 15%. Abdominal pain that may or may not radiate to the back region is a common complaint among patients. Serum pancreatic enzymes and suitable imaging techniques

should be used more often in determining the patient's clinical situation (8). Spontaneously unresolved pseudocysts (10% of cases) could lead to serious complications such as pain, pseudocyst rupture and abscess formation due to the expanding size of the lesion and the compression of other visceral organs (9). In our patient, acute pancreatitis was detected with laboratory and abdominal USG findings on admission. Possible etiological factors for acute pancreatitis (alcohol, biliary disease, medication, and others) were excluded. Because she had a history of OP ingestion, we diagnosed OP-induced acute pancreatitis. Four weeks after admission, abdominal USG and CT showed development

of a 6-cm in diameter PP. We did not perform any invasive treatment and followed its progress conservatively. In the 8<sup>th</sup> week, we observed that the diameter of the PP had regressed to 4 cm.

The diagnosis of acute pancreatitis can be obscured by the systemic effects of OP poisoning (6). Abdominal pain, nausea and vomiting are common features of acute pancreatitis and OP poisoning. If these symptoms are considered to be caused only by OP poisoning, diagnosis and treatment of acute pancreatitis may be delayed. This attitude may lead to an increase in morbidity and mortality. In conclusion, acute pancreatitis and its complications should be considered in OP poisoning.

## REFERENCES

1. Kandalaf K, Liu S, Manivel C, et al. Organophosphate increases the sensitivity of human exocrine pancreas to acetylcholine. *Pancreas* 1991; 6: 398-403.
2. Goodale RL, Manivel JC, Borner JW, et al. Organophosphate sensitizes the human pancreas to acinar cell injury: an ultrastructural study. *Pancreas* 1993; 8: 171-5.
3. Sahin I, Onbasi K, Sahin H, et al. The prevalence of pancreatitis in organophosphate poisoning. *Hum Exp Toxicol* 2002; 21: 175-7.
4. Rizos E, Liberopoulos E, Kosta P, et al. Carbofuran-induced acute pancreatitis. *JOP* 2004; 5: 44-7.
5. Brahmi N, Blel Y, Kouraichi N, et al. Acute pancreatitis subsequent to voluntary methomyl and dichlorvos intoxication. *Pancreas* 2005; 31: 424-7.
6. Harputluoglu MMM, Kantarceken B, Karıncaoglu M, et al. Acute pancreatitis: an obscure complication of organophosphate poisoning. *Human Exp Toxicol* 2003; 22: 341-3.
7. Banks PA. Acute and chronic pancreatitis. In: Feldman M, Sleisenger MH, Scharschmidt BF, eds. *Sleisenger and Fordtran's Gastrointestinal and Liver Disease*. 6<sup>th</sup> ed. Philadelphia, PA: W.B. Saunders Company 1998; 809-62.
8. Isselbacher KJ, Braunwald E, Wilson JD, et al. *Harrison's Principles of Internal Medicine Companion Handbook*. 13<sup>th</sup> ed. Singapore: McGraw-Hill, Inc 1995; 514-6.
9. ke Andrén-Sandberg, Christos D. Pancreatic pseudocysts in the 21<sup>st</sup> century. Part II: Natural history. *JOP* 2004; 5: 64-70.