

Necrotizing Enterocolitis due to Congenital Complete Atrioventricular Block*

Uğur Koltuksuz,¹ MD, Feyza A. Paç,² MD, M. Harun Gürsoy,¹ MD, Mustafa Aydinç,¹ MD, Hamza Karabiber,² MD, Selma Çetin,¹ MD, Abdurrahman Karaman,¹

Some of the cardiac diseases are known to predispose to necrotizing enterocolitis (NEC). However, congenital atrioventricular (AV) block, resulting in NEC, has not hitherto been reported. We report a newborn with bradycardia who was proved to have a complete congenital heart block and operated due to NEC on her third day of life. Although there was no pacemaker indication with an atrial rate of 125 and ventricular rate of 55 bpm, a temporary pacing was accomplished. Unfortunately, the patient worsened postoperatively and died of cardiopulmonary arrest. Therefore, as in other diseases, which cause low tissue perfusion, it should be considered that congenital AV block may result in mesenteric ischemia and NEC. We suggest that any patient with AV block presenting with NEC should undergo pacemaker placement even with high ventricular rates. *Ann Med Sci* 2000;9:85-87

Key words: *Necrotizing enterocolitis, congenital complete atrioventricular block.*

Necrotizing enterocolitis (NEC) is a disease most frequently affecting premature babies who have undergone hypoxia, shock or similar stress in the neonatal intensive care units^{1,2}. The etiology of the disease is obscure, but numerous agents and events have been hypothesized as responsible causes. Among these causes, congenital heart disease (CHD) is known as predisposing to NEC³. However congenital atrioventricular (AV) block which predisposing to NEC has not hitherto been reported. In this report, we present a neonate with proven complete AV block in whom NEC developed and discuss the management.

Case Report

A full term baby girl weighing 2620 g was delivered by spontaneous vaginal delivery to a 26-year-old multiparous mother. Ultrasonography revealed fetal bradycardia in the second trimester of the pregnancy, but movements of the baby were normal. When the baby was referred to our

tion showed heart rate below 50-55 bpm with a blood pressure of 82/70 mmHg. However, none of the atrial impulses were conducted to the ventricles in the electrocardiography (Fig 1). Echocardiography revealed a normal cardiac structure. Antibodies to riboproteins which might show maternal connective tissue disorders were negative. Atropine therapy as an adrenergic agonist was started. Pacing therapy was not indicated due to a heart rate of 55 bpm and above after atropine therapy. On the second day of admittance, the baby revealed abdominal distention and on the third day, hyperemia, edema and cellulitis developed on the abdominal wall along with ascites. Serial abdominal radiographs showed intestinal dilatation and a group of static intestinal loops in the upper left quadrant. The microscopic examination of ascitic fluid demonstrated gram negative bacteria. An emergency laparotomy was performed on the third day. Moderate serosanguineous fluid was present in the abdominal cavity. A transmural necrosis in the ascending and transverse colon was seen. After removing the necrotic part of the colon, a double-barrelled colostomy was performed. Pathological examination of the resected bowel segments revealed ischemic necrosis including

Originally received: February 19, 1999.

Revision accepted: July 21, 1999.

*Presented at the 15th Turkish Congress of Pediatric Surgeons, June 25-26, 1996 Istanbul, TÜRKİYE

İnönü University Faculty of Medicine, Department of Pediatric Surgery¹ and Pediatrics², Malatya-TÜRKİYE

both mucosa and muscularis.

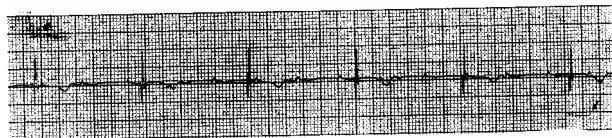


Figure 1. Electrocardiography showing complete AV block.

The patient was in a good condition until 10th postoperative day with an atrial rate of 125 and ventricular 55 bpm. Apparently there was no pacemaker indication. However, on the tenth day, the condition of the patient deteriorated with abdominal distention. Since the examination of the patient and abdominal radiographs revealed no sign of intestinal necrosis, a reexploration of the abdomen was not considered. Despite the heart rate was around 55 bpm constantly, and there was no clear-cut pacemaker indication, a temporary pacing was accomplished by transcutaneous pacemaker via right jugular vein, considering that abdominal distention was due to mesenteric ischemia, and the heart rate was adjusted to 100 bpm. Right after pacing, the baby was better, but unfortunately after nearly six hours of the procedure heart failure developed. On the eleventh day, her abdominal distention increased and the response to the pacing disappeared. Finally, the baby died of cardiopulmonary arrest on the 12th day. Necropsy revealed a normal cardiac morphology without any discernible pathology. Although small bowel loops were distended, there was no sign of necrosis.

Discussion

Neonatal NEC is the most common gastrointestinal emergency in the neonatal intensive care units. Incidence is higher among premature and low birth weight infants. However, 20% of the patients are full-term newborns and their birth weights are in the normal range⁴. The concept of risk factors such as hypoxia, neonatal asphyxia, apnea, pulmonary disease, exchange transfusions, hyperosmolar feedings, use of plastic umbilical artery and vein catheters has been questioned. On the other hand, a risk factor is usually present in term infants. Particularly, neonates with symptomatic CHD frequently develop the intestinal complication^{3,5,6}. Leung et al³ studied all symptomatic neonates with proven CHD. They found that 7% of the patients with symptomatic CHD developed NEC during their study period. Hebra et al¹ reported their experience in the patients with hypoplastic left heart syndrome, which is basically a form of cyanotic congenital heart disease. Eight percent of these patients developed significant mesenteric ische-

mia. Among the theories of pathogenesis of NEC, mesenteric insufficiency, resulting in mucosal injury, is the most widely accepted one. In the diseases, which cause low tissue perfusion, there is a predisposition to NEC.

AV block is defined as the inability of an atrial impulse to be propagated to the ventricles. The infant with congenital complete heart block may be asymptomatic or may present with varying degrees of decreased cardiac output; if clinically asymptomatic, the block does not require treatment, but should be followed clinically in an intensive care unit when the heart rate is above 55 bpm, since there is a definite risk for sudden death⁷. Since the amount of blood pumped is related to the ventricular volume and ventricular rate, mesenteric circulation may be impaired at ventricular rates less than normal. In the presence of NEC, attempts at improving circulation and especially mesenteric circulation seems to be important. Therefore, the limits considered for normal newborns may not be appropriate for those who have experienced NEC. In the present case, we managed the baby as a newborn who does not have an associated pathology such as NEC at the beginning. However, we think that this management caused the delay of the application of the temporary pacemaker.

As in the other conditions, which cause low tissue perfusion, it should be kept in mind that congenital AV block may result in mesenteric ischemia and NEC. In order to prevent this situation, all infants with congenital AV block should be managed as premature babies are inclined to NEC. We suggest that when NEC develops in a baby with congenital AV block, pacing should be considered immediately even if the heart rate is over 55 bpm.

References

1. Hebra A, Brown MF, Hirschl RB, McGeehin K, O'Neill JA Jr, Norwood WI, Ross AJ 3d. Mesenteric ischemia in hypoplastic left heart syndrome. *J Pediatr Surg*, 1993; 28:606-611.
2. Lawrence G, Bates J, Gaul A. Pathogenesis of neonatal necrotizing enterocolitis. *Lancet*, 1982; 8264:137-139.
3. Leung MP, Chau KT, Hui PW, Tam AY, Chan FL, Lai CL, Yeung CY. Necrotizing enterocolitis in neonates with symptomatic congenital heart disease. *J Pediatr*, 1988; 113:1044-1046.
4. Allen HA, Haney PJ. Left ventricular outflow obstruction and necrotizing enterocolitis. *Radiology*, 1984; 150:401-402.
5. Kliegman RM, Fanaroff AA. Neonatal necrotizing enterocolitis: a nine-year experience. *Am J Dis Child*, 1981; 135:603-607.
6. Moss TJ, Adler R. Necrotizing enterocolitis in older infant, children, and adolescents. *J Pediatr* 1982; 100:764-766.

Koltuksuz et al. Necrotizing Enterocolitis due to Congenital Complete Atrioventricular Block

7. Smith RT Jr. Pacemakers for children. In: Gillette PC, Garson A Jr. Eds. Pediatric Arrhythmias: Electrophysiology and Pacing. Philadelphia, W.B. Saunders Company. Hartcourt Brace Jovanovich Inc; 1990:532-558.